

Original Article

## Combined Effect of Granulocyte-Colony-Stimulating Factor-Induced Bone Marrow-Derived Stem Cells and Red Ginseng in Patients with Decompensated Liver Cirrhosis (Combined Effect of G-CSF and Red Ginseng in Liver Cirrhosis)

Hyun Hee Kim<sup>1</sup>, Seung Mo Kim<sup>2</sup>, Kyung Soon Kim<sup>2</sup>, Min A Kwak<sup>2</sup>, Sang Gyung Kim<sup>3</sup>,  
Byung Seok Kim<sup>1</sup>, Chang Hyeong Lee<sup>1</sup>

<sup>1</sup>Department of Internal Medicine, Catholic University of Daegu School of Medicine

<sup>2</sup>Department of Internal Medicine, College of Korean Medicine, Daegu Haany University

<sup>3</sup>Department of Laboratory Medicine, Catholic University of Daegu School of Medicine

**Objectives:** Granulocyte-colony-stimulating factor (G-CSF) mobilized bone marrow (BM)-derived hematopoietic stem cells could contribute to improvement of liver function. In addition, liver fibrosis can reportedly be prevented by the Rg 1 component of red ginseng. This study investigated the combined effect of G-CSF and red ginseng on decompensated liver cirrhosis.

**Methods:** Four patients with decompensated liver cirrhosis were injected with G-CSF to proliferate BM stem cells for 4 days (5 µg/kg bid subcutaneously) and followed-up for 3 months. The patients also received red ginseng for 4 days (2 tablets tid per os). We analyzed Child-Pugh scores, Model for End-Stage Liver Disease (MELD) scores and cirrhotic complications.

**Results:** All patients showed marked increases in White blood cell (WBC) and CD34+ cells in the peripheral blood, with a peak time of 4 days after G-CSF injection. Spleen size also increased after G-CSF injection, but not severely. At end of the study, 2 patients showed improvement in Child-Pugh scores, hepatic encephalopathy, and refractory ascites. During the clinical trial period, none of the 4 patients showed any other adverse events or deterioration of liver function.

**Conclusions:** We conclude that G-CSF/red ginseng combination therapy is relatively effective in improving liver function and major complications of decompensated liver cirrhosis without adverse effects. Further clinical trials are warranted to assess the clinical effects of G-CSF for decompensated liver cirrhosis.

**Key Words** : granulocyte colony-stimulating factor, hematopoietic stem cell, liver cirrhosis, red ginseng

### Introduction

Liver transplantation is the only curative treatment for cirrhotic patients; however, its use is limited by a lack of donors. In addition, liver transplantation is

associated with the following drawbacks: rejection, viral reactivation after transplantation, use of immunosuppressants, and de novo malignancy<sup>1-2</sup>. Therefore, other therapies that can substitute for liver transplantation are needed. Adult stem cell therapy

---

• Received : 31 August 2016      • Revised : 23 December 2016      • Accepted : 30 December 2016  
• Correspondence to : Chang Hyeong Lee  
Department of Internal medicine, Daegu Catholic University Hospital  
Daemyeong 4-dong, Nam-gu, Daegu, Korea (705-718)  
Tel : +82-53-650-4050, Fax : +82-53-628-4050, E-mail : chlee1@cu.ac.kr

---

has been considered as another solution for the treatment of various degenerative diseases including liver cirrhosis in cases that cannot be treated with liver transplantation due to lack of donors or unsuitability. The two types of bone marrow stem cells are hematopoietic and mesenchymal stem cells. Mesenchymal stem cells are known to be able to differentiate into bone, cardiac muscle, endothelial cells, nerve cells, and hepatocytes<sup>3</sup>. Recently, several studies have reported that bone marrow stem cells can improve hepatic fibrosis and liver function by regenerating hepatocytes in cirrhotic patients<sup>4-7</sup>. Stem cells were harvested from the bone marrow of cirrhotic patients in ongoing regenerative studies of hepatocytes<sup>8-9</sup>. In many studies, autologous stem cells were reinfused into patients via the hepatic artery<sup>7,8,10-11</sup> or portal vein<sup>7,9</sup>.

Several reports indicate that granulocyte colony-stimulating factor (G-CSF) can mobilize marrow stem cells to the peripheral blood. Peripheral stem cells collected by apheresis and reinfused via the hepatic artery or portal vein can improve liver function<sup>7,10-11</sup>.

It was also reported that peripheral blood monocyte infusion via the peripheral vein improved liver function and hepatocyte differentiation in patients

with decompensated liver cirrhosis after harvesting peripheral stem cells via apheresis under G-CSF injection<sup>12</sup>. Bone marrow aspiration, apheresis, and stem cell injection via the hepatic artery or portal vein are too invasive to use safely in decompensated cirrhotic patients with a poor general condition.

Liver fibrosis can reportedly be prevented by the Rg 1 component of red ginseng and improved by the saponin in ginseng<sup>13-14</sup>. When G-CSF is administered in combination with red ginseng, the release of hematopoietic stem cells from bone marrow may increase, and the increased number of hematopoietic stem cells in the peripheral blood would regenerate hepatocytes. There are no reports of improved liver function in end stage liver disease after G-CSF use in Korea. Therefore, we performed a preliminary clinical study to investigate the effects of adult stem cell therapy as a less invasive and effective method of regenerating hepatocytes by evaluating improvements in liver function and cirrhotic complications after injection of G-CSF.

## Patients and methods

### 1. Patients

Four patients with decompensated liver cirrhosis

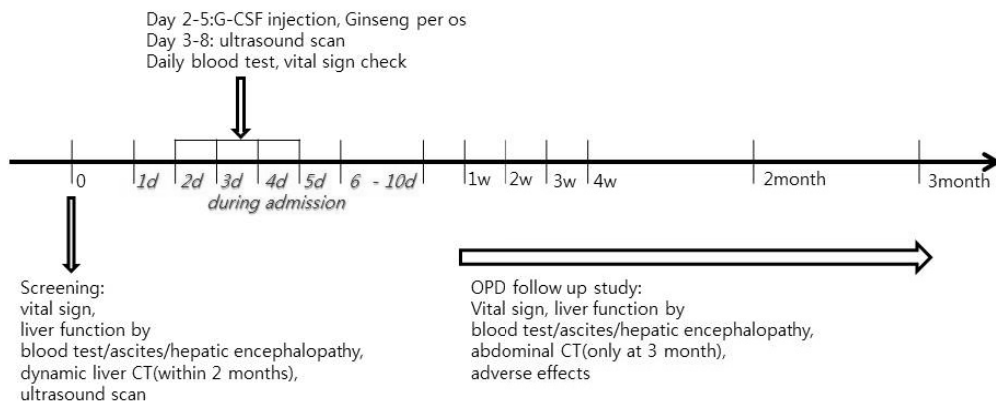


Fig. 1. Study protocol

were enrolled in this study between September 2013 and April 2014. Eligibility criteria included an age between 18 and 70 years, decompensated liver cirrhosis with a Child-Pugh score  $\geq 7$ , and refusal of liver transplantation. Exclusion criteria were the following: diagnosis of hepatocellular carcinoma or other malignancy, esophageal or gastric variceal bleeding within the past 6 months, type 1 hepatorenal syndrome, spontaneous bacterial peritonitis, portal vein thrombosis, a spleen diameter  $> 170$  mm, severe congestive heart failure, severe chronic obstructive pulmonary disease, severe coagulopathy, acute infection, or pregnancy/absence of reliable contraception. The study protocol was approved by our institution's Ethics Committee. Written informed consent was obtained from all patients.

## 2. Study protocol and methods - clinical study

The study protocol is summarized in Figure 1. Liver dynamic computed tomography (CT) was performed at screening to rule out hepatocellular carcinoma. Abdominal ultrasonography was used to determine initial spleen diameter. On admission, patients were injected with G-CSF to proliferate bone marrow stem cells for 4 consecutive days ( $5 \mu\text{g}/\text{kg}$  bid subcutaneously from admission day 2 to 5). In addition, patients were administered red ginseng (Red ginseng tablet, KGC; Korea ginseng corporation, Korea) for 4 consecutive days (2 tablets tid per os). Clinical signs were monitored and laboratory tests with peripheral bloods were performed daily to monitor changes of WBC, platelet and  $\text{CD34}^+$  cell counts. Ultrasonography was performed daily from day 3 to day 8 to monitor spleen diameter changes. All patients were discharged 5 days after G-CSF discontinuation (day 10 from admission).

After discharge, patients were followed-up weekly for the first month and monthly thereafter until 3

months. Clinical signs and laboratory data were evaluated at each visit. Abdominal CT was performed at the last visit (3 months after G-CSF injection). We analyzed improvements of Child-Pugh scores and Model for End-Stage Liver Disease (MELD) scores as primary endpoints<sup>15</sup>. The adverse effects were monitored. We also analyzed other parameters as secondary endpoints including improvement of refractory ascites and hepatic encephalopathy, serum albumin, serum bilirubin, serum sodium, and prothrombin time.

## 3. In vitro study

Bone marrow-derived cell mobilization was assessed considering the  $\text{CD34}^+$  count in the peripheral blood by using flow cytometry (FC-500, Beckman Coulter, USA) at baseline and during day 3 to day 8 of admission. Expressions of CD29, CD44, CD105, and CD184, which represent mesenchymal stem cell markers, were assessed by using flow cytometry from peripheral blood mononuclear cells (PBMCs) at baseline and on the day after G-CSF injection completion (day 6 of admission).

## 4. Statistical analysis

Statistical analyses were performed using IBM SPSS Win. (ver. 19.0). Summaries of demographic and clinical characteristics were obtained using descriptive analysis, with mean, maximum, minimum, and standard deviation values presented for quantitative variables and frequencies and percentages presented for qualitative variables. The changes of the laboratory data by follow-up days after G-CSF injection were performed using a repeated-measure one-factor analysis. And multiple comparison result was performed by contrast.

## Results

### 1. Clinical outcomes and follow-up

Four male patients with decompensated liver cirrhosis were included in the study. Demographic and clinical characteristics are shown in Table 1. All

**Table 1.** Demographic and clinical characteristics

Variable	n(%) or mean(SD)
Age, mean(SD)	61.50(4.73)
Male ratio, n (%)	4(100)
Etiology of cirrhosis	
Alcohol, n (%)	3(75)
Alcohol + HBV, n (%)	1(25)
Median spleen LD(cm)	12.28
Severity of cirrhosis	
Child-Pugh score	11.25
MELD score	15.25

Abbreviations: SD, Standard Deviation; LD, longitudinal diameter; HBV, hepatitis B virus; MELD, Model for End-Stage Liver Disease

4 patients had hepatic encephalopathy and refractory ascites at the time of inclusion.

#### Case 1

A 68-year-old male, alcoholic liver cirrhosis with diabetes mellitus had a Child-Pugh scores 11 points and MELD scores 12 points at admission. During the

2 month  
3 month

Abbreviations: CPS, Child-Pugh scores; PT, prothrombin time; MELD, Model for End-Stage Liver Disease study in admission period, he did not show clinical/laboratory deterioration and adverse events after G-CSF injection. Three months later, Child-Pugh scores decreased to 8 points and also MELD scores decreased to 11 points. Ascites and hepatic encephalopathy had disappeared during the follow-up period. Laboratory parameters such as serum albumin, bilirubin and serum-sodium were also improved (Table 2).

#### Case 2

A 62-year-old male, alcoholic liver cirrhosis was admitted for clinical study. His Child-Pugh and MELD scores were 10 and 13 points respectively. He was discharged after the completion of G-CSF/red ginseng therapy without any adverse events and deterioration of liver function. His refractory ascites and hepatic encephalopathy were slightly improved and more controllable as compared to baseline. His clinical and laboratory findings at 1

**Table 2.** Clinical outcomes of patients

	Follow up	CPS	MELD	T-bilirubin (mg/dl)	Albumin (g/dL)	Na (mEq/L)	K (mEq/L)	PT (sec)	Ammonia ( $\mu$ mol/L)
PT 1	screening	11	12	2.37	2.3	125	4.7	15.1	39.4
	4 week	9	14	1.6	2.8	135	4.3	17.6	17
	2 month	8	12	1.1	3.2	138	4.4	16.2	93
	3 month	8	11	0.7	3.5	136	4.5	15.2	36
PT 2	screening	10	13	1.93	2.6	125	4.3	15.2	85.6
	4 week	12	17	3.1	2.5	137	4.3	15.8	42
	2 month								
	3 month								
PT 3	screening	13	18	3.73	2.7	127	4.6	20.6	75.1
	4 week	12	19	5.35	3.1	132	4.5	19.4	99
	2 month	10	15	2.7	3.0	135	3.4	18.0	59
	3 month	10	19	4.8	2.9	129		20.5	49
PT 4	screening	11	18	3.08	3.2	131	5.3	18.2	79.8
	4 week								

month after G-CSF/red ginseng therapy were not changed compared to baseline. He was admitted to another hospital due to a traffic accident after his 1-month visit. However, 1 week before his 2-month visit, the patient developed a sore throat and fever with leukocytosis (WBC, 12,950/mm<sup>3</sup>). He was immediately treated with antibiotics but developed acute renal failure and a recurrence of hepatic encephalopathy. At that time, he was transferred to our hospital. However, despite aggressive treatment he died after 2 days. We thought his acute systemic infection and acute renal failure were not associated with this clinical trial.

### Case 3

A 58-year-old male, alcoholic liver cirrhosis was admitted for clinical study. He had a Child-Pugh scores 13 points and MELD scores 18 points. He had also recurrent hepatic encephalopathy and refractory ascites. During admission period for clinical trial, there showed no complications and clinical/laboratory deterioration. Three months later, Child-Pugh scores decreased to 10 points. MELD scores were not changed and ascites was persistent. However, degree of hepatic encephalopathy did not worsen during the study.

### Case 4

A 58-year-old male, alcoholic and hepatitis B virus related liver cirrhosis with diabetic nephropathy, was admitted for clinical study. His Child-Pugh and MELD scores were 11 points and 18 points, respectively. During admission period for clinical trial, renal failure occurred after large volume paracentesis 7L for refractory ascites. Serum creatinine was increased to 3.7 mg/dL (baselines 1.3 mg/mL). It was assumed that prerenal failure is caused by circulatory blood volume decrease on diabetic nephropathy due to large volume paracentesis. Also hepato-renal syndrome was not ruled out. Consequently, he was treated with continued albumin

(20 g/day) and terlipressin injection for 2 weeks. Finally his serum creatinine was improved to 1.7 and he discharged. But before his 1-month visit, he was withdrawn from the study because of a violation of the study protocol regarding esophageal or gastric variceal bleeding within the recent 6 months. We noticed 3 weeks after study inclusion that he had esophageal variceal bleeding 5 months prior to study enrollment.

Clinical outcomes of patients are shown in [Table 2](#). The Child-Pugh scores of Patient 1 decreased consistently (11 points at screening). Thus, at study end, Child-Pugh scores significantly improved to 8 points. MELD scores improved from 12 points to 11 points. Improvements were also observed for other parameters such as serum albumin, bilirubin, and sodium. In addition, ascites and hepatic encephalopathy were not observed during the follow-up period.

Child-Pugh scores decreased from 13 points to 10 points in Patient, but MELD scores did not change. This patient had ascites and hepatic encephalopathy throughout the study, but the degree of refractory ascites and frequency of hepatic encephalopathy did not worsen during the study.

## 2. Spleen size, CD34+ counts after G-CSF injection, and red ginseng intake

Spleen size, WBC, hemoglobin, and CD34<sup>+</sup> counts significantly increased, with peak values observed 4 days after G-CSF injection ( $p < 0.05$ ). Afterwards, each parameter decreased as shown in [Table 3](#). Each patient's spleen size increased after G-CSF injection ([Figure 2](#)). Neither severe increase in spleen size nor complications according to an increased spleen size were observed in all 4 patients.

## 3. In vitro study

The cell surface markers expressed on PBMCs were analyzed before and after G-CSF injection.

CD105 expression decreased after G-CSF injection while CD29, CD44, and CD184 expressions increased after G-CSF injection (Figure 3).

#### 4. Discussion

Bone marrow stem cells mostly consist of hematopoietic stem cells along with a small amount of mesenchymal stem cells. In nearly all studies, stem cells were obtained through bone marrow aspiration. In addition, stem cells were obtained by apheresis after achieving increased bone marrow stem cell separation under G-CSF injection. After these stem cells were separated into mesenchymal stem cells or CD34 cells and allowed to multiply, they were re-injected into the patient's hepatic artery or hepatic vein<sup>4,19-21</sup>. However, these methods are highly invasive and challenging, and difficult to apply safely in decompensated cirrhotic patients with a very poor general condition. Therefore, less invasive and simpler treatment methods are needed.

In addition, it has been reported that the mobilization of bone marrow stem cells using G-CSF is a well-tolerated procedure without severe toxicity in cirrhotic patients<sup>19</sup>. Several studies reported that Rg 1 of red ginseng could prevent liver fibrosis and that saponin exerts a curative effect on liver fibrosis<sup>22-24</sup>. Considering the non-invasiveness of the mobilizing procedure, we performed this pilot study in order to evaluate the combined effect of subcutaneous G-CSF and red ginseng.

In our study, the G-CSF injection process was shown to be safe and well tolerated in all 4 patients. It has been known that G-CSF induces splenic extramedullary hematopoiesis in peripheral blood cell donors and hematologic malignancy patients, but this increase in spleen size very rarely results in splenic rupture<sup>25-27</sup>. Another report described spontaneous splenic rupture after the administration of G-CSF in an allogeneic donor of peripheral blood stem cells<sup>26</sup>. Thus, abdominal ultrasonography was carefully

performed to measure spleen diameter increases in all patients during admission days 3~8 (Figure 1). Spleen size changes were carefully monitored for the assessment of spleen rupture risk. Spleen sizes increased in all 4 patients. However, no adverse effects occurred, and all 4 patients completed the course of G-CSF injections and the study during the admission period.

Two patients (Patient 2 and Patient 4) were lost to follow-up. Patient 2 was dropped out due to death that had nothing to do with this study. Patient 4 was withdrawn from the study because of a violation of the study protocol regarding esophageal or gastric variceal bleeding within the recent 6 months.

Ultimately, 2 patients completed the study. Patient 1 and Patient 3 demonstrated improvement of liver function. As shown in Table 2, Child-Pugh scores decreased in these 2 patients at study completion. In Patient 1, MELD scores also decreased. Ascites and hepatic encephalopathy had disappeared during the follow-up period. Various parameters such as serum albumin, bilirubin and serum-sodium were also improved. In Patient 3, MELD scores were unchanged, but his degree of hepatic encephalopathy and refractory ascites did not worsen during the study.

The number of CD34<sup>+</sup> cells in peripheral, a marker of hematopoietic stem cells, increased the day after G-CSF injection and reached peak levels after 4 days of consecutive injection in all 4 patients. We think that the improvement of liver function in the 2 patients in our study was due to CD34<sup>+</sup> PBMC mobilization by G-CSF. Other studies also showed that G-CSF-mobilized CD34<sup>+</sup> stem cells were responsible for the clinical improvement observed in patients with liver damage<sup>7,10</sup>. G-CSF can improve liver function via mobilized PBMCs homing to the injured liver<sup>5</sup>.

In a previous study<sup>7</sup>, 5 cirrhotic patients were subcutaneously administered 520  $\mu$ g of G-CSF daily for 5 days, to increase the number of circulating

CD34<sup>+</sup> cells. Leukopheresis was performed on day 5. After selecting CD34<sup>+</sup> cells, these were reinfused into patients via the hepatic artery or portal vein. No complications or specific side effects related to the procedure were observed. Three of the 5 patients showed decrease in serum bilirubin, and 4 of 5 showed increase in serum albumin. In a study of 9 patients with alcoholic liver cirrhosis, PBMCs were mobilized by G-CSF injection, and autologous CD34<sup>+</sup> cells were expanded in vitro and injected into the hepatic artery<sup>10</sup>. There were significant decreases in serum bilirubin, alanine transaminase, and aspartate transaminase. The Child-Pugh score improved in 7 out of the 9 patients, while 5 patients had improvement in ascites on imaging. However, the above two studies used apheresis for collecting PBMCs, and stem cells were infused via the hepatic artery or portal vein. Therefore, these studies are more invasive than our study. We only injected G-CSF subcutaneously in combination with red ginseng intake, and this method showed a similar effect in improving liver function compared to other studies<sup>5,7,10</sup>.

The small number of patients and high rate of attrition were the limitations of this study. However, G-CSF for PBMC mobilization was a safe and tolerable treatment in decompensated cirrhotic patients.

In the in vitro study, markers of mesenchymal stem cells including CD29, CD44, and CD184 increased after G-CSF injection. These data support the idea that G-CSF injection induces mobilization of hematopoietic stem cells, which contain components of mesenchymal stem cells.

In conclusion, our study verified the stability of G-CSF injection, making a long term or repetitive G-CSF study for hepatocyte regeneration by PBMCs feasible. Additional red ginseng intake was not shown to have any adverse effects or side effects. Our results suggest that G-CSF injection with red ginseng intake will be a candidate treatment for the patients with decompensated liver cirrhosis who are

not suitable for other treatment. A randomized controlled clinical trial is warranted for investigating the role of G-CSF-mobilized PBMCs in decompensated liver cirrhosis.

### Acknowledgements

This study was supported by the foundation of the Comprehensive and Integrative Medicine Institute, Daegu, Korea.

### Conflict of Interest

The authors report no conflicts of interest.

### References

1. Haagsma EB, Hagens VE, Schaapveld M, van den Berg AP, de Vries EG, Klompmaker IJ, et al. Increased cancer risk after liver transplantation: a population-based study. *J Hepatol.* 2001;34: 84-91.
2. Park HW, Hwang S, Ahn CS, Kim KH, Moon DB, Ha TY, et al. De novo malignancies after liver transplantation: incidence comparison with the Korean cancer registry. *Transplant Proc.* 2012;44:802-805.
3. Preston SL, Alison MR, Forbes SJ, Direkze NC, Poulson R, Wright NA. The new stem cell biology: something for everyone. *Mol Pathol.* 2003;56:86-96.
4. am Esch JS 2nd, Knoefel WT, Klein M, Ghodsizad A, Fuerst G, Poll LW, et al. Portal application of autologous CD133<sup>+</sup> bone marrow cells to the liver: a novel concept to support hepatic regeneration. *Stem Cells.* 2005;23: 463-470.
5. Terai S, Ishikawa T, Omori K, Aoyama K, Marumoto Y, Urata Y, et al. Improved liver function in patients with liver cirrhosis after autologous bone marrow cell infusion therapy.

- Stem Cells. 2006;24:2292-2298.
6. Yannaki E, Anagnostopoulos A, Kapetanios D, Xagorari A, Iordanidis F, Batsis I, et al. Lasting amelioration in the clinical course of decompensated alcoholic cirrhosis with boost infusions of mobilized peripheral blood stem cells. *Exp Hematol*. 2006;34:1583-1587.
  7. Gordon MY, Levicar N, Pai M, Bachellier P, Dimarakis I, Al-Allaf F, et al. Characterization and clinical application of human CD34+ stem/progenitor cell populations mobilized into the blood by granulocyte colony-stimulating factor. *Stem Cells*. 2006;24:1822-1830.
  8. Peng L, Xie DY, Lin BL, Liu J, Zhu HP, Xie C, et al. Autologous bone marrow mesenchymal stem cell transplantation in liver failure patients caused by hepatitis B: short-term and long-term outcomes. *Hepatology*. 2011;54:820-828.
  9. Kharaziha P, Hellstrom PM, Noorinayer B, Farzaneh F, Aghajani K, Jafari F, et al. Improvement of liver function in liver cirrhosis patients after autologous mesenchymal stem cell injection: a phase I-II clinical trial. *Eur J Gastroenterol Hepatol*. 2009;21:1199-1205.
  10. Pai M, Zacharoulis D, Milicevic MN, Helmy S, Jiao LR, Levicar N, et al. Autologous infusion of expanded mobilized adult bone marrow-derived CD34+ cells into patients with alcoholic liver cirrhosis. *Am J Gastroenterol*. 2008;103:1952-1958.
  11. Han Y, Yan L, Han G, Zhou X, Hong L, Yin Z, et al. Controlled trials in hepatitis B virus-related decompensate liver cirrhosis: peripheral blood monocyte transplant versus granulocyte-colony-stimulating factor mobilization therapy. *Cytotherapy*. 2008;10:390-396.
  12. Yan L, Han Y, Wang J, Liu J, Hong L, Fan D. Peripheral blood monocytes from patients with HBV related decompensated liver cirrhosis can differentiate into functional hepatocytes. *Am J Hematol*. 2007;82:949-954.
  13. Geng J, Peng W, Huang Y, Fan H, Li S. Ginsenoside-Rg1 from *Panax notoginseng* prevents hepatic fibrosis induced by thioacetamide in rats. *Eur J Pharmacol*. 2010;634:162-169.
  14. Peng XD, Dai LL, Huang CQ, He CM, Yang B, Chen LJ. Relationship between anti-fibrotic effect of *Panax notoginseng* saponins and serum cytokines in rat hepatic fibrosis. *Biochem Biophys Res Commun*. 2009;388:31-34.
  15. Christensen E, Schlichting P, Fauerholdt L, Gluud C, Andersen PK, Juhl E, et al. Prognostic value of Child-Turcotte criteria in medically treated cirrhosis. *Hepatology*. 1984; 4:430-435.
  16. Terai S, Sakaida I, Yamamoto N, Omori K, Watanabe T, Ohata S, et al. An in vivo model for monitoring trans-differentiation of bone marrow cells into functional hepatocytes. *J Biochem (Tokyo)*. 2003;134:551-558.
  17. Sakaida I, Terai S, Yamamoto N, Aoyama K, Ishikawa T, Nishina H, et al. Transplantation of bone marrow cells reduces CCl4-induced liver fibrosis in mice. *Hepatology*. 2004;40:1304-1311.
  18. Terai S, Sakaida I, Nishina H, Okita K. Lesson from the GFP/CCl4 model-translational research project: The development of cell therapy using autologous bone marrow cells in patients with liver cirrhosis. *J Hepatobiliary Pancreat Surg*. 2005;12:203-207.
  19. Gaia S, Smedile A, Omede P, Olivero A, Sanavio F, Balzola F, et al. Feasibility and safety of G-CSF administration to induce bone marrow-derived cells mobilization in patients with end stage liver disease. *J Hepatol*. 2006;45:13-19.
  20. Handgretinger R, Gordon PR, Leimig T, Chen X, Buhning HJ, Niethammer D, et al. Biology and plasticity of CD133+ hematopoietic stem cells. *Ann N Y Acad Sci*. 2003;996:141-151.
  21. Potgens AJ, Schmitz U, Kaufmann P, Frank HG. Monoclonal antibody CD133-2 (AC141)



- against hematopoietic stem cell antigen CD133 shows crossreactivity with cytokeratin 18. *JHistochem Cytochem.* 2002;50:1131-1134.
22. Geng JW, Peng W, Huang YG, Fan H, Li SD. Gnisengoside-Rg1 from *Panax notoginseng* prevents hepatic fibrosis induced by thioacetamide in rats. *Euro J Pharm.* 2010;634:162-169
  23. Peng Xd, Dai Ll, Huang CQ, He CM, Yang B, Chen LJ. Relationship between anti-fibrotic effect of *Panax notoginseng* saponins and serum cytokines in rat hepatic fibrosis *Biochemical and Biophysical Research Communications.* 2009; 388:31-34.
  24. Lee NH, Son CG. Systematic Review of Randomized Controlled Trials Evaluating the Efficacy and Safety of Ginseng. *J Acupunct Meridian Stud.* 2011;4:85-97
  25. Shimizu H, Miyazaki M, Wakabayashi Y, Mitsuhashi N, Kato A, Ito H, et al. Vascular endothelial growth factor secreted by replicating hepatocytes induces sinusoidal endothelial cell proliferation during regeneration after partial hepatectomy in rats. *J Hepatol.* 2001;34:683-689.
  26. Becker PS, Wagle M, Matous S, Swanson RS, Pihan G, Lowry PA, et al. Spontaneous splenic rupture following administration of granulocyte -colony-stimulating factor (G-CSF): occurrence in an allogeneic donor of peripheral blood stem cells. *Biol Blood Marrow Transplant.* 1997;3(6): 341-343.
  27. Balaguer H, Galmes A, Ventayol G, Bargay J, Besalduch J. Splenic rupture after granulocyte -colony-stimulating factor mobilization in a peripheral blood progenitor cell donor. *Transfusion.* 2004;44:1260-1261.