

# 전산화단층촬영검사에서 하지의 3D 혈관조영검사를 위한 새로운 고정기구의 유용성 평가

## Evaluation of Usefulness in New Immobilization Device with 3D CT Angiography for Lower Extremity

장근조\*, 권대철\*\*

예수병원 영상의학과\*, 서울대학교병원 영상의학과\*\*

Keun-Jo Jang(kunjochang@hanmail.net)\*, Dae-Cheol Kweon(kdc@radiol.snu.ac.kr)\*\*

### 요약

3차원 전산화단층촬영 검사에서 하지 혈관조영술을 위해서는 움직임이 없어야 한다. 표재질환의 검사는 환자의 하지가 테이블에 접촉하지 않도록 해야 한다. 새로운 고정기구를 하지 조영술을 위해 새롭게 개발되었다. 본 연구에서는 새로운 하지조영술용 고정기구를 고안하여 개발하였다. 개발된 고정기구는 2개로 구성되었고, 폴리우레탄 레진의 재료를 이용하였다. 둔부에 위치하는 패드와 족부를 고정할 수 있도록 만들었다. 새로운 고정기구를 100명의 환자를 대상으로 전산화단층촬영영상을 획득하였으며 이들 영상을 5등급으로 구분하여 고정기구를 사용하지 않은 환자와 영상을 비교하여 평가하였다. 고정기구를 사용하여 전산화단층촬영으로 하지 혈관조영검사를 시행한 경우 매우 편안하고 움직임이 없이 혈관을 묘출하는데 효과적으로 사용됨을 확인하였다.

■ 중심어 : | 조영제 | 고정기구 | 3차원 영상 | 전산화단층촬영 |

### Abstract

Our objective was to develop and evaluate a non-invasive device for rigid immobilization and surface disease non-contact of the table in the lower extremity during CT angiography. The immobilization device consists of two components. The patient's lower limb device stabilizing elements made of polyethylene resin soft materials, and pelvis parts foam pad is used for non-contact surface. In a prospective study the lower extremity device was used in patients who underwent a CT angiography of the lower limb. Immobilization with our device was well tolerated by all patients. The quality of the resulting images in the popliteal and infrapopliteal region was rated by five-point scale. The rigid immobilization resulted in a complete absence of motion artifacts. The new device is an effective, well tolerated and easily used immobilization that is suitable of use in 3D lower extremity CT angiography.

■ keyword : | Contrast Medium | Immobilization Device | 3D Imaging | Computed Tomography |

## I. Introduction

Computed tomographic (CT) angiography is a

non-invasive and rapid imaging technique that shows high sensitivity and specificity in the detection of

접수번호 : #070123-001

접수일자 : 2007년 01월 23일

심사완료일 : 2007년 03월 14일

교신저자 : 권대철, e-mail : kdc@radiol.snu.ac.kr

arterial and venous injuries in the extremities [1]. However, movement during CT angiography is a common cause of reduced image quality [2].

Immobilization patient's motion may be a serious problem in lower limb CT angiography, particularly when using a three-dimensional (3D) software program displayed of volume rendering, maximum intensity projection (MIP), surface shade display (SSD) and multi-planar reformation (MPR). CT images provide 3D information, plaque morphology, they can help unravel overlapping structures.

Patient movement causes misregistration artifacts that may lead to errors in diagnosis, or the need for repeat runs to be performed with a consequent increase in both the load of iodinated contrast medium and radiation dose. Motion artifacts are a major source of image degradation in CT angiography. Rigid fixation of the target structure is also of great importance in imaging-guided biopsies and interventional procedures, to avoid misplacing introduced instruments and repeating punctures [3].

The cause of patient movement relate to discomfort caused by prolonged procedures on an uncomfortable examination table, painful pressure from constraining devices or involuntary movement after injection of contrast medium. Even the injection of a bolus of non-ionic contrast media frequently procedures a warm "flush" or heat sensation in the lower limbs or perineum which can lead to involuntary movement [2]. Stable immobilization of the patients is essential for diagnostic CT angiography. Our objective was to develop and evaluate a non-invasive device for rigid immobilization and surface disease non-contact of the table in the upper and lower extremity during CT angiography.

## II. Patients and Methods

### 1. CT Scanning without Immobilization Device

The lower limb was supported on pillows and foam, and the foot positioned of on the couch as was practical. In the without immobilization device patient's group there was complete absence in the lower limbs structures[Fig. 1]. Failure obtained sout image and volume rendered projection in the knee region for lower limb CT angiography[Fig. 2]. Stable immobilization of the patient is essential for diagnostic angiography. Patient movement during angiography is a common source of image degradation artefacts which may result in image interpretation errors.

### 2. Immobilization Device

Our simple potential solution to this problem was to employ a immobilization device in an attempt minimize the generation of any to reduce motion-related artifacts from musculoskeletal activity.

The immobilization device was designed to restrain the foot and knee in order to allow application of a lower extremities . The device was designed on the basis of the following criteria: restriction of limb rotation, simplicity and fast speed of use, patient comfort, accommodation of variable of foot size, and hygiene. Lower limb device stabilizing elements made of polyethylene resin soft materials, pelvis parts foam pad is used for noncontact surface[Fig. 3] and lower extremity immobilization device straps of feet[Fig. 4].

The patient foot is secured with velcro tape to grip the foot and leg firmly. Following construction and final adjustments , the device underwent a one-month trial: it has subsequently been used for all leg examinations.

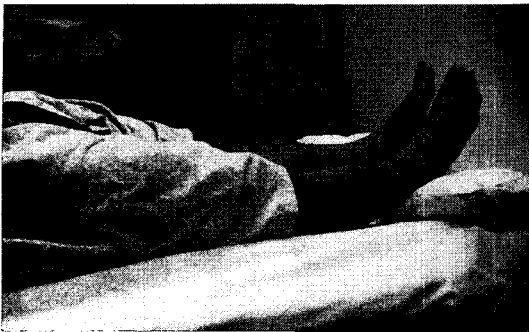

Fig. 1. A picture of patient's legs laid on pillow for lower extremity CT angiography without immobilization device. Authors found that lower knee contacts with couch in most cases.

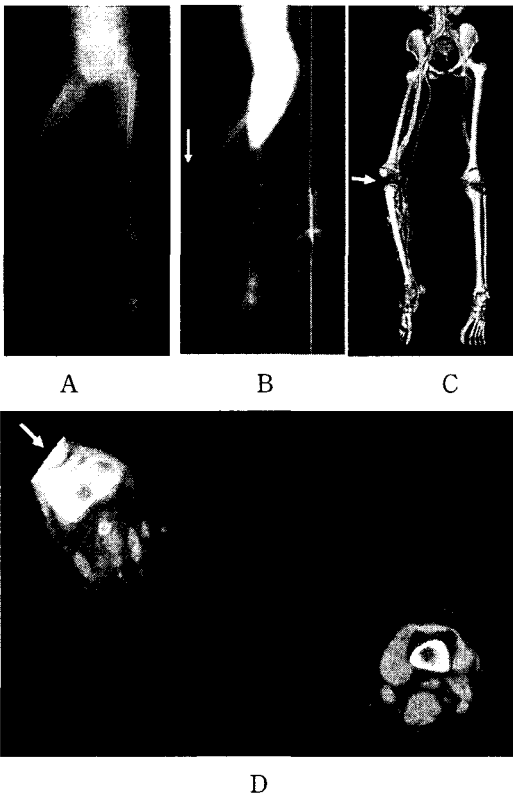

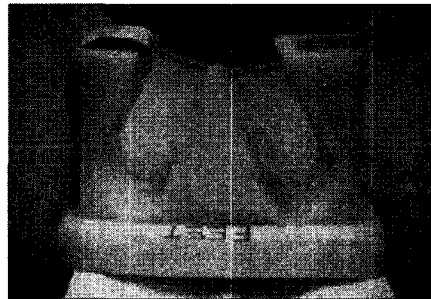


Fig. 2. A 75-year-old man with arteriosclerosis. Patient is supine with legs placed in non-immobilization device and non- straps of feet. A, Failure sout image (arrow) of

anteriorposterior projection and lateral projection (B). C, Failure knee region(arrow) image of MDCT angiogram obtained in volume rendered projection. D, Axial CT scan image of non-visualized left knee(arrow) for lower limb CT angiography.



A



B

Fig. 3. Two adjustable supports are positioned under patient's legs. New device of immobilization for lower limbs 3D CT angiography. A, Cushioned foam pad and immobilization device. B, Lower limbs immobilization device straps secured across top of feet.

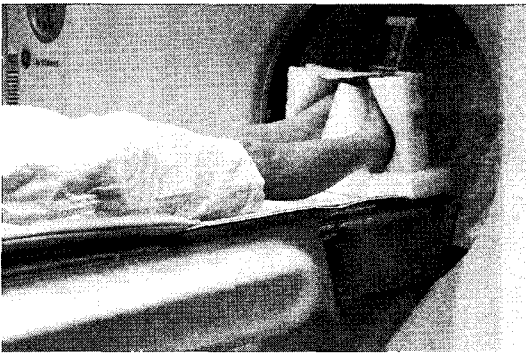

Fig. 4. Photograph shows healthy female volunteer demonstrating position used in three-dimensional CT angiographic protocol. Patient is supine with legs placed in leg-immobilizing device. One adjustable cushioned supports is non-contact of skin positioned under patient's legs.

### 3. Patient Population

The usefulness of the device was evaluated in a prospective study in 100 patients (67 men, 33 women; age range 35-75 years, mean age 54 years) and compared with a control group of 100 patients without immobilization (66 men, 34 women; age range 36-72 years, mean age 54 years). Informed consent was obtained from all patients after the nature of the procedure had been fully explained.

When have used in the immobilization device of patients undergoing CT angiography examination during 8 months January to September 2004. In the patients included in our study, CT examinations had been performed at our institution with a with a Somatom Sensation sixteen scanner (Siemens, Erlangen, Germany) ( $n = 57$ ), a Lightspeed Ultra (General Electric Medical Systems, Milwaukee, Wis) ( $n = 33$ ), or an MX 8000 four detector row scanner (Philips Medical Systems, Cleveland, Ohio) ( $n = 10$ ).

### 4. CT Technique

Each patient received 150 mL of a nonionic contrast material (iopromide, Ultravist 370; Schering Korea, Seoul, Korea) through an 18-gauge angiographic catheter inserted into a forearm vein.

CT scans were routinely obtained with the patient in a supine position during full inspiration. The contrast material was injected at a rate of 3 mL/sec with an automatic power injector.

Helical CT was performed with a multi-detector row scanner at the following parameters: detector collimation, 1.25 mm; table pitch, 1:1; reconstruction intervals, 1 mm, 120 kVp, 512×512 matrix, AutoMA (100-450 mA), Noise index (11) and standard algorithm.

In Somatom Sensation sixteen MDCT scanner with a 1.0 mm slice thickness, 0.5 mm reconstruction interval, at 120 kVp, 150 effective mAs, at a pitch of 1.25, and with a 0.5 seconds gantry rotation time. and reconstruction interval, 0.625 mm. When the MX 8000 scanner was used, the parameters were as follows: detector collimation, 2.5 mm; table speed, 20 mm/sec; section thickness, 3.2 mm; and reconstruction interval, 1.6 mm. All thin-section axial images were transferred to a workstation running a PC-based 3D reconstruction program (Rapidia 2.8; Infinitt, Seoul).

### 5. CT Image Analysis

In a prospective study the upper and lower extremity device was used in patients who underwent a CT angiography of the upper and lower extremities. The CT scans acquired in the 100 patients were reviewed in consensus by two cardiovascular radiologists and five radiological technologists who had no knowledge of the final radiologic or pathologic findings.

We graded the area of the artery region in popliteal and infrapopliteal on the thin-section CT scans with

a five-point scale. The quality of the resulting images in the region were rated by experienced radiologist and radiological technologists by consensus as follows: excellent (immobilized extremity bone and vessels); very good (only minimal contours of the bone and vessels mobilized), good (sufficient for diagnosis), poor (bone and vessels immobilized but insufficient for diagnosis), very poor (vessels not visible).

All CT scans were reviewed on a picture archiving and communication system workstation (Marotech, Seoul, Korea). According to our hospital's institutional review board, we were required to have formal approval or informed patient consent for the limited and anonymous review of patient data required for this study.

### 6. Statistical Analysis

Statistics were calculated and compared for the different sex of subjects and between immobilization device and control groups using t-tests with SPSS 9.0 computer software (SPSS Inc., Chicago, IL, U.S.A.). The values are expressed as a means  $\pm$  SD. Statistical significance was considered at  $p < 0.05$ .

### III. Results

Immobilization with our device was well tolerated by all patients. The rigid immobilization resulted in a complete absence of motion artifacts. The device is well tolerated easy and quick to apply, and is now routinely used in limb angiography. Due to the absence of motion artefacts in the patients in the fixated group, there was complete absence of bony structures of the patients in the popliteal and infrapopliteal region.

A through examination of the immobilized extremity after the procedure did not reveal any abnormalities such as bruises or swelling. No complications directly attributable to the immobilization device occurred. The average time for examination the CT angiography was about 20-30 minutes. The device did not interfere with imaging procedure in any way. During the examination the patients were explicitly asked about pain or any other discomfort, which all denied.

### 1. Immobilization with Device for CT Angiography

All patients reported no pain or discomfort. A through examination of the immobilized extremity after the procedure did not any motion artifacts. The device did not interfere with the imaging study in any way. Lower extremity immobilization device used of axial image[Fig. 5], scout[Fig. 6A], MIP[Fig. 6B] and volume rendering display with lower extremity immobilization device[Fig. 6C].

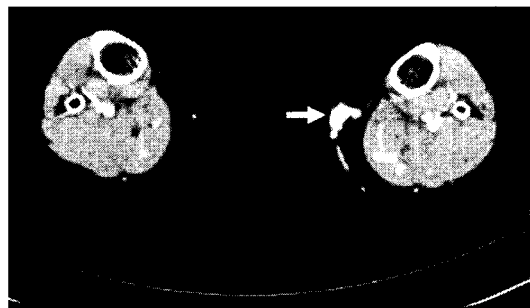


Fig. 5. A 56-year-old woman with varicose vein. Immobilized axial CT scan obtained at level of distal knee of lower limb device immobilized and non-contact of couch with varicose vein (arrow) disease.

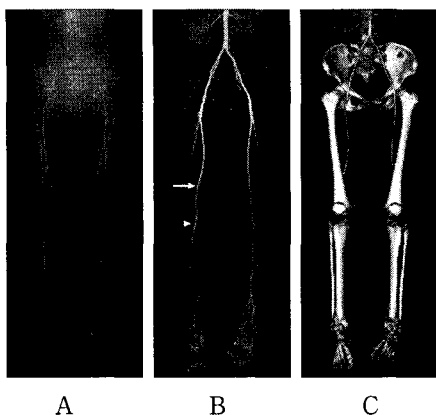


Fig. 6. A 54-year-old woman with diabetes mellitus. Lower extremity immobilization device scanned of patient. A, Scout image B, MIP image revealed an excellent clearly of the popliteal(arrow) and infrapopliteal(arrowhead) artery. C, Volume rendering image shows lower extremity with immobilization device.

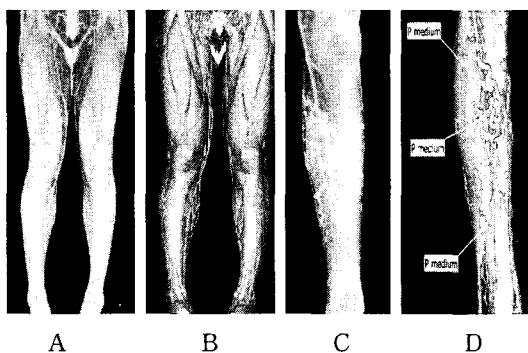


Fig. 7. Photographs display for lower immobilization device of varicose vein patient. A, Surface revealed of volume rendered projection image. B, Muscle and vessels well displayed of volume rendered projection image. C, Volume-rendered MDCT angiogram shows of varicose vein. D, 3D image processing of volume rendered image.

Angiography of a varicose vein patient who where immobilized with the new immobilization device. Due to absence of motion artifacts and well displays of the

vessels. Muscle and vessels well displayed of volume rendered projection image. Three-dimensional mage processing of volume rendered image[Fig 7].

## 2. Image Quality rated of Immobilization Device

[Table 1] gives detailed information about the image quality in the infrapopliteal region for the CT lower extremity angiography. A new lower extremity with immobilization device image results as follows: excellent(55), very good(29), good(14), poor(0), very poor(0) and without immobilization device results: excellent(6), very good(30), good(46), poor(12), very poor(6). The improvement in image quality was especially obvious in the patients who had undergone a previous CT examination without adequate immobilization. The new immobilization device itself can also be used for fixation in CT angiography.

Immobilization device and without immobilization of image quality did significantly differ between groups ( $p < 0.05$ ).

Table 1. Lower limb 3D angiography image quality rated of immobilization vs without immobilization device

	Immobilization device(n=100)	Without Immobilization device(n=100)
Excellent	55	6
Very good	29	30
Good	14	46
Poor	2	12
Very Poor	0	6

## IV. Discussion

In a recent paper have been described the reasons

for and problems related to motion artifacts during DSA of the lower legs: movement artifacts during angiography can be a source image quality compromise [3].

We describe a comfortable, adaptable and cheap restraint for 3D CT lower extremity angiography.

Many methods have been used to immobilize patients [4], particularly in radiotherapy [5-7] where accurate localization for therapy is essential. For the purposes of imaging, casts and moulds allow for rigid reproducible immobilization, but they are expensive and time-consuming. We believe that simple, non-invasive devices, such as bandages, foam pillows and sand bags or plastic film [8], are not sufficient for adequate immobilization. Frequently encountered sources of motion artifacts are involuntary movements caused by injection of contrast media, especially in the lower limb, uncooperative patients or in prolonged procedures [9].

Since pixel shift compensates for movements in two axes but not for rotations, this technique helps only in selected cases as well as being time-consuming.

Various devices have been used for immobilization of the head and neck, including casts; molds; vacuum mattresses; head clamps fixed to the skull, auditory meatus, and nasion; dental cast-based systems and invasive stereotactic frames attached to the skull by pins or rods.

In magnetic resonance imaging (MRI) any patient movement during image acquisition degrades image quality. This is particularly a problem with longer imaging sequences and any method of comfortable limb immobilization is of benefit [10]. The new immobilization device has been used only for CT examination. However, its use for MR imaging appears to be possible, provided that the new device is used of place the MR scan center.

CT angiography is a much less invasive than conventional angiography and more patient-friendly procedure contrast media is injected into a peripheral vein rather than an artery.

The ideal fixation system for angiography should grant quick, simple, clean, cheap and effective immobilization without causing patient discomfort [8].

CT angiography in the clinical setting was therefore enabled by the introduction of helical MD CT scanners. Most patients have CT angiography without being admitted to a hospital. It is also far more rapid and much less expensive. This technique is being used with increasing frequency to replace more standard angiography procedures.

## V. Conclusions

In conclusion, experience with out prototype have shown immobilization device seem to be a promising method for comfortable and effective immobilization of the extremities during CT angiography resulting in complete absence of motion artifacts. This new immobilization device was well so tolerated and easily used immobilization device that is suitable for use in CT angiography.

## Reference

- [1] M. M. Miller-Thomas, O. C. West, and A. M. Cohen, "Diagnosing Traumatic Arterial Injury in the Extremities with CT Angiography: Pearls and Pitfalls," *Radiographics* Vol.25, pp.S133-S142, 2005.
- [2] I. S. Francis, G. S. Dodge, and A. D. Platts, "The bead bag immobilization device," *Br J Radiol* Vol.72, No.861, pp.889-890, 1999.

- [3] R. J. Bale, M. Vogele, M. Rieger, W. Buchberger, P. Lukas, and W. Jaschke, "A new vacuum device for extremity immobilization," Am J Roentgenol Vol.172, No.4, pp.1093-1094, 1999.
- [4] R. J. Johnson and C. Collins, "Immobilisation of patients during wide-field radiotherapy," Br J Radiol Vol.44, pp.724-727, 1971.
- [5] R. L. Gerber, J. E. Marks, and J. A. Purdy, "The use of thermal plastics for immobilisation of patients during radiotherapy," Int J Radiat Oncol Biol Phys Vol.8, pp.1461-1462, 1982.
- [6] R. L. Gerber, J. E. Marks, and J. A. Purdy, "The use of thermal plastics for immobilisation of patients during wide field radiotherapy," Br J Radiol Vol.44, pp.724-727, 1971.
- [7] A. Jacobson, P. Iversen, C. Gadeberg, J. L. Hansen, and M. Hjelm-Hansen, "A new system for patient fixation in radiotherapy," Radiother Oncol Vol.8, pp.145-151, 1987.
- [8] L. H. Greenwood, M. H. Proto, and S. S. Morse, "Plastic-wrap restraint for lower extremity arteriography (letter)," Am J Roentgenol Vol.149, p.1082, 1987.
- [9] R. J. Bale, C. Lottersberger, M. Vogele, A. Prassl, B. Czermak, A. Dessl, R. A. Sweeney, P. Waldenberger, and W. Jaschke, "A novel vacuum device for extremity immobilisation during digital angiography: preliminary clinical experiences," Eur Radiol Vol.12, No.12, pp.2890-2894, 2002.
- [10] D. J. Lomas, R. Mackenzie, and A. Dixon, "Magnetic resonance imaging of the knee: does foot restraint improve the examination?," Br J Radiol Vol.66, pp.497-502, 1993.

저 자 소 개

장 근 조(Keun-Jo Jang)


정회원



- 1993년 8월 : 전북대학교 환경공학과 (공학석사)
- 2005년 2월 : 전주대학교 병원경영전공 (경영학박사)
- 1994년 3월 ~ 현재 : 서해대방사선과 겸임교수
- 2006년 3월 ~ 현재 : 전주대학교 방사선학과 겸임교수
- 1982년 2월 ~ 현재 : 예수병원 영상의학과 근무  
<관심분야> : 방사선관리, 핵의학

권 대 철(Dae-Cheol Kweon)

정회원



- 1991년 8월 : 경기대학교 산업공학과 공학사
- 2000년 3월 : 동국대학교 산업시스템공학과 공학석사
- 2005년 8월 : 아주대학교 의용공학과 (공학박사)
- 1987년 12월 ~ 현재 : 서울대학교병원 영상의학과 근무  
<관심분야> : 영상정보학, 의용공학