

사람 뇌의 3차원 영상과 가상해부 프로그램 만들기

° 정민석, 이제만, 박승규*, 김민구*
아주대학교 의과대학 해부학교실, 아주대학교 정보통신대학 정보및컴퓨터공학부*

Manufacture of 3-Dimensional Image and Virtual Dissection Program of the Human Brain

° M. S. Chung, J. M. Lee, S. K. Park*, M. K. Kim*
Department of Anatomy, Ajou University School of Medicine,
Division of Information and Computer Engineering, Ajou University College of Information and Communication*

ABSTRACT

For medical students and doctors, knowledge of the three-dimensional (3D) structure of brain is very important in diagnosis and treatment of brain diseases. Two-dimensional (2D) tools (ex: anatomy book) or traditional 3D tools (ex: plastic model) are not sufficient to understand the complex structures of the brain. However, it is not always guaranteed to dissect the brain of cadaver when it is necessary. To overcome this problem, the virtual dissection programs of the brain have been developed. However, most programs include only 2D images that do not permit free dissection and free rotation. Many programs are made of radiographs that are not as realistic as sectioned cadaver because radiographs do not reveal true color and have limited resolution. It is also necessary to make the virtual dissection programs of each race and ethnic group. We attempted to make a virtual dissection program using a 3D image of the brain from a Korean cadaver. The purpose of this study is to present an educational tool for those interested in the anatomy of the brain.

The procedures to make this program were as follows. A brain extracted from a 58-years old male Korean cadaver was embedded with gelatin solution, and serially sectioned into 1.4 mm-thickness using a meat slicer. 130 sectioned specimens were inputted to the computer using a scanner (420×456 resolution, true color), and the 2D images were aligned on the alignment program composed using IDL language. Outlines of the brain components (cerebrum, cerebellum, brain stem, lentiform nucleus, caudate nucleus, thalamus, optic nerve, fornix, cerebral artery, and ventricle) were manually drawn from the 2D images on the CoreIDRAW program. Multimedia data, including text and voice comments, were inputted to help the user to learn about the brain components. 3D images of the brain were reconstructed through the volume-based rendering of the 2D images. Using the 3D image of the brain as the main feature, virtual dissection program was composed using IDL language. Various dissection functions, such as dissecting 3D image of the brain at free angle to show its plane, presenting multimedia data of brain components, and rotating 3D image of the whole brain or selected brain components at free angle were established.

This virtual dissection program is expected to become more advanced, and to be used widely through Internet or CD-title as an educational tool for medical students and doctors.

INTRODUCTION

Brain disease is one of the leading causes of death. For the purpose of accurate diagnosis and treatment of brain disease, it is essential for doctors to understand the anatomical structure of the brain. Three-dimensional (3D) structure of the brain is so complex that it is impossible to get accurate knowledge from anatomy books [1]. Traditionally, medical students have studied anatomy by dissecting a cadaver. However, there are not enough opportunities to dissect a cadaver even for a medical person. Currently, plastic models of human organs are being widely used, but they are not as detailed as cadaver and they do not permit free dissection.

Due to the popularization of the multimedia computer, various anatomy programs have been developed. However, most anatomy programs include only two-dimensional (2D) images that do not permit free dissection and free rotation. To overcome this problem, virtual dissection programs including 3D images have been developed [2, 3, 4, 5, 6]. Most of these programs are made of radiographs, which do not reveal true color and have limited resolution, are not as realistic as sectioned cadaver [7, 8]. Thus, 3D image based on the sectioned cadaver is thought to be more realistic than that based on the radiographs.

The shape and size of organs differ according to race and ethnic groups. Therefore, it is necessary to make the dissection program of each race and ethnic group.

We attempted to make a virtual dissection program using a 3D image of the brain from a Korean cadaver to present an educational tool for those interested in the anatomy of the brain.

MATERIALS AND METHODS

The brain extracted from a 58-year old male Korean cadaver was used.

For the serial section, the brain was embedded with gelatin solution (8 gm%) and frozen. After removing the embedding box, a brain block was acquired. The brain block was serially sectioned into 1.4 mm-thickness using a meat slicer (HFS-330L, FUJEE™). As a result, 130 serially sectioned specimens were obtained.

Each specimen was inputted to the computer using a scanner (ScanJet 4c, Hewlett Packard™) with 420×456 resolution and true color.

In this study, 2D images were not aligned properly. To correct this problem, an alignment program was required. The alignment program was composed using IDL language (version 5.0 for windows). The alignment program operated as follows: If two neighboring sections were selected, both outlines would be represented. While the left section remained stationary, the right section would move and rotate with the panel. Accuracy of alignment could be immediately verified through the two vertical planes selected by the user.

Segmentation of the brain components was performed manually on the CorelDRAW program (version 6.0). Outlines of the cerebrum, cerebellum, brain stem, lentiform nucleus, caudate nucleus, thalamus, optic nerve, fornix, cerebral artery, ventricle were drawn with different colors in each of the 2D images of the brain.

Multimedia data, including text and voice comments, about the brain components were prepared. For example, the text comments about brain stem was 'Brain stem is densely packed with many vital structure such as long ascending and descending pathways, and specific nuclear groups including the nuclei of the cranial nerves.'

After stacking the 130 images, 3D images of the brain were reconstructed through the volume-based rendering. Shading was added to the 3D image of the brain to represent the depth of brain convolution. Using the 3D image of the brain as the main feature, a virtual dissection program was composed using IDL language. We named this program VIRDI BRAIN as an abbreviation of 'VIRtual Dissection program of the BRAIN'. We made VIRDI BRAIN which have the following functions: first, dissecting 3D image of the brain at free angle to show its plane; second, presenting multimedia data of brain components; thirdly, rotating 3D image of the whole brain or selected brain components at free angle.

RESULTS AND DISCUSSION

The alignment program developed in this study is expected to be applied to various fields of morphology. For example, this program can be used to align the serially sectioned microscopic specimens for making a 3D image of the microscopic structure.

On VIRDI BRAIN, the sectional direction of 3D image of the brain can be placed orthogonally (horizontally, sagittally, coronally) or at free angle. The section will be followed by its plane.

The sectioned plane can be transformed from the raw image to the segmented image. And it is possible to zoom in that plane. Additionally, multimedia data, including text and voice comments, about the brain components were added and linked to help the user to learn about the specific parts of the brain. So if the user clicks on the brain component by the computer mouse, text and voice comments about that component will be displayed.

VIRDI BRAIN can rotate a 3D image of the whole brain.

On VIRDI BRAIN multiple selections of the 10 brain components are possible. 3D images of the selected components can be shown at free angle.

VIRDI BRAIN is expected to become more advanced together with magnetic resonance image, and to be widely used through Internet or CD-title as an educational tool for medical students and doctors.

REFERENCES

1. K. L. Moore, Clinically Oriented Anatomy. 3rd ed. Baltimore, Williams & Wilkins, pp. 692-702, 1992
2. B. F. Richards, L. Sawyer, G. Roark, "Use of low-cost 3-D images in teaching gross anatomy", *Med Teach*, Vol. 9, pp. 305-308, 1987
3. N. J. Mankovich, D. R. Robertson, A. M. Cheeseman, "Three-dimensional image display in medicine", *J Digit Imag*, Vol. 3, pp. 69-80, 1990
4. I. Mano, Y. Suto, M. Suzuki, M. Iio, "Computerized three dimensional normal atlas", *Radiat Med*, Vol. 8, pp. 50-54, 1990
5. U. Tiede, M. Bomans, K. H. Höhne, A. Pommert, M. Riemer, T. Schiemann, R. Schubert, W. Lierse, "A computerized three dimensional atlas of the human skull and brain", *Am J Neuroradiol*, Vol. 14, pp. 551-559, 1993
6. K. H. Höhne, B. Pflesser, A. Pommert, M. Riemer, T. Schiemann, R. Schubert, U. Tiede, "A new representation of knowledge concerning human anatomy and function", *Nat Med*, Vol. 1, pp. 506-511, 1995
7. M. Bomans, K. H. Höhne, U. Tiede, M. Riemer, "3D-segmentation of MR-images of the head for 3D-display", *IEEE Trans Med Imag*, Vol. 9, pp. 177-183, 1990
8. K. H. Höhne, W. A. Hanson, "Interactive 3d segmentation of MRI and CT volumes using morphological operations", *J Comput Assist Tomogr*, Vol. 16, pp. 285-294, 1992

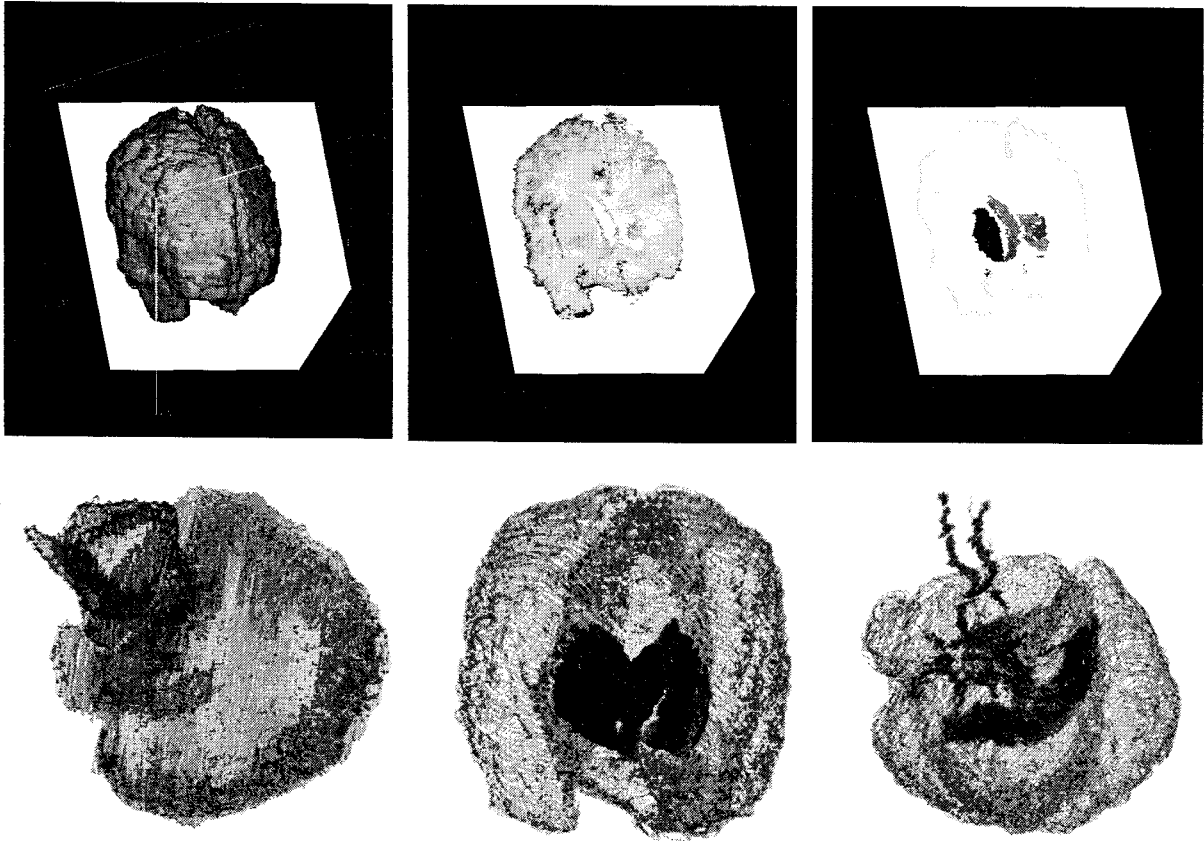


Figure. Free angle section of the brain (top left) and its plane showing raw image (top middle) and segmented image (top right). Three-dimensional image of the selected brain components rotated at various angles. Cerebrum, cerebellum, brain stem (bottom left); cerebrum, lentiform nucleus, caudate nucleus, thalamus (bottom middle); cerebrum, cerebral artery, ventricle (bottom right).