

목뼈의 바깥쪽 굽힘과 회전에 대한 이상 치료

이현창*, 신성윤^o

*원광대학교 디지털콘텐츠공학과

^o군산대학교 컴퓨터정보통신공학과

e-mail: hclglory@wku.ac.kr*, s3397220@kunsan.ac.kr^o

Abnormal Treatment of Lateral Flexion and Rotation of Cervical Spine

Hyun-Chang Lee*, Seong-Yoon Shin^o

*Dept. of Digital Contents Eng., Wonkwang University

^oSchool of Computer Infor. and Comm. Eng., Kunsan Natl. University

● 요약 ●

본 논문에서는 중요한 목뼈 부분의 움직임을 다루도록 한다. 특히 목뼈의 기증 굽힘과 돌림에 대한 각도를 측정하고 고통을 수반하는지를 파악한다. 측정된 각도가 정상수치를 크게 벗어나거나 통증을 동반하면 이상이 있는 것으로 간주하여 치료법을 제시한다.

키워드: 안쪽돌림(Lateral Flexion), 회전(Rotation), 통증(Pain)

I. Introduction

A forward head posture occurs more frequently in white-collar workers and students sitting at the desk for a long time. Axial rotation is essential for everyday life without neck pain. Currently, there is a lack of research on neck rotation.

[1] is to investigate the effects of visual feedback on the neck rotation angle, lateral flexion angle, lateral flexion movement onset time, and neck muscle activity in adults with anterior head posture.

II. Later Flexion and Rotation

The rotation of the neck bone is rotated to the left and right axes as shown in Fig. 1. Here, the angle is $60^{\circ} \sim 90^{\circ}$. Also, be careful that the jaw does not touch the shoulder line. In the neck bone, the lateral flexion and rotation occur together but in different directions.

In other words, move the ear towards the shoulder direction. The normal range of joint movement is $20^{\circ} \sim 45^{\circ}$ to the right and left. It is possible to compare the movements of each of the stages by promoting the transverse processes when moving. Precautions must be taken not to move the shoulder towards the ear at this time.

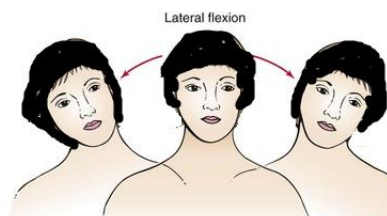


Fig. 1. Lateral Flexion

The rotation of the neck bone is rotated to the left and right axes as shown in Fig. 2. Here, the angle is $40^{\circ} \sim 90^{\circ}$. Also, be careful that the jaw does not touch the shoulder line. In the neck bone, the lateral flexion and rotation occur together but in different directions.

In other words, instruct the person to rotate the head to the right and left. Turn the head to the direction without pain first. The normal range of rotation is $40^{\circ} \sim 90^{\circ}$ to the right and left. Precautions must be exercised to prevent chin coming in contact with the shoulder at this time. In addition, the point at which lateral flexion occurs at the time of rotational movement is the end point of rotation.

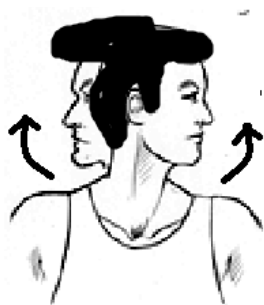

Fig. 2. Rotation

III. Experiments

Experiments were conducted on subjects of 30 peoples at fifties. The experimental results are shown in Table 1. The lateral flexion problem is a person with a problem in the lateral flexion of the neck bone. In other words, the angle of the lateral flexion is less than 20° to 45° , or it causes pain. Rotation problem is a person with a problem of rotation of the neck bone. That is, the angle is less than 60° to 90° or causes pain. Both problems have both lateral flexion and rotation problems.

Table 1. Experimental Results

Categories	lateral flexion problem	rotation problem	both problems
person (total: 30)	5	6	4

IV. Conclusions

Cervical spine is the section between the cranium and thoracic vertebrae among the vertebrae and is the bone structure that forms the neck section of the body. It supports the body and maintains the balance through the ligaments and muscles from the cranium to backbone. In addition, it has the function of protecting the spinal cord and enabling the movement of the spine.

REFERENCES

- [1] No-Yul Yang, Jae-Seop Oh, "Effects of the Visual Biofeedback on the Movement Patterns of the Neck Lateral Flexion and Muscle Activation of Sternocleidomastoid during Neck Rotation in Adults with Forward Head Posture," J Korean Soc Phys Med, 9(4) (2014), 425-432