

Intestinal trematode infections in the villagers in Koje-myon, Kochang-gun, Kyongsangnam-do, Korea

Woo-Young Son¹⁾, Sun Huh^{2)*}, Soo-Ung Lee²⁾, Ho-Choon Woo³⁾ and Sung-Jong Hong³⁾

Department of Parasitology²⁾, College of Medicine, Hallym University, Chunchon 200-702, Koje-myon Health Center¹⁾, Kochang-gun, Kyongsangnam-do 670-830, Department of Parasitology³⁾, College of Medicine, Gyeong-Sang National University, Chinju 660-280, Korea

Abstract: An epidemiological study for the intestinal trematode infection of the villagers was done in Koje-myon, Kochang-gun, Kyongsangnam-do, Korea in March, 1994. Of 116 stool specimens examined, total helminthic ova positive cases were 13 (11.2%) and cumulative ova positive cases 21 (18.1%): *Echinostoma hortense* 11 cases (9.5%), *Metagonimus* sp. 6 cases (5.2%), and *Clonorchis sinensis* 4 cases (3.4%). After the treatment and purgation, variable numbers of *E. hortense*, 6 to 227 per person, were collected from 7 echinostome egg positive cases, together with *M. takahashii* in 6 cases. Three adult flukes of *E. cinetorchis* were collected from one person and one *Stellantchasmus falcatus* was recovered from another case. This mountainous village was proved to be one of the endemic foci of echinostomiasis in Korea.

Key words: *Echinostoma hortense*, *Echinostoma cinetorchis*, *Stellantchasmus falcatus*, *Clonorchis sinensis*, *Metagonimus takahashii*, epidemiology, Korea

INTRODUCTION

The study area, Koje-myon is a rural village with a population of 2,024 at the study time. This village was surrounded by Togyusan (Mt.) and located in Kochang-gun, Kyongsangnam-do, Korea. A tributary of Nakdonggang (River) crosses the village, which is not polluted yet. The villagers usually enjoy eating raw fresh water fishes caught in the stream. From their eating habit, it was suspected that villagers could be infected with intestinal trematodes transmitted by freshwater fish. We tried to identify whether there was endemic of any

kind of intestinal trematode infection, especially *Echinostoma hortense* infection. This report also describes rare human cases infected with *E. cinetorchis* and *Stellantchasmus falcatus*.

MATERIALS AND METHODS

A total of 116 stool specimens was collected from villagers residing in Nongsan-ri, Kunghang-ri and Ponggye-ri in Koje-myon, Kochang-gun, Kyongsangnam-do, Korea in early March 1994. The specimens were examined once by formalin ether sedimentation method for the presence of helminth ova at Department of Parasitology, College of Medicine, Hallym University, Chunchon. Clinical data from egg positive persons were recorded. We prescribed praziquantel (Distocide®, Shinpoong Pharmaceutical Co., Seoul, Korea) 10 mg/kg single

• Received June 15 1994, accepted after revision July 20 1994.

• Present address: Woo-Young Son, Department of Surgery, College of Medicine, Aju University, Suwon 441-749, Korea

* Corresponding author

dose *p.o.* to egg positive villagers. One hour after prescription, they intook magnesium sulfate 30-50 g. Loose stools or diarrhea from subjects were collected during day time. Stools were transferred to Department of Parasitology, College of Medicine, Gyeongsang National University, Chinju. They were searched for the presence of worm under a stereomicroscope. Collected worms were wet-mounted and identified for the species differentiation. Number of eggs per gram of feces (EPG) was counted by Stoll's dilution egg count technique. EPG and worm collection data were analyzed for worm fecundity.

RESULTS

Egg positive rates and clinical data

Of 116 stool specimens examined, a total number of helminthic ova positive was 13 (11.2%) and cumulative ova positive was 21 (18.1%); Ova of *Echinostoma hortense* 11 (9.5%), *Metagonimus* sp. 6 (5.2%), and *Clonorchis sinensis* 4 (3.4%). Size of 50 echinostome eggs from stools of villagers was 115.0-152.5 × 70.0-95.0 μm (mean 132.4 × 81.2 μm). *Metagonimus* egg positive persons were all concomitantly infected with *E. hortense* (Table 1). Egg positive rate by age was 25% in the thirties, 35.7% in the forties, 7.3% in the fifties, 8.8% in the sixties and 5.6% in the seventies. All below thirties and above seventies were negative. Egg positive rate in female was 10.6%, and that in male, 12.2%. From 13 egg positive persons, the

gastrointestinal symptoms were listed as they complained of: epigastric fullness (53.8%); loose stool or diarrhea(38.5%); constipation(23.1%); epigastric soreness (7.7%); nausea and vomiting (7.7%). One person did not complained of any symptom. Every infected person had a history of eating raw freshwater fishes caught at the stream. The woman who was infected with *Stellantchasmus falcatus* had a history of eating raw mullet flesh (*Mugil cephalus*) at the restaurant out of her village 6 months before examination.

Worm recovery and worm fecundity

Ten *E. hortense* egg positive persons were subjected for the worm recovery. However, three of them failed in defecation due to severe constipation. A total of 452 worms of *E. hortense* (6-227 worms/person) was collected from 7 persons. We also collected *Metagonimus takahashii* (8-402 worms/person), 3 *Echinostoma cinetorchis* and one *Stellantchasmus falcatus* concomitantly (Table 1). Result of *E. hortense* EPG was shown in Table 1. From those results, we could calculate the egg per day per worm (EPDPW) of *E. hortense* when daily stool weight was estimated as 200 g. Mean EPDPW was 3,882.

Description of worms

***Echinostoma hortense*:** Body is elongated, and measures 8.0 mm in length. The head collar is reniform with 27 collar spines including 4 end group spines on each sides. Characteristics of this worm such as 4 end

Table 1. Trematodes collected from echinostome egg positive villagers

Subjects			No. of worms		
Name	Age	Sex	<i>Echinostoma hortense</i> (EPG ^a)	<i>Metagonimus takahashii</i>	Others
Park, OO	54	M	227 (1,200)	402	<i>Echinostoma cinetorchis</i> (3)
Park, OO	49	M	6 (350)	43	
Poh, OO	49	M	22 (150)	106	
Lee, OO	31	M	18 —	8	
Choi, OO	47	F	18 (250)	21	
Kim, OO	42	F	8 (150)	0	
Kim, OO	42	F	153 (2,050)	42	<i>Stellantchasmus falcatus</i> (1)
Mean			65	104	

^aNo. of eggs per gram of feces

group spines, length of eggs (mean $132.4 \times 81.2 \mu\text{m}$), laterally deviated ovary, and two distinct testes (T) at equatorial portion are well agree to the description of *E. hortense* Asada 1926 (Fig. 1).

***Echinostoma cinetorchis*:** Adult worm is elongated, dorsoventrally flattened, and measures 10.6 mm in length. The head collar was reniform, and bearing 36 to 38 spines, including six end group spines on each side. This species is characterized by the variation or abnormalities of the testes. Testis single in a worm and none in another 2 worms. Remaining one testis is post-equatorial in

position. Ovary ellipsoidal in shape is in median line of the body. Mehlis' gland large and immediately behind ovary (Fig. 2). From these characters, we identified this trematode as *E. cinetorchis* Ando and Ozaki, 1923.

***Metagonimus takahashii*:** Body small 1.53 mm long and 0.83 mm wide, Characteristics of this worm such as no posteriormost location of right testis, separated left testis from the right one, distribution of uterine tubule over the left testis and intertesticular junction, vitellaria passing through the posteriormost portion of the body coincide with the *M. takahashii* Suzuki 1930 (Fig. 3)

***Stellantchasmus falcatus*:** Body small 0.71 mm long and 0.40 mm wide, pyriform to ovoidal in shape, covered with fine scale-like spines (Fig. 4). Oral sucker subterminal and 0.06 mm in diameter. Ventral sucker small, 0.05 mm in diameter, muscular, displaced right to median line, and armed with minute spines

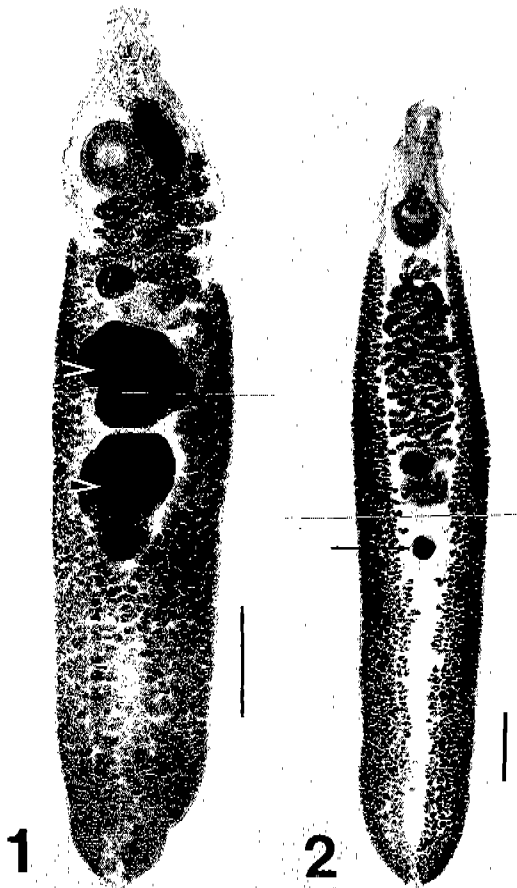


Fig. 1. *Echinostoma hortense* collected from Park OO (54/M) in Table 1 has laterally deviated ovary, and two distinct testes (arrowheads) at equatorial portion. Acetocarmine stained. Bar = 1 mm. **Fig. 2.** One of 3 *Echinostoma cinetorchis* collected from Park OO (54/M) in Table 1 has one reduced testis (arrow) located posteriorly to ovary. Acetocarmine stained. Bar = 1 mm.

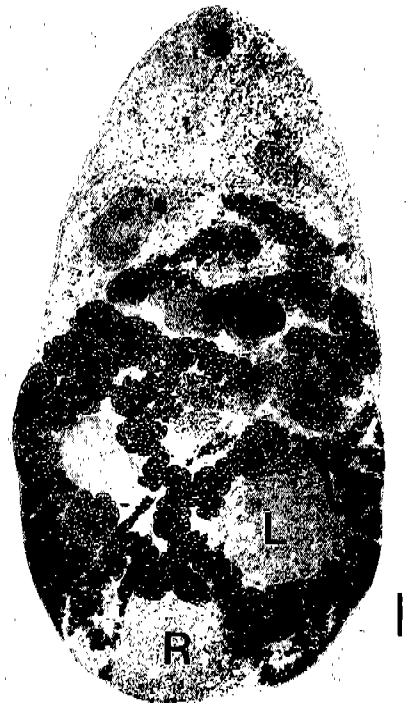

Fig. 3. *Metagonimus takahashii* collected from Park OO (54/M) in Table 1. No posteriormost location of right testis (R), separated left testis (L) from the right one, distribution of uterine tubule over the left testis and intertesticular junction, vitellaria passing through the posteriormost portion of the body. Unstained. Bar = 100 μm .

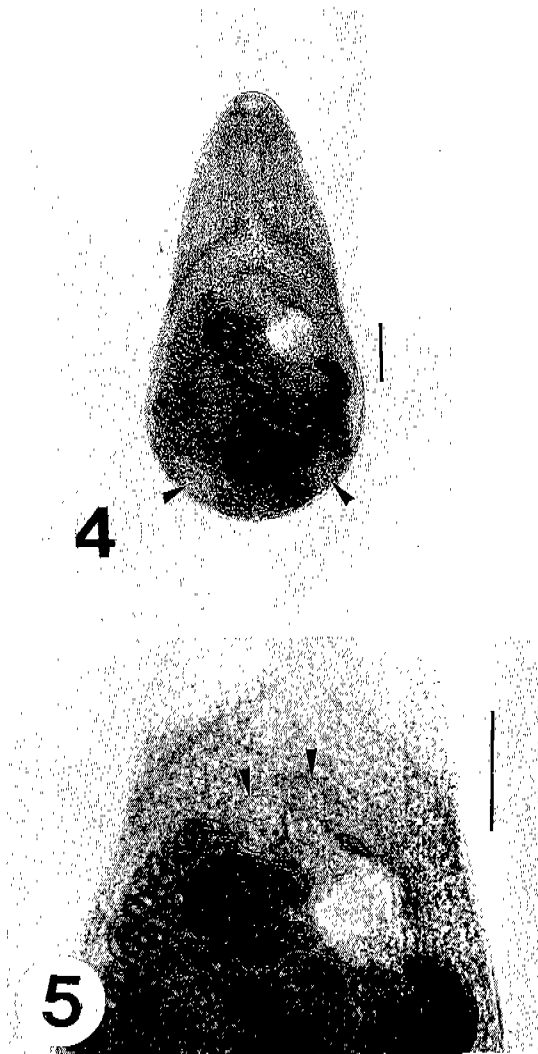


Fig. 4. *Stellantchasmus falcatus* collected from Kim OO, showing well-developed seminal vesicle, two testes (arrowheads) and many uterine eggs. Unstained. Bar = 100 μ m. **Fig. 5.** Magnification of Fig. 2 showing ventrogenital sac (arrowheads) between ventral sucker and distal part of seminal vesicle. Bar = 200 μ m.

on its inner rim. Ventrogenital sac slightly submedian to left side and contains gonotyl and male and female genital pores. Seminal vesicle bipartite and located obliquely between the levels of ventral sucker and ovary (Fig. 5). Uterus winding convoluted between ventral sucker and posterior end. Intrauterine eggs yellowish, oval and a little elongated in shape with slightly attenuated anterior end, and 30.8

μ m long and 14.7 μ m wide. These morphological characters coincide well with those of *S. falcatus* Onji and Nishio, 1915.

DISCUSSION

Egg positive rate at rural area in Kyongsangnam-do, 1992, was recorded as *Ascaris lumbricoides* 0.5%, *Trichuris trichiura* 1.0%, *C. sinensis* 21.6% in nationwide surveys of intestinal helminthiasis (Ministry of Health and Social Affairs, and Korea Association of Health, 1993). In this village, the prevalence of clonorchiasis is much lower than that of Kyongsangnam-do. Echinostomiasis is one of the endemic diseases in Far east and South-east Asian countries. Of them, *E. revolutum*, *E. echinatum*, *E. malayanum* and *Euparyphium ilocanum* are frequently found in south-east Asia (Huffman and Fried, 1990; Waikagul, 1991). *E. hortense*, *E. cinetorchis* and *Echinochasmus japonicus* infection in human have been recorded in Korea, Japan and China (Chai and Lee, 1990 & 1991; Ujiie, 1936; Miyamoto *et al.*, 1983; Zhu *et al.*, 1986). From 1980, human echinostomiasis had been known to be as the endemic intestinal trematodiasis in Korea. Seventy six cases of *E. hortense*, five cases of *E. cinetorchis*, and one case of *Echinochasmus japonicus* infection were already confirmed in Korean (Chai and Lee, 1990). Not only Chongson-gun but also upper reaches of the Namhangang such as Umsong-gun, Yongwol-gun have been known as endemic foci of echinostomiasis (Ahn and Ryang, 1986; Lee *et al.*, 1988; Ryang, 1990; Chai *et al.*, 1993). We add Koje-myon, Kochang-gun as another endemic focus of echinostomiasis in Korea.

Clinical findings from persons with *E. hortense* infection was variable, and did not well correlate with worm burdens. First human case in Korea with one worm did not complained of any trouble (Seo *et al.*, 1983). Other cases complained of abdominal pain and diarrhea, tenesmus, easy fatiguability, and dizziness. Fifty nine *E. hortense*-infected villagers in Chongsong-gun, Korea did not complain of specific gastrointestinal symptoms although their degrees of eosinophilia were positively correlated with the worm number.

Their infections were found during the screening of the intestinal helminthiases incidentally. The records from volunteers who ate metacercariae of *E. hortense* showed generalized weakness, diarrhea, epigastric pain in a case with ten worms. On the other hand, only mild generalized weakness was in the one worm burden case (Seo *et al.*, 1985). Out of four volunteers in Japan who were experimentally infected with metacercariae of *E. hortense*, only one revealed violent diarrhea and abdominal pain from 3rd-4th week post-infection (Miyamoto *et al.*, 1984). The upper small intestine of rats experimentally infected with *E. hortense* showed a marked destruction of villi (Lee *et al.*, 1990). Those histopathological changes are expected to be seen also in human infection. The explanation of symptomless infection might be as a difference of immunological reaction. In this study, the egg positive villagers complained of gastrointestinal symptoms. However, those non-specific symptoms were believed as endurable conditions for them, since they did not visit the health center with those kinds of problems by themselves.

Egg laying capacity is one of the parameter for the detection of infection through stool examination. Egg laying capacity of *E. hortense* is fairly variable according to its age in the host. Maximum egg production per worm of *E. hortense* occurs during the 30-40th day post-infection (Seo *et al.*, 1985). Mean EPDPW was 1,478 in 35 villagers in Chongsong-gun. *E. hortense* collected in this study were in the form of juvenile or senile worms. Considering flukes in human intestine are not in same age, it is not easy to estimate the correct EPDPW from our data.

Ten human cases of *E. cinetorchis* infection had been recorded in Korea and Japan from 1930. Some infected cases complained of weight loss, loose stools. The others were found incidentally during stool examination. *E. cinetorchis* infection of 54 years-old man in this study can be reported here as the 11th case of human infection (Chai and Lee, 1990; Ryang, 1990; Takahashi *et al.*, 1930; Kawahara and Yamamoto, 1933; Moriyama, 1952), and as the 6th case in Korea. Human infection with *S. falcatus*, has been reported from Asia Pacific

countries: one in the Philippines (Africa and Garcia, 1935), 2 in Hawaii (Alicata and Schattenberg 1938; Glover and Alicata, 1957), 3 in Japan (Takahashi S, 1929; Kagei *et al.*, 1964), 6 in Thailand (Radomyos *et al.*, 1990) and 4 in Korea (Chai and Lee, 1990). Forty two-year-old woman in this study was the 17th human case of *S. falcatus* infection as literature concerned.

The loach (*Misgurnus anguillicaudatus*) has been known as most important source of echinostome infections. Further study should be pursued to explain the source of infection in this area. The mullet was known as second intermediate host of *S. falcatus* in Korea (Chai and Sohn, 1988). From the history of infected woman, the mullet is thought to be a source of infection of *S. falcatus* infection.

REFERENCES

- Africa CM, Garcia EY (1935) Heterophyid trematodes from man and dogs in the Philippines with description of three new species. *Phil J Sci* **57**: 253-167.
- Ahn YK, Ryang YS (1986) Experimental and epidemiological studies on the life cycle of *Echinostoma hortense* Asada, 1926 (Trematoda: Echinostomatidae). *Korean J Parasit* **24**: 121-136.
- Alicata JE, Shattenber OL (1938) A case of intestinal heterophyidiasis of man in Hawaii. *J Amer Med Ass* **110**: 1,100-1,101.
- Chai JY, Huh S, Yu JR, *et al.* (1993) An epidemiological study of metagonimiasis along the upper reaches of the Namhan River. *Korean J Parasit* **31**: 99-108.
- Chai JY, Lee SH (1990) Intestinal trematodes of humans in Korea: *Metagonimus*, heterophyids and echinostomes. *Korean J Parasit* **28** (suppl.): 103-122.
- Chai JY, Lee SH (1991) Intestinal trematode infecting humans in Korea. *Southeast Asian J Trop Med Public Health* **22**(suppl): 163-170
- Chai JY, Sohn WM (1988) Identification of *Stellantchasmus falcatus* metacercariae encysted in mullets in Korea. *Korean J Parasit* **26**: 65-68.
- Glover BA, Alicat JE (1957) Intestinal heterophyidiasis. *Hawaii Med J* **16**: 636-688.
- Huffman JE, Fried B (1990) Echinostome and echinostomiasis. *Advances in Parasitology* **29**:

- 215-169.
- Kagei N, Oshima T, Ishikawa K, Kihata M (1964) Two case of human infection with *Stellantchasmus falcatus* Onji et Nishio, 1915 (Heterophyidae) in Kochi Prefecture. *Jap J Parasit* **13**: 472-478.
- Kawahara S, Yamamoto E (1933) Human case of *Echinostoma cinetorchis*. *Tokyo Iji Shinshi* (2840): 1794-1796.
- Lee SH, Noh TY, Sohn WM, Kho WG, Hong ST, Cahi JY (1990) Chronological observation of intestinal lesions of rats experimentally infected with *Echinostoma hortense*. *Korean J Parasit* **28**: 45-52.
- Lee SK, Chung NS, Ko IH, et al. (1988) An epidemiological survey of *Echinostoma hortense* infection in Chongsong-gun, Kyongbuk Province. *Korean J Parasit* **26**: 199-206.
- Ministry of Health and Social Affairs and Korea Association of Health (1993) Prevalence of intestinal parasitic infections in Korea-the fifth report-Appendix. pp 96-99. Seoul.
- Miyamoto K, Nakao M, Inaoka T (1983) Studies on the zoonoses in the Hokkaido, Japan 5. On the epidemiological survey of *Echinostoma hortense* Asada, 1926. *Jap J Parasit* **32**: 261-269.
- Miyamoto K, Naka M, Ohnishi K, Inaoka T (1984) Studies on the zoonoses on Hokkaido, Japan 6. Experimental human echinostomiasis. *Hokkaido Igakai Zasshi* **59**: 696-700.
- Moriyama S (1952) A human case of *Echinostoma cinetorchis* Ando et Ozaki, 1923. *Nippon Kiseichu Gakkai Kiji* **11**: 438-442.
- Radomyos S, Charoenlarp P, Radomyos B, Tungtrongchitr A (1990) Two human cases of *Stellantchasmus falcatus* (Trematoda, Heterophyidae) infection in northeastern Thailand. *Jap J Parasit* **39**: 7-11.
- Ryang YS (1990) Studies on *Echinostoma* spp. in the Chungju Reservoir and upper stream of the Namhan River. *Korean J Parasit* **28**: 221-233.
- Seo BS, Chun KS, Cahi JY, Hong SJ, Lee SH (1985) Studies on intestinal trematodes in Korea V. Development and egg laying capacity of *Echinostoma hortense* in albino rats and human experimental infection. *Korean J Parasit* **23**: 24-32.
- Seo BS, Hong ST, Chai JY, Lee SH (1983) Studies on parasitic helminths of Korea VII. A human case of *Echinostoma hortense* infection. *Korean J Parasit* **21**: 219-223.
- Takahashi S (1929) On the eggs of *Stellantchasmus falcatus* and *Pygidiopsis summa* found in human stools. *Okayama Igakai Zasshi* **41**: 1502-1513.
- Takahashi S, Ishii T, Ueno N (1930) The second human case of *Echinostoma cinetorchis* and case of tapeworm in man. *Tokyo Iji Shinshi*, No. 2678: 1,326-1,327.
- Ujiié N (1936) On the development, the structure of *Echinochasmus japonicus* and its parasitism in man. *Taiwan Igakai Zasshi* **35**: 535-546.
- Waikagul J (1991) Intestinal fluke infections in Southeast Asia. *Southeast Asian J Trop Med Public Health* **22**(suppl): 158-162.
- Zhu D, Lin J, Cheng Y, Liang C, Wang X (1986) Pyquitol treatment of *Echinochasmus japonicus* infection. *J Parasitol Parasitic Dis* **4**: 1-4.

=국문초록=

경상남도 거창군 고제면 주민들의 장흡충 감염상

한림대학교 의과대학 기생충학교실²⁾, 거창군 고제면 보건지소¹⁾,
경상대학교 의과대학 기생충학교실³⁾

손우영¹⁾, 허선²⁾, 이수응²⁾, 우호춘³⁾, 홍성중³⁾

주민들의 장내 기생충 감염상황 조사와 구충을 목적으로 1994년 3월 경상남도 거창군 고제면 주민 116명의 대변을 수거하여 포르말린-에테르 집란법으로 1번 검사하였다. 장흡충 총란 양성자들에게 프라지판텔을 투여하여 충체를 회수하였다. 주민들의 총란 양성율은 11.2%(13례)이었고 간흡충 3.4%(4례), 메타고니무스 5.2%(6례), 호르텐스극구흡충 9.5%(11례)이었다. 7명의 호르텐스극구흡충 양성자를 치료하여 평균 65(6-227)마리의 호르텐스극구흡충을 수집하였다. 그중 1례에서 이전고환극구흡충 3마리를 수집하였고, 다른 1례에서 수세미이형흡충 한마리를 수집하였다. 상복부 팽만감, 무른변, 설사, 변비가 감염자의 주된 위장관 증상이었다. 경남 거창군 고제면을 호르텐스극구흡충 유행지의 하나로 추가한다. 이 조사의 이전고환극구흡충증은 국내 제6례, 수세미이형흡충증은 국내 제5례이다.

(기생충학잡지 32(3): 149-155, 1994년 9월)