

The first human case of *Diplogonoporus balaenopterae* (Cestoda: Diphyllbothriidae) infection in Korea

Dong-Il CHUNG^{1)*}, Hyun-Hee KONG¹⁾, Chu-Hwan MOON¹⁾, Dong-Wik CHOI¹⁾,
Tae-Hyung KIM²⁾, Dong-Wook LEE²⁾ and Jung-Ja PARK³⁾

Department of Parasitology¹⁾, Kyungpook National University School of Medicine, Taegu 700-422, Department of Internal Medicine²⁾ and Department of Surgical Pathology³⁾, Masan Fatima Hospital

Abstract: The first human case of *Diplogonoporus balaenopterae* infection is reported in Korea. The patient was a 41-year old male who passed a part of cestode strobila, about 1 m long, spontaneously in his stool. He used to eat raw marine fish when he drank alcohol. The worm was identified as *D. balaenopterae* after morphological observations and literature review. Results of laboratory examination were within normal limits except for slight eosinophilia (6%) and extraordinarily high serum Ig E level (10.182 IU/ml).

Key words: *Diplogonoporus balaenopterae*, human, raw marine fish, case report, Korea

INTRODUCTION

In Korea, human infections by adult tapeworms belonging to Family Diphyllbothriidae have been considered to be rare, compared with relatively common infections by spargana, plerocercoid larvae of *Spirometra* (*Diphyllbothrium*) *erinacei* (Min, 1990). Human infections by adult diphyllbothriid tapeworms, *D. latum* (Cho *et al.*, 1971), *D. yonagoense* (Lee *et al.*, 1988) and *S. erinacei* (Lee *et al.*, 1984) have been reported in this country. Among the adult diphyllbothriid tapeworms, *D. latum* is the most frequently recorded species (Min, 1990). Recently, Lee *et al.* (1994) reported 2 cases of human infection by *D. latum* parvum type (*D. parvum*) although its taxonomic validity remained uncertain.

Diplogonoporus balaenopterae Loennberg, 1892 is known to infect whales, dogs, and human beings (Deliamure and Skrjabin, 1986).

The species of diplogonadic cestode recovered from man, like the other cestodes, also remained controversial in its taxonomy. According to Iwata (1967) and Deliamure and Skrjabin (1986), it seems reasonable to regard *D. grandis* as a synonym of *D. balaenopterae*. However, many parasitologists still recorded the species as *D. grandis* when recovered from human cases although they recognized the possibility that *D. grandis* as a synonym of *D. balaenopterae* (Kamo, 1969).

The authors found a human case of infection by a cestode quite different in morphology from the species already reported in this country. After a detailed morphological examination and literature review, we identified the cestode as *D. balaenopterae*. This is a new pseudophyllidean cestode infection in Korea.

CASE RECORD

The patient was a 41-year old Korean male, living in Masan-shi, Kyongsangnam-do. He found a part of tapeworm strobila spontaneously discharged in his stool. He

* Received May 13 1995, accepted after revision May 30 1995.

* Corresponding author

brought it to the Department of Surgical Pathology, Masan Fatima Hospital. The strobila was transferred again to the Department of Parasitology, Kyungpook National University School of Medicine, in May 1994.

He had habitually eaten raw marine fish and sometimes fresh-water fish, carp (*Cyprinus carpio*) when he drank alcohol. Nothing particular was in his family history and past history. He did not complain of any special symptoms. Results of laboratory examination were within normal limit except for slight eosinophilia (6%) without leukocytosis and extraordinarily increased serum immunoglobulin E level (10,182 IU/ml). Ultrasonography revealed the alcoholic fatty liver. Besides diplogonoporiasis balaenopterae, no special causes of eosinophilia and hyperimmunoglobulinemia E were found. He was treated with oral administration of niclosamide 2 g, but no scolex was recovered.

DESCRIPTION OF PARASITE

The strobila was about 1 m long and consisted of mature and gravid proglottids of a pseudophyllidean tapeworm with no scolex (Fig. 1). The morphology of segments is as follows: All the segments are much broad in their width and diplogonadic. Genital pores are situated at the anterior margin of each segment. Strobilar margins are slightly serrate. The strobila of the present specimen is traversed by more or less deep furrows on both ventral and dorsal surface. Among the four furrows on the dorsal surface, the inner or main 2 run correspondingly with the rows of the genital pores which open to the ventral side. Additional or secondary segmentation of the proglottids is observed occasionally. The proglottids newly developed by secondary segmentation appear to be immature ones which have, if any, immature reproductive organs. Incomplete tertiary segmentation is also taking place at some proglottids. The number of the uterine loops ranges from 3 to 5 on each side (Fig. 3). The vagina opens just beneath the opening of cirrus pouch at the bottom of genital atrium (Fig. 4). In cross section of the specimen, 2 sets of reproductive

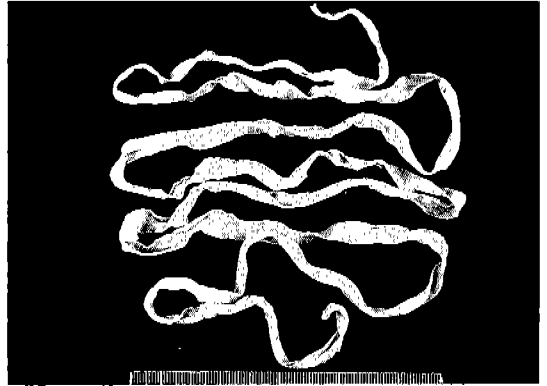


Fig. 1. An incomplete strobila of *D. balaenopterae* spontaneously passed from the present case. Its length was about 1 m, and the maximum breadth 7.8 mm.

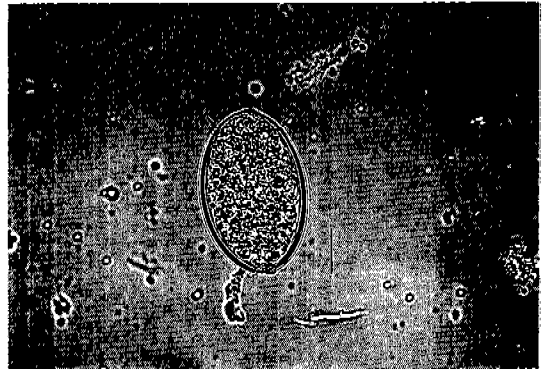


Fig. 2. An egg of *D. balaenopterae* obtained from proglottids. The operculum (arrows) is seen at one end. Bar = 18.4 μ m.

organs are observed at a level. Testes are divided into 3 groups, 2 lateral and one medial, by 2 genital pores in a proglottid. Follicular vitellaria are diffusely distributed throughout the cortical layer of the parenchyme (Fig. 5). In sagittal section of the proglottids, oval shaped cirrus pouch is surrounded by muscular fibers. Spherical seminal vesicle is observed just posterior to the cirrus pouch at a right angle.

Proglottid is measured 0.65-1.01 mm in length, 4.66-7.83 mm in width and 0.18-0.51 mm in thickness. The distance between genital openings in a segment is 0.97-1.62 mm, about a fifth of the segmental width. Transverse and sagittal sections (Fig. 6) show that the

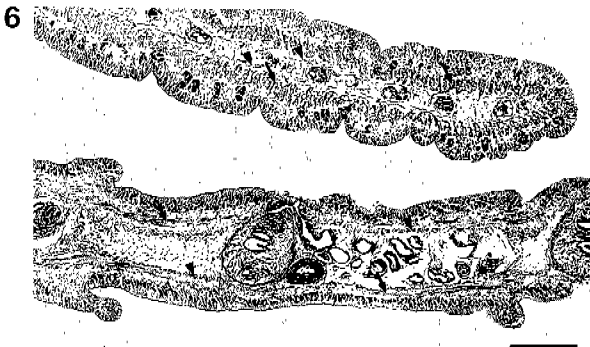
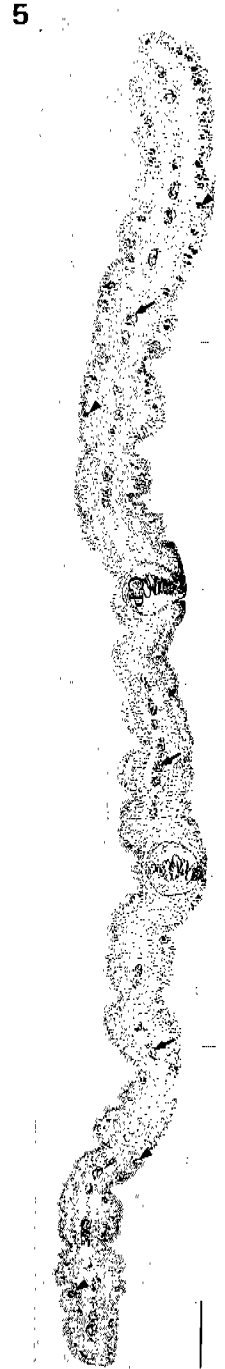


Fig. 3. Mature (M) and newly developing (ND) proglottids of *D. balaenopterae*, showing two sets of genital openings and rosette-like uteri. Secondary (arrows) and tertiary (arrow head) segmentations of proglottids are observed. Bar = 0.94 mm. **Fig. 4.** Genital atrium showing uterine opening (UO) just beneath to cirrus opening (CO). Bar = 0.29 mm. **Fig. 5.** Transverse section of a mature proglottid, showing two cirrus pouches (CP) in a level. Testes (arrows) are divided into 3 groups by cirrus pouches. Vitellaria (arrow heads) are seen in cortical parenchyme. Bar = 0.29 mm. **Fig. 6.** Transverse (top) and sagittal (bottom) sections showing longitudinal (arrow) and circular muscle layers. Bar = 0.19 mm.

Table 1. Measurements of *Diplogonoporus balaenopterae* proglottids in comparison with previous reports.

	Present specimen	Hatsushika <i>et al.</i> (1970)	Hatsushika <i>et al.</i> (1969)	Maejima <i>et al.</i> (1969)
Proglottid				
length	0.65-1.01 mm	0.09-0.32 mm	0.45-1.30 mm	1.1-1.7 mm
width (A)	4.66-7.83 mm	0.75 mm	2.8-7.6 mm	3.4-12.0 mm
thickness	0.18-0.51 mm	0.8-1.0 mm	0.6-0.9 mm	0.12-0.35 mm
Inter-GO ^{a)}				
distance (B)	0.97-1.62 mm			
B/A	0.19			
Thickness of				
longitudinal m	44-80 μ m	60-90 μ m	20-120 μ m	16.2-41.2 μ m
transverse m	14-30 μ m	30-70 μ m	20-60 μ m	13.5-21.6 μ m
Testis				
diameter	20-36 μ m		27-81.6 μ m	41.2-62.1 μ m
No. in T/S ^{b)}	44-58		44-65	17-40
L/S ^{c)}	5-14		2-15	2-17
Egg				
length	57-80 μ m		57.2-73.4 μ m	59.4-81.0 μ m
width	34-45 μ m		41.9-48.6 μ m	35.1-51.3 μ m
operculum	29-32 μ m			
Remark	mature proglottids	immature proglottids	mature proglottids	mature proglottids

^{a)}GO, genital opening; ^{b)}T/S, transverse section; ^{c)}L/S, longitudinal section

longitudinal muscle layer (44-80 μ m) is thicker than the transvers muscle layer (14-30 μ m). The diameter of testes is 20-36 μ m. The number of testis is 44-58 in transverse section and 5-14 in longitudinal section. The size of eggs obtained from the uterus ruptured artificially ranged 34-45 \times 57-80 μ m with an operculum, 29-32 μ m at an end (Figs. 2 & 4, Table 1).

DISCUSSION

The present specimen was identified as *Diplogonoporus balaenopterae* by diffuse, follicular vitellaria distributed throughout the cortical layer of the parenchyma, two sets of reproductive organs in each mature proglottid, both genital pores situated on the same transverse plane in a proglottid, and the distance between 2 genital pores about one fifth of segmental width. *D. fukuokaensis*, reported by Kamo and Miyazaki (1970), can be easily ruled out by the difference in the remarkably closer distance of paired genital

openings (one-tenth to one-twentieth of segmental width) than *D. balaenopterae* or *D. grandis*. Besides the genus *Diplogonoporus*, some pseudophyllidean cestodes parasitizing mammals have two or more sets of reproductive organs in a mature proglottids. Tapeworms belonging to the genus *Baylisia* Markowski, 1952, a parasitic cestode of seals, are also provided with 2 sets of reproductive organs in a proglottid. But the genital pores are at different levels with each other in the case of *Baylisia*. Tapeworms of the genera *Tetragonoporus* Skrjabin, 1961, and *Polygonoporus* Skrjabin, 1967, have 4 or more sets of reproductive organs in a segment.

Some mature proglottids of *Diplogonoporus* are known to be provided with 3 or 4 sets of reproductive organs (Tsunoo *et al.*, 1935 ; Miura, 1937; Iwata, 1940). We failed to find proglottids with 3 or more sets of reproductive organs from the present specimen.

The cestodes belonging to the genus *Diplogonoporus* are regarded as a parasite of marine mammals. Human infections by *Diplogonoporus* spp. have been reported mainly

in Japan. A canine infection by *Diplogonoporus* spp. was also reported in Alaska (Rausch, 1964). Unlike anisakid larvae, the larvae of pseudophyllidean cestodes have seldom been studied in marine fish. Until now, the life cycle of *D. balaenopterae* remains uncertain. Kamo *et al.* (1973) reported that two species of marine copepods was experimentally infected by coracidia of *D. balaenopterae*. But there is no report on natural infection of marine copepods by *D. balaenopterae*. Some marine copepods have been regarded as the first intermediate host and the marine fish, second intermediate host.

There have been discrepancies among parasitologists in the taxonomic position or nomenclature of *Diplogonoporus* sp. recovered from human cases. However, in so-called balaenopterae-type, *D. grandis* and *D. balaenopterae*, there was no difference in morphological examinations (Iwata, 1940). Furthermore, Iwata (1967) stated that *D. balaenopterae* should be a correct name for the worms from both man and whale. Kamo *et al.* (1972, 1973) reported that no essential difference was noticed in the development of coracidia and proceroid larvae between *D. balaenopterae* obtained from a whale, *Balaenoptera acutorostrata* and *D. grandis* from a human infection. More recently, Deliamure and Skriabin (1986) also insisted that *D. balaenopterae* capable of infecting whales, dogs, and human beings can be considered as really existing. Nevertheless, some parasitologists, who reported human diplogonoporiasis, named their specimens *D. grandis* although they recognized the possibility of *D. grandis* as a synonym of *D. balaenopterae*. The authors suggest that the correct name, *D. balaenopterae*, alone should be used even in human diplogonoporiasis by balaenopterae-type. Balaenopterae-type worms have characteristics of possessing larger strobila, and broader and deeper bothria in comparison with so-called tetrapterus-type.

Several species of *Diplogonoporus* of tetrapterus-type have been reported from marine mammals. *D. tetrapterus* was recovered from the harbor seal, *Phoca vitulina* (Markowski, 1952); from the stellar sea lion, *Eumetopias jubata* (Margolis, 1956; Rausch,

1964); from the sea otter, *Enhydra lutris* (Rausch, 1964); from the fur seal, *Callorhinus ursinus* (Rausch, 1964); from the harp seal, *Pagophilus groenlandicus* and the hooded seal, *Cystophora cristata* (Deliamure, 1966). *D. variabilis* was reported from the bearded seal, *Erygnathus barbatus* (Krabbe, 1865). *D. fasciatus* was found from the ringed seal, *Pusa hispida* (Krabbe, 1865). *D. septentrionalis* was detected from a seal, *Phoca* sp. (Cholodkovsky, 1915). *D. mutabilis* was reported from the harbor seal (Belopol'skaia, 1960).

The standard of living, continuously increasing in Korea, allowed Koreans to consume more raw marine fish, which is relatively expensive compared with fresh-water fish. The increased consumption of marine fish would probably raise the opportunity of Koreans to be infected by cestodes transmitted by the fish. It is necessary to pay more attention to eating raw marine fish with regard to marine fish-borne cestodiasis. Efforts should be made to determine the first and second intermediate hosts in order to clarify the life cycle of *D. balaenopterae* and to prevent human infections.

ACKNOWLEDGEMENTS

The authors wish to thank Dr. N. Kagei, NIH, Japan, and Dr. J. Kim, Chonnam National University School of Medicine, for critical reading and helpful discussions on the present manuscript.

REFERENCES

- Belopol'skaia MM (1960) Gel'mintofauna larga (*Phoca vitulina largha* Pall.). *Vestn Leningr Univ Ser Biol* **15**: 113-121 (in Russian).
- Cho SY, Seo BS, Ahn JH (1971) One case report of *Diphyllobothrium latum* infection in Korea. *Seoul J Med* **12**: 157-163.
- Cholodkovsky N (1915) Cestodes nouveaux ou peu connus. *Annu Mus zool Acad Imp Sci St Petersb* **19**: 516-523 (in Russian).
- Deliamure SL (1966) Morfoloġo-anatomicheskoe issledovanie cestod' *Diplogonoporus tetrapterus* (Siebold, 1848), parazitiruiushchei u lastonogikh grenlandskogo moria. In Kraevaia parazitologiya i prirodnaia ochagovost' transmissivnykh boleznei Akad.

Nauk SSSR Kiev, 39-43 (in Russian).

Deliamure SL, Skrjabin AS (1986) Ob identifikatsii vidov *Diplogonoporus balaenopterae* i *D. grandis* (Cestoda, Diphylobothriidae). *Parazitologiiia* **20**: 69-72 (in Russian).

Iwata S (1940) *Diplogonoporus grandis* and whale tapeworm. *Osaka Iji Shinshi* **11**: 559-566 (in Japanese).

Iwata S (1967) *Diplogonoporus grandis* (Blanchard, 1894) in the synonym of *D. balaenopterae* Loennberg, 1892. *Dobutsu Bunruigakkai Shi* **3**: 20-24 (in Japanese).

Kamo H (1969) Studies on *Diplogonoporus grandis* (Blanchard, 1894). *Jpn J Parasitol* **18**: 333-337 (in Japanese).

Kamo H, Iwata S, Hatsushika R, Maejima J (1973) Experimental studies on the life cycle of *Diplogonoporus grandis* I. Embryonation and hatching of the eggs. *Jpn J Parasitol* **21**: 59-69 (in Japanese with English summary).

Kamo H, Iwata S, Hatsushika R, Maejima J (1973) Experimental studies on the life cycle of *Diplogonoporus grandis* II. Experimental infection of marine copepods with coracidia. *Jpn J Parasitol* **22**: 79-89 (in Japanese).

Kamo H, Miyazaki I (1970) *Diplogonoporus fukuokaensis* sp. nov. (Cestoda: Diphylobothriidae) from a girl in Japan. *Jpn J Parasitol* **19**: 625-644.

Krabbe H (1865) Helminthologiske Undersoegelser i Danmark og paa Island, med saerligt Hensyn til Blaereormlidelserne paa Island. *Kgl Danske Videnskab Selskab Skrifter naturvidenskab Math Afdel* **7**: 347-408 (in Russian).

Lee SH, Chai JY, Hong ST, Sohn WM, Choi DI (1988) A case of *Diphylobothrium yonagoense* infection. *Seoul J Med* **29**: 391-395.

Lee SH, Chai JY, Seo BS, Cho SY (1984) Two cases of human infection by adult of *Spirometra erinacei*. *Korean J Parasitol* **22**: 66-71.

Lee SH, Chai JY, Seo M, Kook J, Huh S, Ryang YS, Ahn YK (1994) Two rare cases of *Diphylobothrium latum* parvum type infection in Korea. *Korean J Parasitol* **32**: 117-120.

Margolis L (1956) Parasitic helminths and arthropods from pinnipedia of the Canadian Pacific coast. *J Fish Res Board Canad* **13**: 489-505.

Markowski S (1952) The cestodes of pinnipeds in the Arctic and other regions. *J Helminthol* **26**: 171-214.

Min DY (1990) Cestode infections in Korea. *Korean J Parasitol* **28**(S): 123-144.

Miura C (1937) Additional note on the morphology of *Diplogonoporus grandis*. *Nagasaki Igakkai Zasshi* **15**: 2379-2392 (in Japanese).

Rausch RL (1964) Studies on the helminth fauna of Alaska. XLI. Observations on cestodes of the genus *Diphylobothrium* Loennberg, 1892 (Diphylobothriidae). *Canad J Zool* **42**: 1049-1069.

Tsunoo S (1935) The second addition of the case of parasitism of *Diplogonoporus grandis*. *Nagasaki Igakkai Zasshi* **13**: 338-395 (in Japanese).

=초록=

고래복식문조충(*Diplogonoporus balaenopterae*)에 의한 인체감염 제1례

정동일¹⁾, 공현희¹⁾, 문주환¹⁾, 최동익¹⁾, 김태형²⁾, 이동욱²⁾, 박정자³⁾

경북대학교 의과대학 기생충학교실¹⁾, 마산 파티마병원 내과²⁾, 해부병리과³⁾

저자들은 1994년 5월 경남 마산시에 거주하는 41세 남자 환자에게서 자연배출된 의염 조충류의 총체 일부를 고래복식문조충(*Diplogonoporus balaenopterae*)으로 동정하였고 우리 나라의 인체 감염 제1례로 보고하는 바이다. 환자는 평소 각종 해산어류의 생식을 즐기고 담수어로는 잉어만을 생식한 경향이 있다. 검사실 소견상 경미한 호산구증다증(6%)과 혈청 IgE의 심한 증가(10.182 IU/ml), 초음파상에서 알콜성 지방간 외에는 특이한 소견을 발견할 수 없었다. Niclosamide 2 g을 경구투여하여 구충하였으나 두절을 발견하지 못하였다.

(기생충학잡지 33(3): 225-230, 1995년 6월)