

## *Diphyllobothrium latum* infection after eating domestic salmon flesh

Kyung Won LEE<sup>1)</sup>, Hyo-Chung SUHK<sup>1)</sup>, Ki-Soo PAI<sup>1)\*</sup>, Ho-Jun SHIN<sup>2)</sup>,  
Suk-Yul JUNG<sup>2)</sup>, Eun-Taek HAN<sup>3)</sup> and Jong-Yil CHAI<sup>3)</sup>

Departments of Pediatrics<sup>1)</sup> and Microbiology<sup>2)</sup>, Ajou University School of Medicine, Suwon 442-721, and  
Department of Parasitology<sup>3)</sup>, Seoul National University College of Medicine, Seoul 110-799, Korea

**Abstract:** *Diphyllobothrium latum* infection in human is not common in Korea and only thirty seven cases have been reported since 1921. We report two cases of fish tapeworm infection after ingestion of raw cherry salmon (*Oncorhynchus masou*) caught in the domestic river. Among four family members who ate together raw salmon flesh six months ago, just two, mother and daughter, were infected. It is our expectation that the salmon associated tapeworm infections would be enlisted as one of the major parasitic problems with the growing consumption of salmon in Korea.

**Key words:** *Diphyllobothrium latum*, *Oncorhynchus masou*, cherry salmon, fish tapeworm

The cestode infections occur not frequently, but often cause serious clinical problems. According to the annual reports of a medical institute located in Seoul, the egg positive rate of overall helminths and *Diphyllobothrium latum* was 6.5% and 0.004%, respectively (Lee et al., 1994). The second intermediate hosts were suggested as redlip mullets (*Liza haematocheila*), trouts, and certain marine fish in Korea (Joo et al., 1983; Lee et al., 1987; Lee et al., 1989; Lee et al., 1994; Sohn et al., 1996; Chung et al., 1997). We are adding two more human cases of fish tapeworm infection after ingestion of raw salmon flesh.

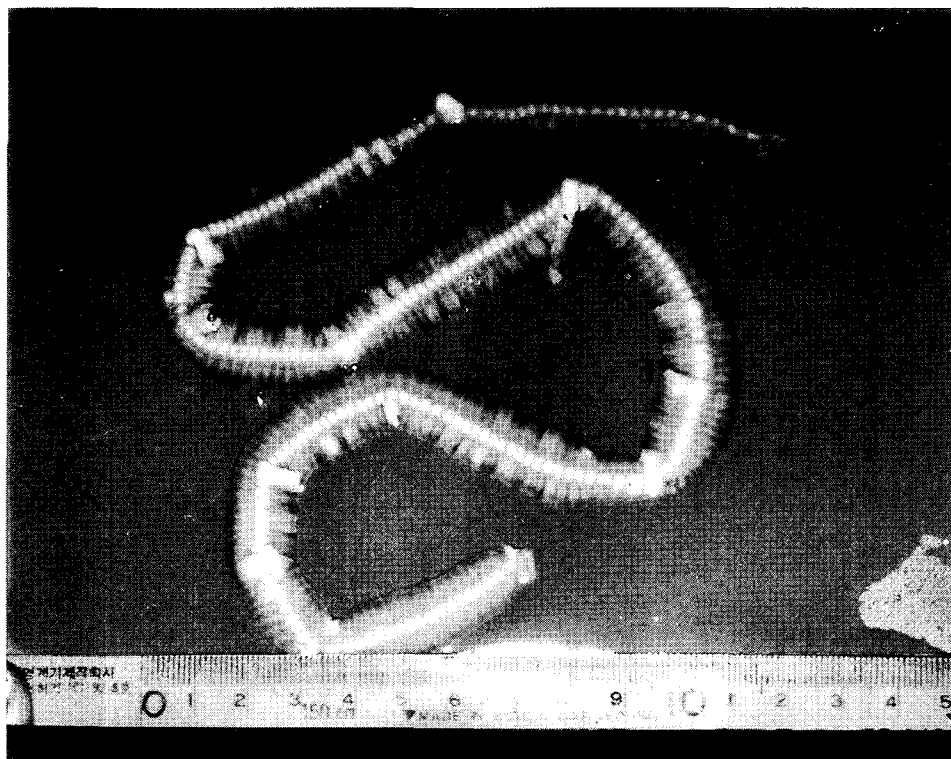
**Case 1:** A 7-year-old girl visited out-patient clinic on July 27, 2000, due to spontaneous discharge with the chain of segments which was 42 cm in length (Fig. 1). She had no history of eating raw fish except once when she ate raw salmon flesh all together with her

parent and sister in January, 2000, in Sockcho-shi, Kangwon-do, Korea. The salmon was caught from a river in the vicinity. She did not complained of any gastrointestinal discomfort. The serum chemistries were all in normal ranges and the hematologic examination revealed; hemoglobin 13.1 gm/dl, hemotocrit 37.5%, WBC 8,400/ $\mu$ l, platelet 3,400  $\times$  10<sup>3</sup>/dl, MCV 85.9 fl, MCH 29.9 pg, total eosinophil count 200/ $\mu$ l. The coprological study was positive for *D. latum* eggs (Fig. 2). The worm was identified as *D. latum*, based on the biological characters: external morphologies, coiling of uterus, number of uterine loops, position of genital opening, morphologies of cirrus, cirrus sac and seminal vesicle, position of vagina and uterine pore (Fig. 3). A single dose of praziquantel 400 mg was given but stool examination was still positive a week later. Another dose of 600 mg was given to and the young female patient was found to be free from the egg after one month.

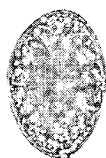**Case 2:** Two months after the young girl's visit, her mother discharged a similar tape worm segments as her daughter did. She was

• Received 20 August 2001, accepted after revision 9 November 2001.

\*Corresponding author (e-mail: kisoopai@madang.ajou.ac.kr)



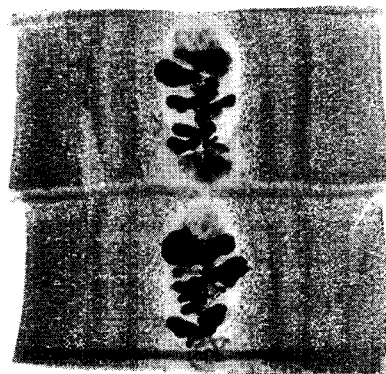
**Fig. 1.** A spontaneously discharged strobila of *Diphyllbothrium latum* from the Case 1.



**Fig. 2.** Eggs of *Diphyllbothrium latum* obtained from the feces of the Case 1 (x 400).

not able to visit our hospital because most Korean medical doctors were on strike against new medical care policy. She medicated herself with one tablet of praziquantel (600 mg) purchased from a drug store without doctor's prescription, even though it is illegal. She visited our clinic three months later on December 14, 2000. Every family member was included for the stool examination this time but the result was negative for diphyllbothriid eggs.

Several species have been found to infect humans and the main ones are *D. latum*, *D.*



**Fig. 3.** Morphologic characters of proglottids obtained from the strobila of *Diphyllbothrium latum*; proglottids of *Diphyllbothrium latum*; coiling of uterus, number of uterine loops, position of genital opening, morphologies of cirrus, cirrus sac and seminal vesicle, position of vagina and uterine pore.

*pacificum* and *D. nihonkaiense*. *D. latum* is known to distribute Siberia, north America and Japan. *D. pacificum* distributes in south

America and *D. nihonkaiense* in Japan. *D. latum* is the longest of the tapeworms that infect human, measuring 4 to 15 m in length and 10 to 20 mm in width. Other *Diphyllobothrium* species are smaller, rarely more than 1 m long. *D. latum* is creamy white in color and consists of 3,000 to 4,000 proglottids. The scolex is shaped like a spoon and has a pair of grooves, or bothria, in its anterior portion that serve as an organ of attachment. Comparing the difference of *D. latum* and *D. nihonkaiense*, the latter has slant penoscrotal and different DNA base sequence (AB015755D vs AF096240). *D. latum* is transmitted to humans through eating raw or uncooked fish (Salminen, 1970). Although many carriers are asymptomatic, clinical manifestations of diphyllbothriasis may include diarrhea, epigastric pain, nausea and vomiting.

We have two types of salmon, *Oncorhynchus keta* and *O. masou*. There is no epidemiological study for *D. latum* infection in the second intermediate hosts in Korea. The infection rate in Korea is assumed to be close to that of Japan because the two countries are sharing the same seas and the same second intermediate hosts. A Japanese report from 1977 to 1982 showed 15.9% to 48.4% infection (Oshima and Wakai, 1983) in the cherry salmon (*Oncorhynchus masou*). At circumpolar north region, *D. latum* was rarely found in salmonids but in pikes and perch (Curtis and Bylund, 1991).

In Korea, the artificial hatchery and stocking human-bred salmon were started in 1913 at Kowon, Hamgyongnam-do. In 1967, an institute for the cold water fish was established in Kangwon-do. The returning rate of the salmon was 0.3% at first, but now it has increased up to 1.5%. The number of stocks and the recovery units were 8,000 and 410 in 1970 and 1.45 million and 27,000 in 1998, respectively. The amount of salmon catch was 553 tons in 1997 and is still increasing through the expanded stocking.

Therefore, it is our expectation that the infection rate of *D. latum* in humans would be increasing in near future with the exploding consumption of salmon in Korea. For the successful control of this parasite,

epidemiological studies of *D. latum* infection should be carried out followed by thorough investigations to find out relevant ways to prevent the further spread of this infection.

#### REFERENCES

- Chung PR, Sohn WM, Jung Y, Pai SH, Nam MS (1997) Five human cases of *Diphyllobothrium latum* infection through eating raw flesh of redlip mullet, *Liza haematocheila*. *Korean J Parasitol* **35**: 283-289.
- Joo KH, Eom KS, Chung MS, Yeo HW, Lee JS, Rim HJ (1983) Case report: 7 cases of *Diphyllobothrium latum* infection. *Korean J Parasitol* **21**: 307 (in Korean).
- Lee SH, Chai JY, Hong ST, et al. (1989) Seven cases of *Diphyllobothrium latum* infection. *Korean J Parasitol* **27**: 213-216.
- Lee SH, Chai JY, Seo M, et al. (1994) Two rare cases of *Diphyllobothrium latum* parvum type infection in Korea. *Korean J Parasitol* **32**: 117-120.
- Lee SK, Chung NS, Paik IK, Ko IH (1987) Two cases of *Diphyllobothrium latum* infection and analysis of diphyllbothriasis in Korea. *Korean J Med Technol* **19**: 239-246 (in Korean).
- Lee SK, Shin BM, Chung NS, Chai JY, Lee SH (1994) Second report on intestinal parasites among the patients of Seoul Paik Hospital (1984-1992). *Korean J Parasitol* **32**: 27-33.
- Min DY (1990) Cestode infections in Korea. *Korean J Parasitol* **28** (Suppl): 123-144.
- Oshima T, Wakai R (1983) Epidemiology of *Diphyllobothrium latum* infection in Japan, with special reference to infection of cherry salmon. *Jpn J Antibiot* **36**: 566-572 (in Japanese).
- Salminen K (1970) The effect of household smoking on the infectiveness of *Diphyllobothrium latum* from fish to man. *Acta Vet Scand* **11**: 228-35.
- Sohn WM, Chai JY, Lee SH (1996) Epidemiologic studies on diphyllbothriid tapeworms in Korea. *Proceed 2nd Japan-Korea Parasitologists' Seminar (Forum Cheju-2)*: 66-73.
- Tanowitz HB, Weiss LM, Wittner M (2001) Tapeworms. *Curr Infect Dis Rep* **3**: 77-84.

**IN MEMORIAM**  
**PROFESSOR DU-HWAN JANG**

(1928-2001)



Professor Du-Hwan Jang passed away on August 16, 2001, over 5 months after his 73rd birthday. He was born on March 27, 1928 in Onyang-gun and spent his childhood in Yesan-gun, Chungcheongnam-do. Prof. Jang graduated from the College of Veterinary Medicine at Seoul National University in 1956. His career in the field of Parasitology began in 1956 as a graduate student. He received master degree from the University of Minnesota in 1961 and doctorate (PhD) by "Studies on *Eurytrema pancreaticum*" from the Seoul National University in 1971. He had kept his position of professor at the Department of Parasitology, College of Veterinary Medicine, Seoul National University from 1961 to retirement in 1993.

Professor Jang's research interest dealt with various fields of Veterinary Parasitology, but especially focused on avian coccidiosis. In recognition of his efforts and studies, he received the Academic Award from the Korean Society for Parasitology (KSP) in 1972. He was elected as the Vice President of the KSP from 1982 to 1983 and became an Emeritus Member since 1993.

His memory leaves those who knew him with a sense of affection and great admiration. He will not be forgotten for his mentorship and achievements by those, both young and old, who follow him in the challenges of Veterinary Parasitology academia in Korea. May he rest in peace and never be forgotten.