

A case of breast sparganosis

Seobo SIM¹⁾, Jai-Kyung YOU²⁾, In-Yong LEE¹⁾, Kyung-Il IM¹⁾ and Tai-Soon YONG^{1)*}

¹⁾Department of Parasitology and Institute of Tropical Medicine, Yonsei University College of Medicine, Seoul 120-752, ²⁾Department of Radiology, Inje University College of Medicine, Busan 614-135, Korea

Abstract: A 29-year-old Korean woman visited the Department of Surgery in MizMedi Hospital with a palpable itching mass on the right breast that had existed for the past 7 months. She had no history to eat either frogs or snakes, but had the history of drinking impure water. Sonography revealed a serpiginous hypoechoic tubular structure associated with partial fat necrosis in breast parenchymal layer and subcutaneous fat layer. It also revealed oval cystic lesions. At operation, an ivory white opaque ribbon-like worm that measured 16.5 cm in length and 0.5 cm in width was extracted. Anti-sparganum specific serum IgG level in the patient's serum (absorbance = 0.71), measured by ELISA, was found to be significantly higher than those of normal controls (cut off point = 0.21). Sonography and ELISA appear to be helpful to diagnose sparganosis. Breast sparganosis is rarely found throughout the world.

Key words: sparganosis, breast, ultrasonography

Sparganosis is an infection caused by sparganum, a plerocercoid larva of a cestode, belonging to the genus *Spirometra*. Sparganosis is a worldwide disease, but the major endemic areas are China, Japan, Taiwan, Korea, Vietnam, Thailand, and other Southeast Asian countries (Sun, 1999). The final host are cats and dogs. The first intermediate host is a crustacean or copepod of the genus *Cyclops*, when the second intermediate hosts such as frogs, snakes, birds or small rodents eat an infected *Cyclops*, the larva penetrates the intestinal wall and migrates into various organs and tissues, where it develops into the plerocercoid larva (Moreira et al., 1997). The most important route of infection in Korea is through eating raw snakes, followed by

drinking contaminated water with infected *Cyclops* and by eating raw frogs or other kinds of raw flesh (Min, 1990). Sparganum was commonly found in the abdomen (28.1%), urogenital organs (22.2%), extremities (17.8%), central nervous system (11.9%), chest (10.4%), orbital region (8.1%), neck and oral cavity (1.5%) in descending order (Min, 1990). Breast is a rare site of infection.

A 29-year-old Korean woman visited the Department of Surgery in MizMedi Hospital with a palpable itching mass on the right breast that had existed for the past 7 months. On physical examination, a lump with mild tenderness was palpated at the lower outer quadrant of the right breast. She had no history to eat either frogs or snakes, but had the history of drinking impure water. Sonography revealed a serpiginous hypoechoic tubular structure associated with partial fat necrosis in breast parenchymal layer and subcutaneous fat layer (Fig. 1A). It also

• Received 21 October 2002, accepted after revision 27 November 2002.

*Corresponding author (e-mail: tsyong212@yumc.yonsei.ac.kr)

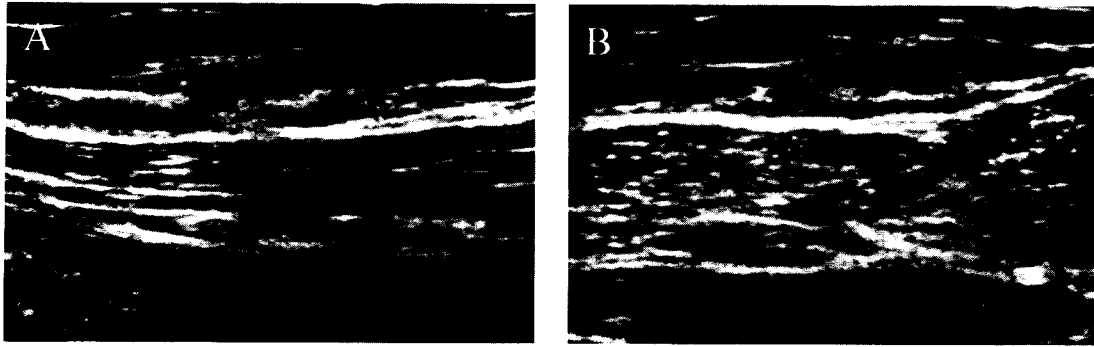


Fig. 1. Breast sparganosis. Sonography shows a serpiginous hypoechoic tubular structure (A) and oval cystic lesions (B).

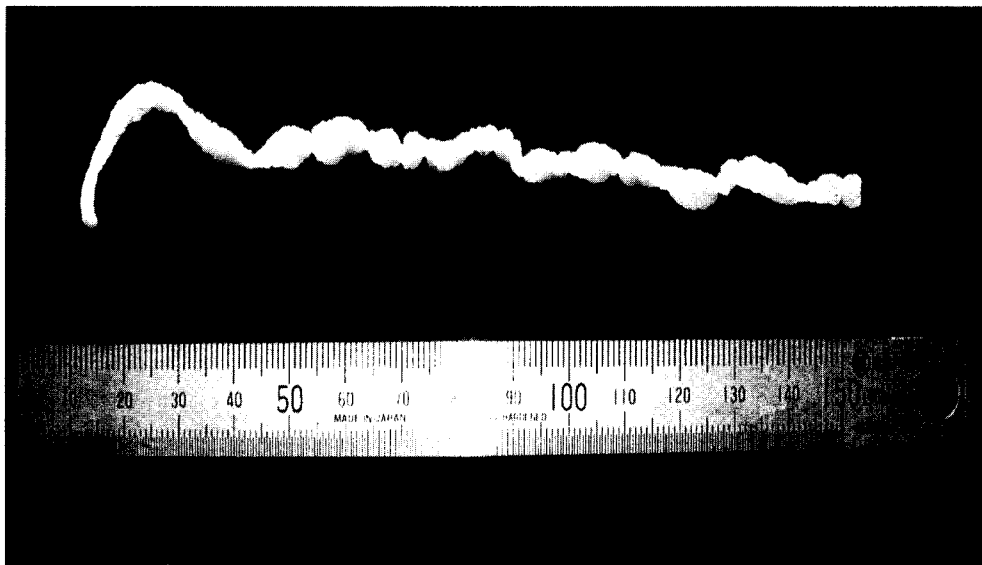


Fig. 2. Sparganum extracted from the lesion of the patient's breast.

revealed oval cystic lesions (Fig. 1B). At operation, an ivory white opaque ribbon-like worm that measured 16.5 cm in length and 0.5 cm in width was extracted (Fig. 2).

The patient's serum was examined for the level of anti-sparganum IgG antibody by micro-ELISA. Antigen was prepared from the spargana collected from naturally infected snakes (*Rhabdophis tigrinus tigrinus*). Human sera were diluted to 1:400, and alkaline phosphatase conjugated goat anti-human IgG (Fab specific; Sigma, USA) was diluted to 1:5,000. The optical density was read at 405

nm. Anti-sparganum specific serum IgG level in the patient's serum (absorbance = 0.71), measured by ELISA, was found to be significantly higher than those of normal controls (cut off point = 0.21). No cross-reaction to other helminthes, such as cysticercus of *Taenia solium*, *Clonorchis sinensis* and *Paragonimus westermani*, was found (Table 1).

The hypoechoic tubular structure revealed by sonography was regarded as a remnant formed by an active moving of sparganum (Hong et al., 1989; Chung et al., 1995). The tubular structure appeared to have just undergone the

Table 1. IgG antibody levels of the patient's serum and normal human sera against the extract of four different antigens, measured by ELISA

Antigens	Optical density	
	Patient's serum	Cut off point
Sparganum	0.71	0.21
Cysticercus	0.18	0.25
<i>Paragonimus westermani</i>	0.12	0.20
<i>Clonorchis sinensis</i>	0.11	0.24

process of active healing after the worms pass through (Hong et al., 1989).

When located in the breast, sparganosis has generally been diagnosed as mastitis or cancer (Moreira et al., 1997). Therefore, sonography and ELISA appear to be very helpful to diagnose sparganosis. In fact, breast sparganosis is rarely found throughout the world.

REFERENCES

Chung SY, Park KS, Lee Y, Park CK (1995) Breast sparganosis: mammographic and ultrasound

features. *J Clin Ultrasound* **23**: 447-451.
 Hong ST, Kim KJ, Huh S, et al. (1989) The changes of histopathology and serum anti-sparganum IgG in experimental sparganosis of mice. *Korean J Parasitol* **27**: 261-269.
 Min DY (1990) Cestode infection in Korea. *Korean J Parasitol* **28**(suppl): 123-144.
 Moreira MA, de Freitas Junior R, Gerais BB (1997) Granulomatous mastitis caused by sparganum. A case report. *Acta Cytol* **41**: 859-862.
 Sun T (1999) Parasitic Disorders: pathology, diagnosis, and management. 2nd ed. p393-398 Williams & Wilkin, Pennsylvania.