

Chronic Lymphocytic Leukemia in a Dog

Seung-Woo Jung, Eul Soo Choi, Jong-Bok Lee, Cheol-Young Hwang, Hwa-young Youn¹,
Chang-Woo Lee and Hong-Ryul Han

Department of Internal Medicine, Veterinary Medical Teaching Hospital, College of Veterinary Medicine and School of Agricultural Biotechnology, Seoul National University, Seoul 151-742, Korea

Abstract : Chronic lymphocytic leukemia is a general disease that evolves over a longer duration and is characterized by more mature and well-differentiated lymphocytes in blood and bone marrow than those seen in acute leukemia. This report presents a 2-year-old mix neutered male dog with seizure, ascites, and transmissible venereal tumor. Diagnostic works-up concluded chronic lymphocytic leukemia. Chemotherapy composed of chlorambucil and prednisolone has been applied to the patient until now. Remission of almost manifestations was achieved, and the quality of life improved.

Key words : dog, chronic lymphocytic leukemia, chlorambucil, prednisolone

Introduction

Leukemia is a malignant neoplasm that originates from hematopoietic precursor cells in the bone marrow. Hematopoietic precursor cells are unable to undergo terminal differentiation, thus they self-replicate as a clone of usually immature cells⁹. Chronic leukemia has a protracted, often indolent course, and the prominent cell is mature lymphocyte which is observed on blood smear in dogs with nonspecific signs of illness⁵. In dog, leukemia constitutes less than 10% of all hemolymphatic neoplasms and is considered rare. Although most leukemia in dogs is considered spontaneous, radiation and viral particles have been identified as possible etiologic factors with this disease⁹. Chronic lymphocytic leukemia (CLL) can be confirmed with a history, clinical signs, radiography, blood analysis, urinalysis, cytology, bone marrow analysis, serum protein electrophoresis, histopathology, and chemotherapeutic response. Unlike acute lymphoblastic leukemia (ALL), CLL is usually responsive to chemotherapy in the early stage. Approximately 75% of animals will respond and enjoy a normal quality of life, with a median survival of approximately one year. Although the prognosis is good in the short term, eventually CLL becomes resistant to therapy or progresses to ALL¹⁰. At the result, lymphoblasts replace mature lymphocytes as the abnormally proliferating population, and survival is short¹⁰. This report describes a successful treatment for a dog presented with systemic manifestations induced by chronic lymphocytic leukemia.

Case

On August 2001, a 2-year-old mix neutered male dog was presented to Veterinary Medical Teaching Hospital of Seoul

National University. This patient had a history of anorexia, bone pain, seizure and twice operations due to transmissible venereal tumor. Physical examination revealed normal TPR, severe abdominal distension, respiratory distress, corneal scar, and episcleritis. On auscultation, there were muffled lung and heart sound without heart murmur. Initial complete blood count & serum-chemistry were performed and the data are shown in Table 1 and 2. Thoracic radiograph revealed decreased tracheospinal angle, increased apicobasal axis with normal heart shape, increased diameter of the caudal vena cava, interlobar fissure and pulmonary interstitial pattern especially on the right caudal lung lobe. Incidentally radiopaque materials between T 7-8, T 9-10, and T 11-12 intervertebral disc spaces were also found. On abdominal radiograph, shown were loss of abdominal detail, abdominal distension, floating intestinal bowel loops, and hepatomegaly protruding the rib cage. But, there was no mass region. On ultrasonography, pleural effusion in lung field, cellular ascites in overall abdomen, hepatosplenomegaly, hepatic venous congestion, sludges in gallbladder, and swelling of mesenteric lymph node were revealed, still the structure and function of heart and kidney were normal. Abdominal fluid was obtained from the abdominocentesis. The result was considered as simple transudate based on the fact of low protein and cellularity, and there were no abnormal cells and little sediments.

Table 1-1. Complete Blood Count

WBC	differential count		
	Lymph	Seg	Eosin
220500/ μ l	82%	17%	1%

Table 1-2. Complete Blood Count

RBC	PCV	Hb	MCV	Platelet
271* 10^4 / μ l	22%	8.6	80	120,000/ μ l

¹Corresponding author.

E-mail : hyyoung@snu.ac.kr

Table 2. Serum-chemistry profiles

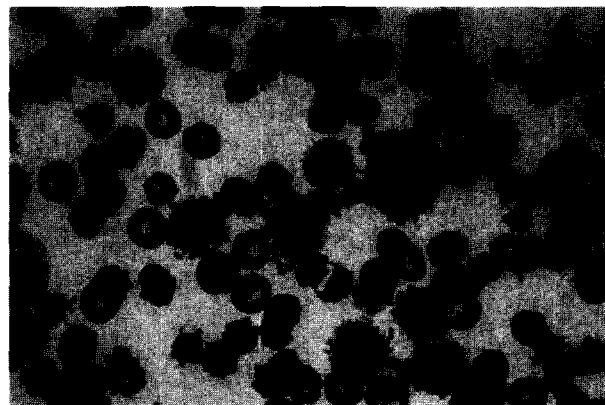
ALT	20 U/L
AST	44 U/L
ALP	517 U/L
γ -GT	20 U/L
BUN	20 mg/dl
Creatinine	0.5 mg/dl
Glucose	99 mg/dl
Total bili	0.3 mg/dl
Total chole	218 mg/dl
Total protein	4.0 g/dl
Albumin	1.0 g/dl
CK	186 U/L
Na	149 mmol/L
K	5.0 mmol/L
Cl	121 mmol/L
Ca	5.9 mg/dl
P	3.6 mg/dl

Table 3. Urinalysis

USG	1.013
RBC	++
Hb	++
protein	++
pH	6
cast	granular
crystal	-
bacteria	-
protein	1.1 g/dl
creatinine	94 mg/dl

Urine Dip-stick[®] and sediment analysis were performed for urinalysis, which data is shown in Table 3. Initial momentary evaluation for urinary protein loss was examined from the ratio of urine total protein to creatinine ratio, which was 11.7. Hematologically neoplastic cells related to CLL were identified with high numbers in the peripheral blood, and assumed an aspect of mature and well-differentiated small lymphocytes which had typical features of clumped chromatin pattern, similar size to RBC, and nucleoli. And they are shown to be various in size, and had especially dark-stained cytoplasm and a few cytoplasmic vacuoles (Fig 1). No lymphoblast cells were identified. There were no autoagglutination and spherocytosis which might be possible events as the result of the secondary immune-mediated hemolytic anemia seen in the CLL patient. From the above diagnostic procedures that include the patient history, clinical signs, radiography, blood analysis, urinalysis, and hematology, this patient could be diagnosed as chronic lymphocytic leukemia (CLL).

Therapeutic mainstay of chronic lymphocytic leukemia is

**Fig 1.** Blood smear film shows malignant and well-differentiated lymphocytes. (modified Diff-Quick, $\times 1000$)

the chemotherapy. But, because of poor condition of this patient, initial approach was targeted onto the supportive care. Blood transfusion for anemia, ultrasound-guided abdominocentesis and colloid fluid infusion for effusion, peripheral parenteral nutrition for anorexia, antibiotics for bacterial prophylaxis and compromised immune status, calcium gluconate injection for hypocalcemia were performed. Chemotherapeutic agents and glucocorticoids are noted for their benefit in control of systemic consequences of chronic lymphocytic leukemia. Chemotherapeutic strategies were discussed with the client. Chlorambucil (Leukeran[®] produced by GlaxoWellcome Greenford Middlesex UK, 0.2 mg/kg PO for 14 days, then 0.1 mg/kg PO continuously) and prednisolone (30 mg/m² PO, SID for 7 days, next 20 mg/m² PO, SID for 7 days, finally 10 mg/m² PO, QOD) were selected for efficacy and minimization of expenses. Successive re-examination has been performed since the initial treatments. Significant hematologic and serum-chemical improvements with resolved manifestations were noted for 3 weeks after initial presentation. (e.g. normal WBC level and normal differential count, increased albumin level, decreased effusion, good appetite) However, total WBC level was increased and especially lymphocytosis occurred thereafter. As the albumin level decreased, ascites and pleural effusion were produced again. Besides, in the middle of the chemotherapy, severe respiratory problems and oculonasal discharge were manifested. These problems were due to canine distemper virus infection which was confirmed by RT-PCR. And immune-mediated hemolytic anemia secondary to CDV progressed to severe anemic condition in hematology. Therefore, more aggressive reintensification strategy such as CHOP protocol which includes cyclophosphamide 50 mg/m² PO QOD, doxorubicin 30 mg/m² IV day 1, vincristine 0.7 mg/m² IV day 8, 15, PDS 20 mg/m² SID for 7 days then, QOD for 14 days was needed. At the end of one cycle of CHOP protocol, total WBC level and differential count was stabilized into normal level, and the

albumin level was increased up to 1.74. After almost conditions are in the remission status, reintensification protocol was switched to maintenance one which was adjusted to chlorambucil 0.1 mg/kg SID, prednisolone 25 mg/m² SID.

Discussion

Chronic lymphocytic leukemia is more common in dogs over 6 years of age than chronic myeloid leukemia (CML)⁵. CLL is characterized by the proliferation of phenotypically mature lymphocytes rather than lymphoblasts. Clinical presentations are nonspecific and can induce lethargy, organomegaly, pyrexia, polyuria, polydipsia, hemorrhage (from thrombocytopenia), lameness, and collapse. The majority of dogs present with mild to moderate lymphadenopathy, splenomegaly, and pale mucous membrane¹⁰. Infiltration of neoplastic lymphoid cells in bone marrow is the hallmark of CLL, and a careful examination of peripheral blood and marrow is essential in establishing a diagnosis of CLL. But, absolute malignant lymphocytosis is the major diagnostic criterion for CLL in dogs. A separate clinical staging system has not been developed for canine lymphocytic leukemia⁷. The reason of hypoalbuminemia which led to ascite and pleural effusion was regarded as the urinary protein loss. A urine protein/creatinine ratio less than 1.0 is considered normal in dog. Significant proteinuria is usually associated with a urine protein/creatinine ratio of greater than 3.0. The ratio of this patient was 11.7, which strongly suspected a glomerular disease. But, this measurement was momentary, not from 24-hour urine collection and urine protein/creatinine ratio cannot be used to distinguish pathologic renal proteinuria from post-renal proteinuria caused by infection or hemorrhage^{1,6}. The renal biopsy not only confirms the diagnosis but also aids in prognostication about glomerular disease². Recognition of the cell line from which the leukemic cells originated is often difficult only by evaluating routinely stained peripheral blood films. Examination of marrow aspirates may be important for confirmation and prognostication of leukemia. However, because leukemic cells within the bone marrow are typically more immature than those in the peripheral blood, the procedure may not aid in specifically identifying the neoplastic cell type unless special cytochemical and immunocytochemical staining are employed⁸. A few of the more common leukemia in dogs and cats may be suggested by combination of leukemic cell morphology, patient history, and associated hematologic abnormalities. In this case, patient status was too severe to proceed bone marrow examination. So, bone marrow analysis was not tried. Because of the indolent nature of CLL in many animals, it is controversial whether or not all dogs with CLL should be treated^{3,4}. However, if the animal is anemic or thrombocytopenic, or has an excessive high WBC count,

therapy should be instituted. The most effective drug evaluated thus far is chlorambucil⁵. But, in this patient the response was tapered by degrees, and drug resistancy occurred. So, the protocol was changed into more potent and effective one such as CHOP, which is known as the standard of therapy in malignant lymphosarcoma. So, we can say that this is a significant attempt in canine leukemic patient. In the case of myelosuppression induce by chemotherapy, dosage should be altered depending on neutrophil and platelet counts. Actually when neutropenia (<2500/ μ l) or thrombocytopenia (<50,000/ μ l) occurred to this patient, chemotherapy stopped and was postponed until recovery over the normal condition. CLL is a slowly progressive disease, and the median survival time is approximately 12 months⁵. Although the prognosis is good in the short term, eventually CLL becomes resistant to therapy or can progress to ALL¹⁰. Response and disease progression should be followed up with periodic hematologic examination. Since switching to maintenance protocol, total WBC level and its differential count have been nearly normalized with the remission of almost all the manifestations.

References

1. Bagley RS, et al. The effect of experimental cystitis and iatrogenic blood contamination on the urine protein/creatinine ratio in the dog. *J Vet Intern Med* 1991; 5: 66-71.
2. Baqi N, et al. Lupus nephritis in children. A longitudinal study of prognostic factors and therapy. *J Am Soc Nephrol* 1996; 6: 924-929.
3. Harvey JW, Terrell TG, Hyde DM, et al. Well-differentiated lymphocytic leukemia in a dog: Long-term survival without therapy. *Vet Pathol* 1981; 18: 37-47.
4. Hodkins EM, Zinkl JG, Madewell BR. Chronic lymphocytic leukemia in the dog. *J Am Vet Med Assoc* 1980; 117: 704-707.
5. Leifer CE, Mtus RE. chronic lymphocytic leukemia in the dog: 22 cases (1974-1984). *J Am Vet Med Assoc* 1986; 189-214.
6. Myers NC, et al. The influence of naturally occurring urinary tract infections on the urine protein/creatinine ratio in dogs. *J Vet Intern Med* 1993; 7: 126-131.
7. Rai KR, Sawitsky A, Cronkite EP, et al. Clinical staging of chronic lymphocytic leukemia. *Blood* 1975; 46: 219-234.
8. Raskin RE, Nipper MN. Cytochemical staining characteristics of lymph nodes from normal and lymphoma-affected dogs. *Vet Clin Pathol* 1992; 21: 62-67.
9. Richard W. Nelson, C. Guillermo Couto. Leukemias. In: *Small Animal Internal Medicine*, 2nd ed. St. Louis: Mosby. 1998: 1138-1140
10. Stephen J. Ettinger, Edward C. Feldman. Hematopoietic tumors. In: *Textbook of Veterinary Internal Medicine*, 5th ed. Philadelphia: Saunders. 2000: 514-515

개에서의 만성 림프구성 백혈병

정승우 · 최을수 · 이종복 · 황철용 · 윤화영¹ · 이창우 · 한홍률

서울대학교 수의과대학 수의내과학교실

요 약 : 만성 림프구성 백혈병은 오랜기간에 걸쳐서 발전하는 전신질환이며, 급성 백혈병에서 보이는 것보다 더욱 성숙되고 잘 분화된 림프구가 혈액과 골수에 존재하는 것을 특징으로 한다. 본 증례보고에서는 발작, 복수의 임상 증상과 전염성 성병성 종양에 대한 치료경력이 있는 2년령의 거세된 잡종견을 다루고 있다. 여러 가지 진단 절차를 통하여 만성 림프구성 백혈병으로 진단내렸고, chlorambucil 과 prednisolone을 이용한 항암치료를 현재까지 적용해 오고 있다. 초기내원 시 보였던 대부분의 증상에 대한 개선을 볼 수 있었으며, 환자의 삶의 질은 향상되었다.

주요어 : 개, 만성 림프구성 백혈병, chlorambucil, prednisolone