

설하갑상선과 수유중 유방이 Tc-99m Pertechnetate 스캔에 동시에 관찰된 증례

경북대학교 의과대학 핵의학교실
서지형 · 성영옥 · 배진호 · 정신영 · 안병철 · 이재태 · 이규보

Simultaneous Visualization of the Sublingual Thyroid and Lactating Breasts with Tc-99m Pertechnetate Scintigraphy

Ji Hyoung Seo, M.D., Young Ok Seong, M.D., Jin Ho Bae, M.D., Shin Young Jeong, M.D., Byeong-Cheol Ahn, M.D., Jaetae Lee, M.D., Kyu Bo Lee, M.D.

Department of nuclear medicine, Kyungpook National University Hospital, Kyungpook National University Medical School, Daegu, Korea

Purpose: The thyroglossal duct runs from the base of the tongue to the thyroid. Rarely the thyroid completely fails to migrate and results in ectopic thyroid tissue, which can be demonstrated scintigraphically. A 31-year old female patient was referred for thyroid scintigraphy due to protruding mass at the base of the tongue. She was mildly hypothyroid. Tc-99m pertechnetate thyroid scan was performed to rule out ectopic thyroid gland. There showed a focal area of intense tracer uptake in sublingual area, suggesting the sublingual thyroid. In addition there noted diffusely increased tracer uptake in both breasts. The patient delivered a baby 6 months prior to the scan and was on breast-feeding. Free Tc-99m pertechnetate physiologically secretes into the salivary glands, the stomach, the gastrointestinal tract, the genitourinary tract and the mammary glands and sodium-iodide symporter plays a role in the accumulation of free Tc-99m pertechnetate. We report simultaneous visualization of lactating breasts and ectopic thyroid gland in the base of the tongue. (Korean J Nucl Med 39(6):489-490, 2005)

Key Words: Sublingual thyroid, Lactating breasts, Tc-99m pertechnetate thyroid scintigraphy

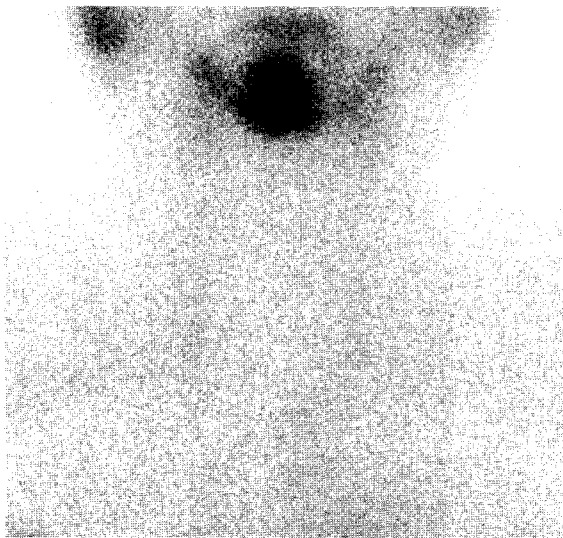

Fig. 1. A 31-year old woman was referred for thyroid scintigraphy to evaluate the protruding mass in tongue base. Tc-99m pertechnetate thyroid scan revealed focal intense tracer uptake in sublingual area, and no visible tracer uptake in thyroid bed, which is suggestive of the presence of ectopic lingual thyroid.

- Received: 2005. 11. 20. • Accepted: 2005. 12. 5.
- Address for reprints: Jaetae Lee, M.D., Department of Nuclear Medicine, Kyungpook National University Hospital, #50, Samduck 2-ga, Jung-gu, Daegu 700-721, Korea
Tel: 82-53-420-5586. Fax: 82-53-422-0864
E-mail: jaetae@knu.ac.kr

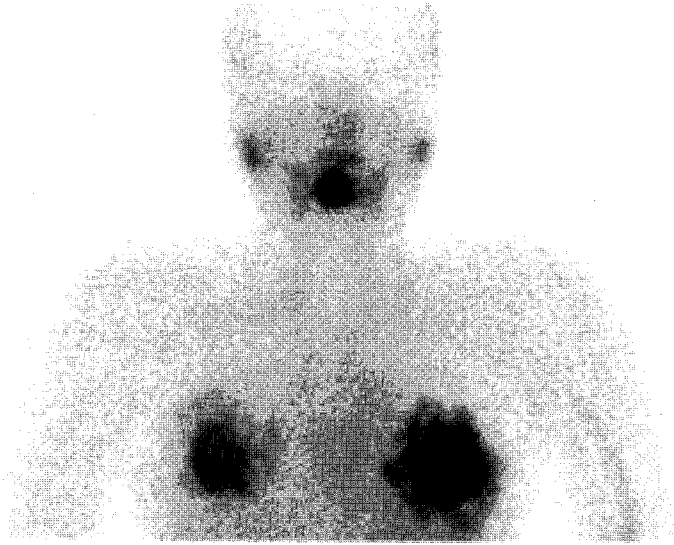


Fig. 2. The planar image of the head and the chest revealed diffuse tracer uptake in both breasts in addition to ectopic thyroid tissue. She had delivered a baby 6 months prior to visiting hospital and was on breast-feeding.

References

1. Ell PL, Gambhir SS. Nuclear medicine in clinical diagnosis and treatment. 3rd ed. Edinburgh: Churchill Livingstone: 2004.
2. Thrall JH, Ziessman HA. Nuclear Medicine The Requisites 2nd ed. Mosby: 2001.
3. Spieth ME, Veluvolu P, Schimitz SL. SPECT and planar imaging of a lingual thyroid gland. *Clin Nucl Med* 2003;28:140-1.
4. Aktolun C, Demir H, Berk F, Metin Kir K. Diagnosis of complete ectopic lingual thyroid with Tc-99m pertechnetate scintigraphy. *Clin Nucl Med* 2001;26:933-5.