

# A Case of Thoracic Vertebral Chondroblastoma, Treated with 3-D Image Guided Resection and Reconstruction

Yoon Ho Lee, M.D., Dong Ah Shin, M.D.,  
Keung Nyun Kim, M.D., Do Heum Yoon, M.D.

Department of Neurosurgery, Yonsei University College of Medicine, Seoul, Korea

We present a case of chondroblastoma in the thoracic vertebra. A 40-year-old patient with upper back pain and lower extremity weakness was admitted to our clinic. On neurological examination, the patient exhibited lower extremity spastic paraparesis. Magnetic resonance imaging revealed a mass infiltrating the 7th thoracic vertebra and its adjacent structures with concomitant compression of the epidural space. After right upper lung tuberculoma was resected through the transthoracic approach, T7 total corpectomy was done with anterior stabilization using a MESH cage and T7 rib bone graft. Two weeks after the first operation, remained part of vertebra was removed and posterior stabilization was performed using a pedicle screw fixation and cross linkage bar with the assistance of the navigation system. The final pathologic diagnosis of the vertebral lesion was benign chondroblastoma.

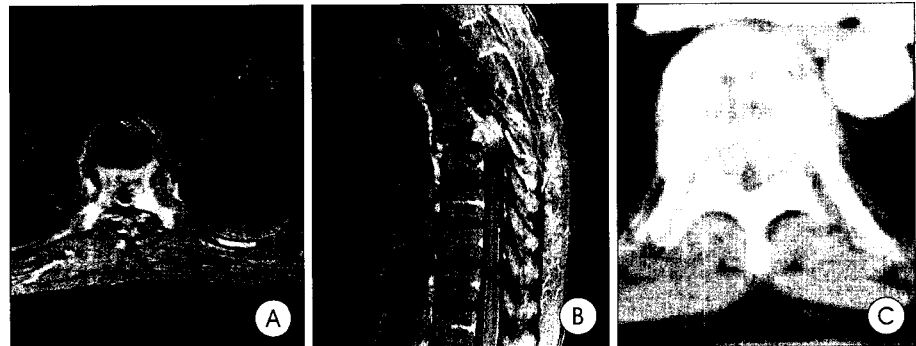**KEY WORDS :** Chondroblastoma · Thoracic vertebra · Spine tumor.

## Introduction

Chondroblastoma is a benign bone tumor arising most often in the epiphysis of long bones. The vertebra is a rare primary site of origin for chondroblastomas. We report a 40-year-old woman with chondroblastoma of the 7th thoracic vertebral body and the adjacent structures. In addition, the use of an intraoperative computer guidance system for a technically demanding spinal tumor resection and reconstruction is discussed.

## Case Report

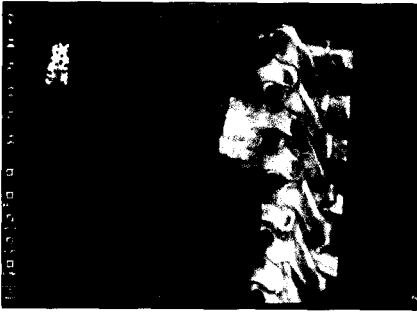
A 40-year-old patient with upper back pain and lower extremity weakness was admitted to our clinic. On examination, the patient exhibited lower extremity spastic



**Fig. 1.** Preoperative T1-weighted enhanced axial(A) and sagittal(B) magnetic resonance images and computed tomography(C) scan demonstrating tumor involvement of the T7 vertebra with spinal cord compression.

paraparesis(grade 4/5) and sensory changes below T9. Deep tendon reflexes were increased. Magnetic resonance imaging revealed a mass infiltrating the 7th thoracic vertebra and adjacent structures with concomitant compression of the epidural space(Fig. 1). Initially, we were highly suspicious of a metastatic spinal body tumor at T7. On the chest CT scan done searching for a possible primary focus in lung, a nodular density was revealed on the right upper lung field. A thoracotomy was performed through the transthoracic approach and a right upper lobe wedge resection was successfully achieved. In addition, a T7 total corpectomy was completed with anterior stabilization using a MESH cage (DePuy Acromed, Raynham, MA, U.S.A) and T7 rib bone graft. On the pathological examination, histological features

- Received : May 10, 2004 • Accepted : October 5, 2004
- Address for reprints : Do Heum Yoon, M.D., Department of Neurosurgery, Yonsei University College of Medicine, 134 Shinchon-dong, Seodaemun-gu, Seoul 120-749, Korea  
Tel : 02) 361-5620, Fax : 02) 393-9979  
E-mail : ydoheum@yumc.yonsei.ac.kr

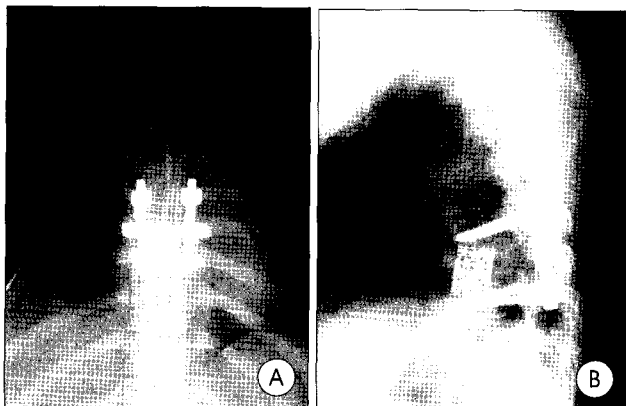


**Fig. 2.** Image-guided placement of pedicle screw instrumentation using CBYON volumetric visualization and navigation software.

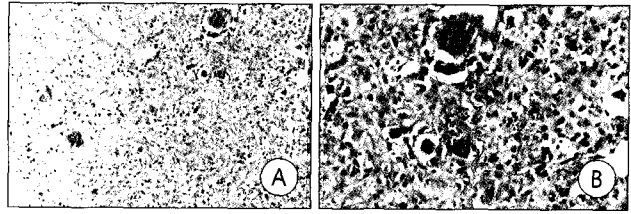
of the vertebral lesion were suggestive of chondroblastoma. The lung biopsy, however, revealed a tuberculoma. Due to the anterior and posterior tumor involvement in the spinal column, the patient required both an anterior and posterior resection and spinal reconstruction. Two weeks after the first operation, remained part of vertebra was removed and posterior stabilization was performed using a pedicle screw fixation and cross linkage bar using the navigation system (Fig. 3). With CBYON guidance system (CBYON, Mountain view, CA, U.S.A.) (Fig. 2), we were able to define the extent of tumor resection from either side of the patient during the operation with a "see through" technique. Volumetric reconstruction of three-dimensional images and filtering features allowed the surgeon to 'see' where and how surgical instruments were being used. There were no neurological complications. The final pathologic diagnosis of the vertebral lesion was benign chondroblastoma (Fig. 4).

## Discussion

Chondroblastoma is an uncommon tumor accounting for approximately one percent of primary benign tumors of bone. Most often found originating from the epiphysis of long bones, chondroblastomas very rarely occur primarily in the vertebra<sup>4,9</sup>. Chondroblastoma of the vertebra was first described by Ewing in 1928<sup>2</sup>. Although benign in nature, a



**Fig. 3.** Postoperative anterior-posterior (A) and lateral radiograph (B).



**Fig. 4.** Prominent osteoclast-like giant cell mixed a plump and polygonal intervening tumor cell (A, H&E X 100) (B, H&E X 200).

tendency for a chondroblastoma to recur locally is a well recognized feature of this tumor. The relapse rate for the vertebral chondroblastomas is apparently higher than the 5~10% reported for the chondroblastomas originating in extravertebral sites<sup>1</sup>. The age at diagnosis of chondroblastomas range from 9 to 59 years, but the lesions occur in vast majority of cases in the second decade of life. Men seem to be more commonly affected than women<sup>5</sup>. Chondroblastomas have characteristic MR findings which correlate well with its histopathological features. Signal intensity on T1- and T2-weighted MR images and the patterns of contrast enhancement of chondroblastomas are dependent on the amounts of immature chondroid matrix, the cellularity of the chondroblasts, the calcifications, the hemosiderin, and the aneurysmal bone cyst components<sup>3</sup>. Unfortunately, the radiologic features of vertebral chondroblastomas are nonspecific and not diagnostic. The differential diagnosis include such entities as an aneurysmal bone cyst, a giant cell tumor, a chordoma, a spondylitis especially of the tuberculous origin, a chondromyxoid fibroma and metastasis<sup>6</sup>.

Curettage or resection is the primary treatment of choice. Occasional tumor recurrence indicate the necessity for complete removal of tumor<sup>1</sup>. In our case, complete removal was not achieved in the initial operation, because of bilateral pedicle invasion of the tumor. Fourteen days after the first operation, we performed the second operation. Total removal of tumor and spinal stabilization was achieved at that time.

Computer-assisted techniques were introduced into clinical practice in spine surgery at the beginning of the 1990s. Computer assistance has been shown to significantly improve the accuracy and safety of pedicle screw insertion under clinical conditions<sup>8</sup>. Mizuno et al. reported the combined anterior and posterior stabilization assisted with a navigation system in the patient with severe cervical injuries<sup>7</sup>.

## Conclusion

Chondroblastomas very rarely occur primarily in the vertebra. Although benign in nature, a tendency for a

## Thoracic Chondroblastoma

chondroblastoma to recur locally is a well recognized feature of this tumor. The high rate of recurrence indicates the necessity for the complete removal of this tumor. The navigation system is a useful method for resection and reconstruction of spine.

## References

1. Attar A, Ugur HC, Caglar YS, Erdogan A, Ozdemir N : Chondroblastoma of the thoracic vertebra. **J Clin Neurosci** 8 : 59-60, 2001
2. Ewing J : The classification and treatment of bone sarcoma. Report of the international Conference on Cancer. **Bristol J Write** 12 : 365-376, 1928
3. Jee WH, Park YK, McCauley TR, Choi KH : Chondroblastoma : MR characteristics with pathologic correlation. **J Comput Assist Tomogr** 23 : 721-726, 1999
4. Kim JY, Cho KH, Kim SH, Ahn YH, Ahn YM, Yoon SH, et al : Solitary Osteochondroma of the Thoracic Spine Presenting as Spinal Cord Compression : A case report. **J Korean Neurosurg Soc** 27 : 1304-1309, 1998
5. Kurth AA, Warzecha J, Rittmeister M, Schmitt E, Hovy L : Recurrent chondroblastoma of the upper thoracic spine : A case report and review of the literature. **Arch Orthop Trauma Surg** 120 : 544-547, 2000
6. Leung LY, Shu SJ, Chan MK, Chan CH : Chondroblastoma of the lumbar vertebra. **Skeletal Radiol** 30 : 710-713, 2001
7. Mizuno J, Nakagawa H, Watabe T : Combined anterior and posterior instrumentation in severe fracture-dislocation of the lower cervical spine with help of navigation : A case report. **J Clin Neurosci** 9 : 446-450, 2001
8. Schlenzka D, Laine T, Lund T : Computer-assisted spine surgery. **Eur Spine** 9 : S57-S64, 2000
9. Springfield DS, Capanna R, Gherlinzoni F, Picci P, Campanacci M : Chondroblastoma : A review of seventy cases. **J Bone Joint Surg** 67 : 748-755, 1985