

Management of Recurrent Vestibular Schwannomas

Wook Ha Kim, M.D., Chul-Kee Park, M.D., Dong Gyu Kim, M.D., Hee-Won Jung, M.D.

Department of Neurosurgery, Seoul National University College of Medicine, Clinical Research Institute, Seoul, Korea

Objective : Management of recurrent vestibular schwannomas(VS) after microsurgery or radiosurgery is a complicated subject. However, few studies have documented the outcome of recurrent VS. The authors review clinical experience of recurrent VS management and analyzed the efficacy of treatment modalities.

Methods : Between 1990 and 2002, 293 patients harboring unilateral VS underwent, microsurgery, radiosurgery, microsurgery followed by radiosurgery. Of these, 26 procedures (in 20 patients) were performed to treat recurrent VS. Recurrence was assessed from an increased tumor size by magnetic resonance imaging(MRI). The mean age of patients with recurred VS was 46.9 years and the mean follow-up period was 68 months. Radiological characteristics were investigated and growth rates of recurred tumors were calculated by measuring changes in tumor diameter on MRI after treatment.

Results : MRI characteristics revealed a lobulated contour in 75% and a cyst in 60% of the patients. Only 1 patient showed neither lobulation nor a cyst. The average diameter of the recurrent tumors were 36.9mm. The overall tumor control rate for initial management was 87.4%, 94.7%, and 98.5% for microsurgery, radiosurgery, and microsurgery plus radiosurgery, respectively. However, control rates for recurrent tumors were lower at 85%, 63%, and 80%, respectively.

Conclusion : A cystic nature and a lobulated tumor contour are frequent clinical characteristics of recurrent VS. Microsurgery or microsurgery followed by radiosurgery shows little difference in tumor control rate for primary and recurrent VS. However, radiosurgery alone appears to be less beneficial for recurrent VS.

KEY WORDS : Recurrent vestibular schwannoma · Management · Microsurgery · Radiosurgery.

Introduction

Vestibular schwannoma is a benign tumor that arises from Schwann cells of the vestibulocochlear nerve. When the tumor is diagnosed, various treatment options such as observation, microsurgery, radiosurgery, and multidisciplinary treatment are available¹⁴. Of these, microsurgery has been the mainstay treatment as the technique has improved remarkably to report acceptable results in terms of tumor control and functional preservation. However, the management of VS remains still a difficult topic to most neurosurgeons. Recently, stereotactic radiosurgery has become a powerful alternative modality for small vestibular schwannoma management, and tumor control rates of 87 to 98% have been reported for follow-ups longer than 10 years^{12,18}. Moreover, facial nerve and hearing function preservation were found to be as high as 99% and 78.6%, respectively¹⁸. To improve patient quality of life with acceptable tumor control, combined microsurgery and radiosurgery approaches for the treatment of large VS have also

been advocated¹⁴.

Despite all efforts, the overall recurrence rates of VS after various treatment modalities are 0% to 44%^{2,7,8,24-27}. For recurrent VS, selection of optimal treatment modality is controversial. Some authors treat recurrent VS after previous microsurgery by repeated microsurgery only^{1,2,6,23}. While other insist on radiosurgery for the treatment of recurrent VS after prior microsurgery^{21,32}. Moreover, recurrence after radiosurgery has the same problems^{12,17,18,22}. Thus generally acceptable treatment guidelines are indispensable.

In this study, we analyzed clinical characteristics and outcomes of recurred VS according to treatment modality, and discussed the causes of treatment failure.

Materials and Methods

The present series comprised 20 patients and 26 procedures of recurrent VS (20 recurrence, 6 repeated recurrence) among 293 patients (46 microsurgery; 86 radiosurgery; 61

• Received : July 11, 2005 • Accepted : September 14, 2005

• Address for reprints : Hee-Won Jung, M.D., Department of Neurosurgery, Seoul National University College of Medicine, Clinical Research Institute, 28 Yeongeon-dong, Jongno-gu, Seoul 110-744, Korea Tel : +82-2-2072-2355, Fax : +82-2-744-2339, E-mail : hwnjung@snu.ac.kr

microsurgery followed by radiosurgery) who were treated between 1990 and 2002. The recurrent cases consisted of 8 males and 12 females of mean age 46.9 years (range 19~63 years) with a mean follow-up period of 68 months (range 21~121 months). Patients with VS associated with neurofibromatosis were excluded.

Tumors were measured in x, y, and z dimensions using a computerized magnetic resonance imaging(MRI) system. These measurements included tumor dimension parallel to the petrous bone (x), perpendicular to the petrous bone at the internal auditory canal in axial images (y), and longest superoinferior dimension in coronal images (z). Treating the tumor shape as an ellipsoid, we assessed its volume using the following formula;

$$V = \frac{4\pi xyz}{3 \times 2^3}$$

Tumor equivalent diameter (d) was defined as :

$$d = (xyz)^{1/3}$$

Radiological characteristics were carefully investigated and the growth rates of recurred tumors were calculated by measuring tumor diameter changes on MR images after treatment. Recurrence was assessed from increased tumor size in MR images with or without symptom aggravation.

Results

Initial tumor control was achieved in 83.3% (128 of 146) in the microsurgery group, 97.7% (84 of 86) in the radiosurgery group, and in 100% (61 of 61) in the microsurgery followed by radiosurgery group. The initial recurrence rate was 6.8%. The mean recur-free time of the 20 patients was 40.6 months (range 5~113 months). At the time of initial management the average tumor volume of the recurred cases was 28.1cc (range 6.0~47.1cc). And the average tumor volume of the first recurrence was 35.6cc (range 2.7~108.7cc).

The mean time to the second recurrence of 6 cases was 25.3 months (range 8~68 months) and the average tumor volume of the second recurrence was 24.2cc (range 1.1~61.6cc).

The management of recurrent VS is summarized (Fig. 1). Of 18 recurrent VS after microsurgery, 8 patients underwent microsurgery, 7 radiosurgery, and 3 microsurgery followed by radiosurgery, and 2 patients with recurrent VS after radiosurgery underwent microsurgery. The average residual tumor volume of the recurrent tumor after microsurgery was 9.0cc (range 0~27.2cc) including two gross-total resections and the tumor volume which underwent radiosurgery after the first recurrence was 6.5cc (range 2.7~11.1cc).

Second recurrence developed in 6 patients; 2 after microsurgery, 3 after radiosurgery, and 1 after microsurgery followed by

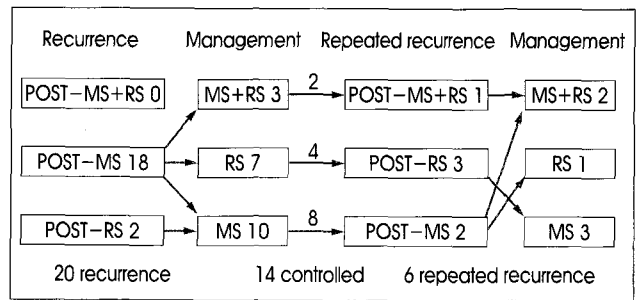


Fig. 1. Management flow sheet for the recurrent vestibular schwannomas in the present series.

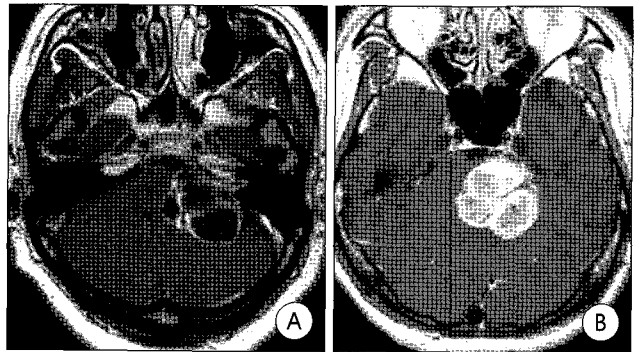


Fig. 2. The characteristic features frequently observed in the recurrent vestibular schwannomas. Cystic nature of the tumor (A) and lobulated contour (B).

radiosurgery. Thus the tumor control rates for recurrent tumors were 85% (11/13) for microsurgery, 63% (5/8) for radiosurgery, and 80% (4/5) for microsurgery followed by radiosurgery, respectively. The radiological characteristics of recurrent VS were interesting. A cystic portion was detected in 12 patients (60%), and a lobulating feature was noticed in 15 (75%) (Fig. 2). Only one case had neither cyst nor lobulation.

Facial nerve function was assessed at the last follow-up in the recurrent VS. Regarding House-Brackman grade 1 and 2 as functional preservation, facial nerve function was preserved in only 5 patients (25%).

Discussion

Recurrence of vestibular schwannoma : risk factors

Recurrence of VS after treatment using microsurgery(MS) or radiosurgery(RS) has been widely reported with rates ranging from 0% to 44%^{2,7,8,24-27,30}. Diverse reported recurrence rates are caused by differences in follow-up periods, differing definitions of the extent of tumor resection, and the different diagnostic procedures used to assess tumor recurrence²⁴.

Indeed recurrence developed even after complete resection of VS, incomplete resection of the tumor has greater chance for recurrence^{2,8}. Several situations can prevent total tumor resection, i.e., excessive tumor vascularity, firm adherence of the tumor to critical neural or vascular structures, extensive

growth deep in the temporal bone, or a poor general patient condition²⁴). Moreover, tumors with a diameter exceeding 3cm have a greater likelihood of recurring after microsurgery or radiosurgery³.

Cystic changes in VS are well known^{2,4,5,10,15,19,20,29,31,32}). The exact location of the facial nerve is unusual in these kind of tumors, and this may cause accidental injury despite intraoperative facial nerve monitoring^{4,15}). When a cystic VS expands and compresses the brain stem and/or the cerebellum, complete tumor removal is difficult due to adherence and avoided to protect neural structures²⁸). Thus, a portion of the cyst wall is left and this may allow recurrence development^{4,23}).

In this study, recurrent VSs showed a cystic nature and a lobulated contour in preoperative images. We recommend meticulous extirpation of the tumor with these characteristics and frequent image follow-up.

Management of recurred vestibular schwannoma

Little information has been provided on the treatment of recurrent VS, and thus microsurgery, radiosurgery, or microsurgery followed by radiosurgery, that are the modalities applied for primary VS are also used to treat recurrent VS. Beatty et al. and others suggested repeated surgical resection as a first-line treatment of choice for recurrent VS in cases treated by microsurgery^{1,23}). Despite reports that postoperative complications such as cerebrospinal fluid leak, ataxia, facial nerve palsy, and/or other multiple cranial nerve deficits are more frequent for repeated microsurgery, surgeons tend to have individual preferences for repeated surgery^{8,23}). However, some authors recommend that patients with recurrence or evidence of a growing tumor following surgery should be referred for radiosurgery³²). Pollock et al²¹) reported radiosurgical outcome in 76 patients who had recurred after one or more microsurgies. Tumor growth control was achieved in 73 patients (94%), and 5 patients experienced tumor progression and required further treatment (microsurgery in 4 cases and repeated radiosurgery in one case). In another study³²) radiosurgery was found to control tumor growth in 48 of 50 patients (96%).

Microsurgery or radiosurgery have also been applied to treat recurrent VS after radiosurgery failed to achieve tumor growth control^{11,17,21,22,28}). Reoperations of the recurrent tumor previously treated with radiosurgery were considered to be more difficult to resect because of tumor fibrosis, loss of the peritumoral arachnoidal plane, and a combination of tumor fibrosis and adjacent scarring^{17,21,22}). However, the reported experience about this problem is variable and no definite conclusion can be made^{11,28}).

In our series, the treatment modalities selected for recurrent VS were chosen based on tumor characteristics, relationship with neural structures, patient general condition, comorbidities,

and patient preference. Tumor growth control was fairly achieved for 11 of 13 (85%) recurrent tumors in the microsurgery group and for 4 of 5 cases (80%) in the microsurgery followed by radiosurgery group respectively. However, in terms of radiosurgical outcome, the result was disappointing. The tumor control rate was only 63% (5 of 8 cases) for the recurrent tumors which contrasted with 97.7% (84 of 86 cases) for primary tumors, but this outcome was limited because the included cases were small to induce the generalization.

Causes for radiosurgical failure

In our study, radiosurgical outcome for recurrent VS showed a lower tumor control rate than microsurgery or combination therapy. Only one second recurrence developed among the ten first recurrences with 9.0cc of the average residual volume although the tumor volume treated with RS was 6.5cc resulting in 3 second recurrences. The tumor volume made no significant difference in terms of treatment outcome in our results. All radiosurgically failed cases showed cystic and lobulating characteristics. Among them, 3 patients with a cystic component developed a second recurrence and required repeated microsurgery. Bloch et al. advocated that stereotactic radiosurgery is not effective at treating cystic recurrence, because the condition is not caused by rapid cell division. It was further suggested that radiosurgery might even stimulate further cystic expansion in such patients²). Pendl et al reported that cyst enlargement as early as 4 months after radiosurgery in all six cases with a cystic portion treated by radiosurgery²⁰). Thus unsatisfactory results of radiosurgical outcome for recurred VS in the present series are originated from the cystic characteristics of the tumor which frequently recurs. More sophisticated study on the mechanism of this problem is required to confirm.

Conclusion

A cystic nature and a lobulated tumor contour are frequently identified in recurrent VS. Microsurgery or microsurgery followed by radiosurgery shows little difference in terms of tumor control rate for primary or recurrent VS. However, radiosurgery alone appears to be less beneficial in recurrent VS despite its high efficacy as a primary treatment.

• Acknowledgement

This work was partially supported by grants from the Seoul National University Hospital and The Korea Brain and Spinal Cord Research Foundation.

References

1. Beatty CW, Ebersold MJ, Harner SG : Residual and recurrent acoustic neuromas. *Laryngoscope* 97 : 1168-1171, 1987
2. Bloch DC, Oghalai JS, Jackler RK, Osofsky M, Pitts LH : The fate of the tumor remnant after less-than-complete acoustic neuroma resection.

- Otolaryngol Head Neck Surg** 130 : 104-112, 2004
3. Cerullo LJ, Grutsch J, Osterdock R : Recurrence of vestibular (acoustic) schwannomas in surgical patients where preservation of facial and cochlear nerve is the priority. **Br J Neurosurg** 12 : 547-552, 1998
 4. Charabi S, Tos M, Borgesen SE, Thomsen J : Cystic acoustic neuromas. Results of translabyrinthine surgery. **Arch Otolaryngol Head Neck Surg** 120 : 1333-1338, 1994
 5. Charabi S, Tos M, Thomsen J, Pygaard J, Fundova P, Charabi B : Cystic vestibular schwannoma : clinical and experimental studies. **Acta Otolaryngol Suppl** 543 : 11-13, 2000
 6. Darrouzet V, Martel J, Enee V, Bebear JP, Guerin J : Vestibular schwannoma surgery outcomes : our multidisciplinary experience in 400 cases over 17 years. **Laryngoscope** 114 : 681-688, 2004
 7. Ebersold MJ, Harner SG, Beatty CW, Harper CM Jr, Quast LM : Current results of the retrosigmoid approach to acoustic neurinoma. **J Neurosurg** 76 : 901-909, 1992
 8. El-Kashlan HK, Zeitoun H, Arts HA, Hoff JT, Telian SA : Recurrence of acoustic neuroma after incomplete resection. **Am J Otol** 21 : 389-92, 2000
 9. Fischer G, Fischer C, Remond J : Hearing preservation in acoustic neurinoma surgery. **J Neurosurg** 76 : 910-917, 1992
 10. Fundova P, Charabi S, Tos M, Thomsen J : Cystic vestibular schwannomas : surgical outcome. **J Laryngol Otol** 114 : 935-939, 2000
 11. Gormley WB, Sekhar LN, Wright DC, Kamerer D, Schessel D : Acoustic neuromas : results of current surgical management. **Neurosurgery** 41 : 50-60, 1997
 12. Hasegawa T, Kida Y, Kobayashi T, Yoshimoto M, Mori Y, Yoshida J : Long-term outcomes in patients with vestibular schwannoma treated using gamma knife surgery : 10-year follow up. **J Neurosurg** 102 : 10-16, 2005
 13. Hong HJ, Yi HJ, Oh SJ, Ko Y : Cystic non-enhancing vestibular schwannoma with unusual clinical presentation. **J Korean Neurosurg Soc** 35 : 214-216, 2004
 14. Iwai Y, Yamanaka K, Ishiguro T : Surgery combined with radiosurgery of larger acoustic neuromas. **Surg Neurol** 59 : 283-291, 2003
 15. Kameyama S, Tanaka R, Kawaguchi T, Fukuda M, Oyanagi K : Cystic acoustic neurinomas : studies of 14 cases. **Acta Neurochir (Wien)** 138 : 695-699, 1996
 16. Karpinos M, Teh BS, Zeck O, Carpenter LS, Phan C, Mai WY, et al : Treatment of acoustic neuroma : stereotactic radiosurgery vs. microsurgery. **Int J Radiat Oncol Biol Phys** 54 : 1410-1421, 2002
 17. Lee DJ, Westra WH, Staecker H, Long D, Niparko JK : Clinical and histopathologic features of recurrent vestibular schwannoma (acoustic neuroma) after stereotactic radiosurgery. **Otol Neurotol** 24 : 650-660, 2003
 18. Lunsford LD, Niranjan A, Klickinger JC, Maitz A, Kondziolka D : Radiosurgery of vestibular schwannoma : summary of experience in 829 cases. **J Neurosurg (Suppl)** 102 : 195-199, 2005
 19. Muzumdar DP, Goel A, Pakhmode CK : Multicystic acoustic neurinoma : report of two cases. **J Clin Neurosci** 9 : 453-455, 2002
 20. Pendl G, Ganz JC, Kitz K, Eustacchio S : Acoustic neurinomas with macrocysts treated with gamma knife radiosurgery. **Stereotact Funct Neurosurg (Suppl 1)** 66 : 103-111, 1996
 21. Pollock BE, Lunsford LD, Flickinger JC, Clyde BL, Kondziolka D : Vestibular schwannoma management. Part I. Failed microsurgery and the role of delayed stereotactic radiosurgery. **J Neurosurg** 89 : 944-948, 1998
 22. Pollock BE, Lunsford LD, Kondziolka D, Sekula R, Subach BR, Foote RL, et al : Vestibular schwannoma management. Part II. Failed radiosurgery and the role of delayed microsurgery. **J Neurosurg** 89 : 949-955, 1998
 23. Robertson JB Jr, Brackmann DE, Hittselberger WE : Acoustic neuroma recurrence after suboccipital resection : management with translabyrinthine resection. **Am J Otol** 17 : 307-311, 1996
 24. Sakaki S, Nakagawa K, Hatakeyama T, Murakami Y, Ohue S, Matsuoka K : Recurrence after incompletely resected acoustic neurinomas. **Med J Osaka Univ** 40 : 59-66, 1991
 25. Samii M, Matthies C : Management of 1000 vestibular schwannomas (acoustic neuromas) : surgical management and results with an emphasis on complications and how to avoid them. **Neurosurgery** 40 : 11-23, 1997
 26. Sampath P, Holliday MJ, Brem H, Niparko JK, Long DM : Facial nerve injury in acoustic neuroma (vestibular schwannoma) surgery : etiology and prevention. **J Neurosurg** 87 : 60-66, 1997
 27. Schessel DA, Nedzelski JM, Kassel EE, Rowed DW : Recurrence rates of acoustic neuroma in hearing preservation surgery. **Am J Otol** 13 : 233-235, 1992
 28. Slattery WH III, Brackmann DE : Results of surgery following stereotactic irradiation for acoustic neuromas. **Am J Otol** 16 : 315-321, 1995
 29. Sugimoto T, Tsutsumi T, Noguchi Y, Tsunoda A, Kitamura K, Komatsuzaki A : Relationship between cystic change and rotatory vertigo in patients with acoustic neuroma. **Acta Otolaryngol Suppl** 542 : 9-12, 2000
 30. Thomassin JM, Pellet W, Epron JP, Braccini F, Roche PH : Recurrent acoustic neurinoma after complete surgical resection. **Ann Otolaryngol Chir Cervicofac** 118 : 3-10, 2001
 31. Unger F, Walch C, Haselsberger K, Papaefthymiou G, Trummer M, Eustacchio S, et al : Radiosurgery of vestibular schwannoma : a minimally invasive alternative to microsurgery. **Acta Neurochir (Wien)** 141 : 1281-1286, 1999
 32. Unger F, Walch C, Papaefthymiou G, Feichtinger K, Trummer M, Pendl G : Radiosurgery of residual and recurrent vestibular schwannoma. **Acta Neurochir** 144 : 671-677, 2002

Commentary

The authors performed a valuable analysis of 20 cases of recurrent vestibular schwannomas (VS). They attempted to identify the characteristic findings on MR images that could signal the possibility of recurrence later. Moreover, their results were very rewarding in that they analyzed the efficacy of each treatment modality for recurrent VS. The authors suggested that tumor with lobulating contour or cystic nature should be closely followed up. Also, their results supported that radiosurgery alone appeared to be less beneficial for recurrent VS.

The finding that recurrence rate of microsurgery alone was 36.7% (18 of 49 patients), in contrast to radiosurgery alone, recurrence rate of which was 2.3% (2 of 86), illustrates that radiosurgery alone is superior to microsurgical resection alone in regard to local control rate (Unfortunately, it was not described accurately whether complete tumor removal or subtotal resection was performed at the previous resection). However, stereotactic radiosurgery alone was less beneficial in recurrent VS, whereas adjuvant stereotactic radiosurgery for residual tumor mass was very highly effective (local control rate : 100%). Relatively low efficacy of radiosurgery for recurrent VS may be attributed to the distinct nature of recurrent VS; rapid growth and aggressiveness. The authors demonstrated that the majority of recurrent VS presented with lobulating contour and cystic nature on MR images. These findings are well concordant with the results of recent another report¹⁾. These data will add substantially to the growing pool of information about characteristic radiological findings of recurrent VS. It would be better to be described more in detail which findings were observed in 6 patients who showed second recurrence, as well as first recurrence.

I expect other immunohistological prognostic factors for developing recurrence would be identified in the next study.

Jong Hyun Kim, M.D.
Department of Neurosurgery, Sungkyunkwan University

Reference

1. Hwang SK, Kim DG, Paek SH, Kim CY, Kim MK, Choi JG, et al : Aggressive vestibular schwannomas with postoperative rapid growth : clinicopathological analysis of 15 cases. **Neurosurgery** 51 : 1381-1391, 2002