

# Rapid canine retraction in a Class II bialveolar protrusion case using a lingually extended distraction screw

Kwang-Seok Ahn, DDS, MSD,<sup>a</sup> Euk Joo, DDS, MSD,<sup>a</sup> Ju-Young Park, DDS,<sup>a</sup> Young-Kyu Ryu, DDS, MSD, PhD,<sup>b</sup> In-Ho Cha, DDS, MSD, PhD,<sup>c</sup> Kee-Joon Lee, DDS, MSD, PhD<sup>d</sup>

Rapid canine retraction, first introduced by Liou, is a distraction osteogenesis applied to the periodontal ligament tissue. Rapid tooth movement was facilitated by establishing minimal bony resistance on the distal surface of the canine by socket preparation and by osteogenesis on the mesial side in response to the periodontal distraction. Since undesired buccal tipping or extrusion of the canine during retraction tends to occur, it is crucial to maintain the firm path of movement and the axis of the canine during retraction. In order to improve the predictability of the canine movement, lingually extended distraction screws with heavy labial guiding wires were designed. Prefabricated plastic canine models for the estimation of socket depth and miniscrew implants for anchorage reinforcement were also devised. Applying these devices to a female patient with Class II anterior protrusion, the whole treatment was effectively finished in 13 months. Loss of vitality or periodontal problems did not occur throughout treatment, and stable occlusion was maintained during 10 months of retention. This case report demonstrates that a predictable rapid canine retraction can be achieved through the use of this modified technique. (*Korean J Orthod* 2006;36(4):308-20)

**Key words:** Rapid canine retraction, Periodontal distraction, Lingually extended distraction screw, Anterior protrusion

## INTRODUCTION

As the demands for esthetic appearances increase, so

does the demand for orthodontic treatment.<sup>1</sup> However, particularly for adults actively involved in social life, an average treatment time of around 2 years is still a limiting factor, possibly causing reluctance to begin orthodontic treatment.<sup>2,3</sup>

Several approaches such as subapical osteotomy, corticotomy and cortical punching have been attempted to facilitate tooth or teeth movement, all requiring separate invasive surgical procedures.<sup>4,5</sup> In contrast, Liou has introduced a protocol for novel rapid canine retraction involving a simple surgical extension of the extraction sockets simultaneously with the removal of the bicuspid, leaving only a minimal bony layer on the distal side of the canine (Fig 1, A).<sup>6</sup> A thinned distal socket wall secures the survival of the periodontal ligament cells and also provides reduced mechanical

---

From Yonsei University, Seoul, Korea.

<sup>a</sup>Resident, <sup>b</sup>Professor Emeritus, Department of Orthodontics.

<sup>c</sup>Professor, Department of Oral and Maxillofacial Surgery.

<sup>d</sup>Assistant Professor, Department of Orthodontics, College of Dentistry and Oral Science Research Center, Institute of Craniofacial Deformity.

Corresponding author: **Kee-Joon Lee**

Department of Orthodontics, College of Dentistry, Yonsei University, 134 Shinchon-Dong, Seodaemun-Gu, 120-752 Seoul, Korea.

+82 2 2228 3105; e-mail, orthojn@yumc.yonsei.ac.kr.

Received September 30, 2005; Last Revision January 27, 2006;

Accepted January 29, 2006.

\*This article was supported by the Institute of Craniofacial Deformity, 2004 Yonsei University research fund.

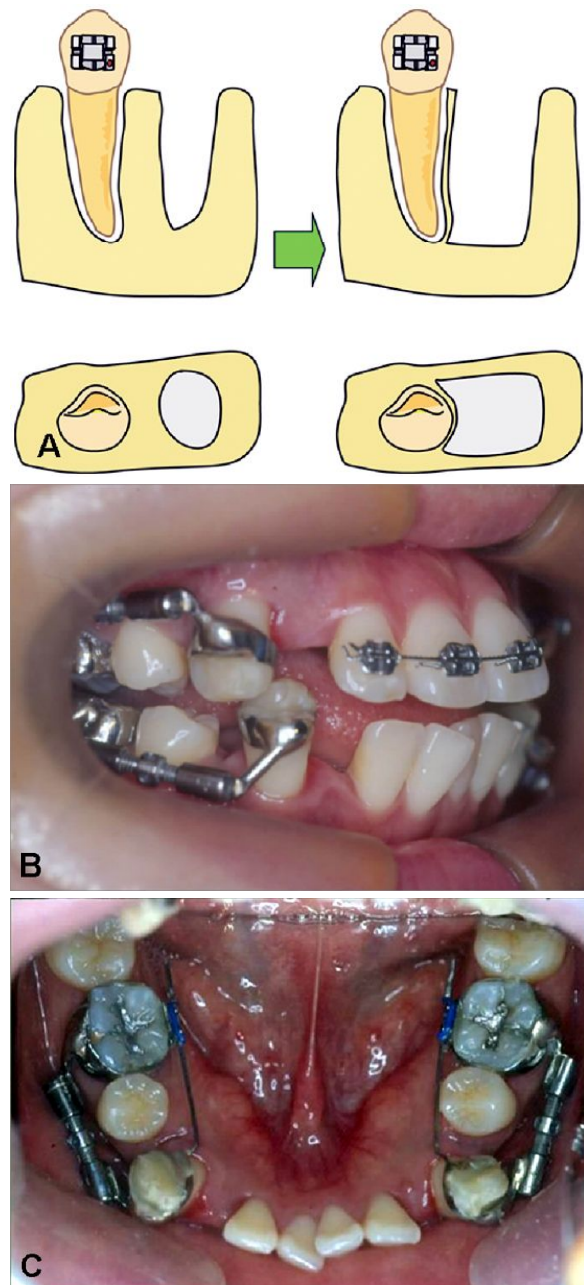
resistance to canine distalization, allowing for rapid tooth movement. On the mesial side, new bone formation is enhanced as the periodontal ligament space is widened. This concept was derived from distraction osteotomy, regarding the periodontal ligament as a type of suture similar to the midpalatal suture.<sup>6</sup> The main appliance for canine retraction consists of bands on the first molars and the canines, with the distraction screws on the buccal side guided by an archwire (Fig 1, B). The distraction screws are activated twice a day in order for the canine retraction to be finished in two to three weeks. The clinical validity of this technique was demonstrated by others.<sup>7</sup>

For more predictable canine movement, precise preparation of the socket wall to the depth of the canine root apex is a prerequisite. In particular, it is crucial to maintain the path of movement as well as the axis of the canine throughout the retraction, since buccal tipping or extrusion of the canine during retraction tend to occur, as Liou has already indicated (Fig 1, C).<sup>8</sup> In maximum anchorage cases, reinforcement of anchorage is necessary for anterior retraction. Based on these inferences, the authors have modified the original appliance and reinforced the protocol, in order to meet those requirements.

The purpose of this report is to propose a lingual retraction screw and its biomechanical advantages, along with other clinical tools, to enhance the efficiency of rapid canine retraction.

## DIAGNOSIS AND TREATMENT PLANNING

An 18-year-old female patient presented with chief complaints of anterior protrusion and crowding (Fig 2). The analysis of her overall facial appearance revealed both upper and lower lip protrusion with considerable lip incompetency. Notably retrognathic chin profile was also observed. There was no significant asymmetry in the frontal view, with the dental midline coincident with the facial midline. The intraoral view exhibited a bilateral Class I molar relation and a slight Class II canine relation. The arch length discrepancies were measured 4 mm in the upper, and 2 mm in the lower arch, respectively.



**Fig 1.** Rapid canine retraction protocol. **A**, Surgical preparation of the first premolar extraction socket; **B**, distraction screws placed on the buccal side; **C**, buccal flaring of the canines tends to occur due to the buccally extended distraction screws, even in the presence of the lingual guiding wires.

The panoramic radiograph did not show any notable pathology other than the impacted third molars in the

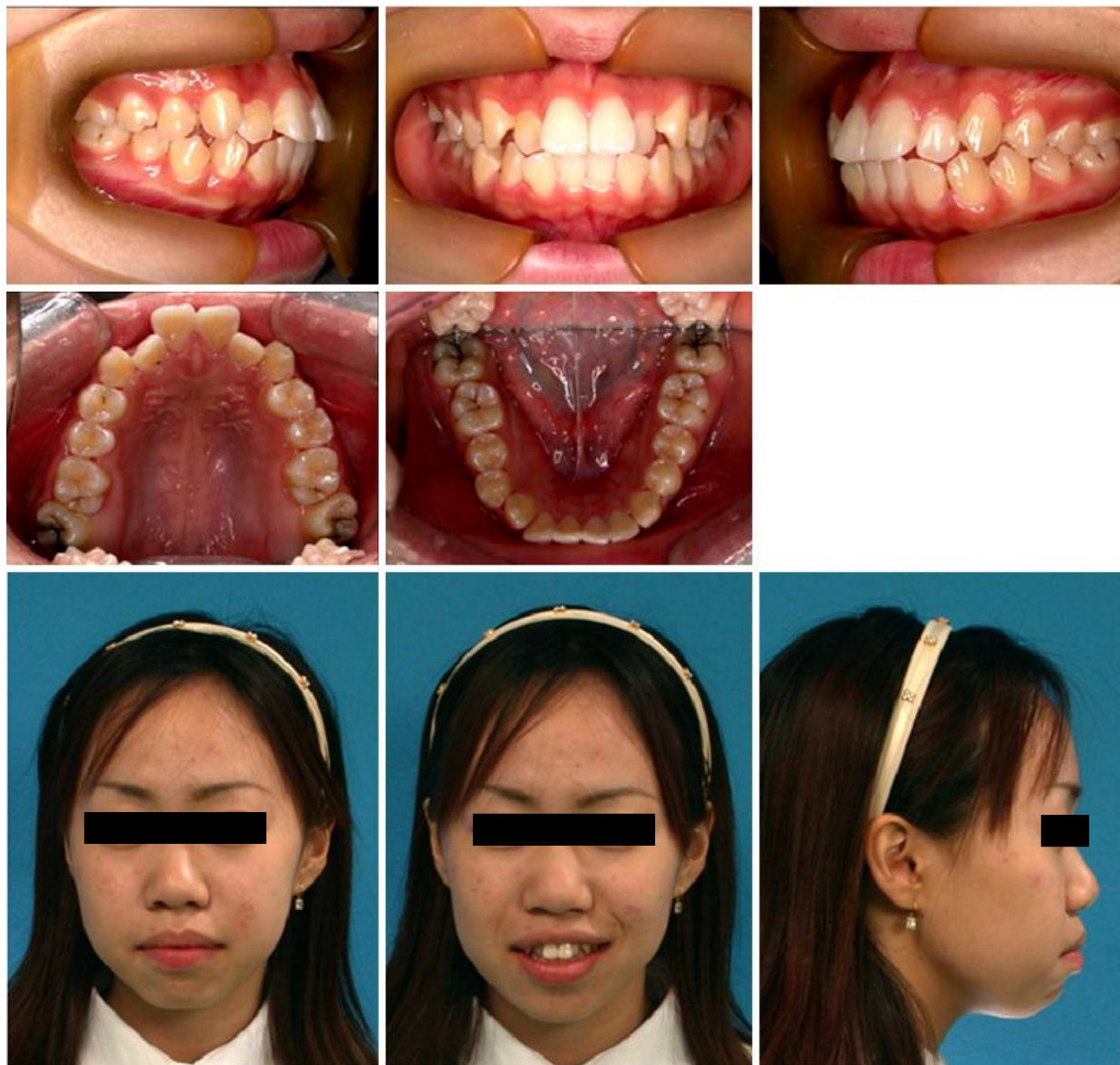

Fig 2. Pretreatment facial and intraoral photographs.

maxilla and mandible (Fig 3). A minor reduction of alveolar height was noticed especially around the upper and lower incisors, which did not significantly affect the treatment planning.

Lateral cephalometric analysis revealed that the patient had a skeletal Class II pattern with an ANB of  $6.7^\circ$ , hyperdivergent facial profile with high gonial angle ( $133.4^\circ$ ), low PFH/AFH ratio (56.8%), and protrusive upper and lower anterior teeth (U1 to SN of

$115.3^\circ$ , IMPA of  $97.2^\circ$ ) (Fig 3). Based on these findings, the case was diagnosed as a skeletal Class II malocclusion with bialveolar protrusion and the extraction of 4 first premolars was planned to improve the lateral profile. Because of the retrusive chin, maximum retraction of both upper and lower anterior teeth was crucial for a significant improvement in the lateral profile. Because she had planned to study abroad in the following year, she wanted to complete her



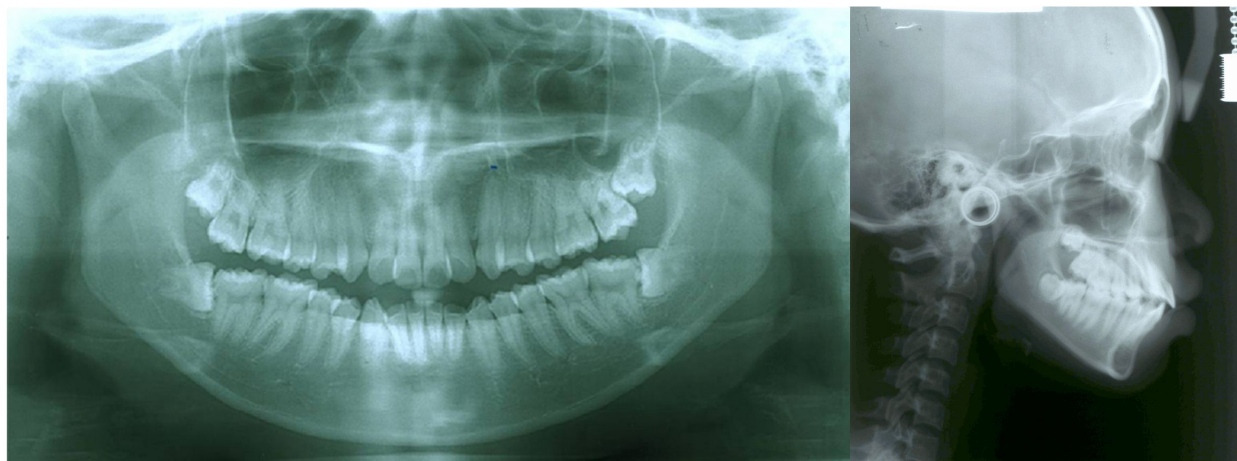

Fig 3. Pretreatment panoramic and cephalometric X-rays.

treatment in around one year. Rapid canine retraction with distraction screw was proposed and accepted by the patient since one of her major concerns was the treatment duration.

Treatment objectives: 1. maximum retraction of upper and lower canines and incisors; 2. maintenance of vertical dimension; 3. establishment of normal occlusion with Class I canine and molar relations; 4. improvement of the soft tissue profile.

## APPLIANCE DESIGN

The following modifications were attempted in this case for predictable rapid tooth movement.

### *Lingually extended distraction screws*

The distraction screws were placed on the palatal/lingual alveolar slopes instead of the buccal areas and connected to the bands with heavy 0.9 mm stainless steel wires (Figs 4 and 5). The lingually positioned distraction screw was expected to exhibit biomechanical advantages compared to the labial approach.

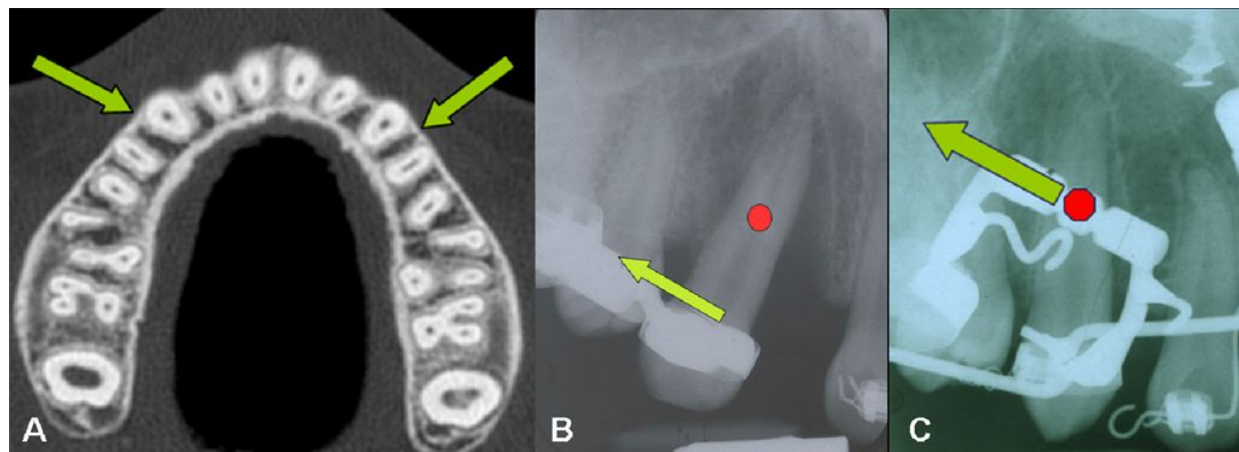
First, it may favor the preservation of the labial cortical plate over the canine root during retraction. As shown on the CT view of the maxillary and mandibular alveolar bone, the canine root is covered by a thin cortical plate on the labial side (Fig 4, A). The

distobuccal surface of the labial plate is mostly depressed, which can be seen both clinically and radiographically. As Liou indicated, a heavy distraction force from the buccal side may induce detrimental buccal flaring and the mesial-out rotation of the canine that can possibly lead to fracture or dehiscence of the buccal plate.<sup>8</sup> In contrast, the distraction screw located on the lingual side does not cause any buccal tipping of the canine. Even in case of lingual tipping and mesial-in rotation of the canine, it would still help to maintain the roots in the basal bone.

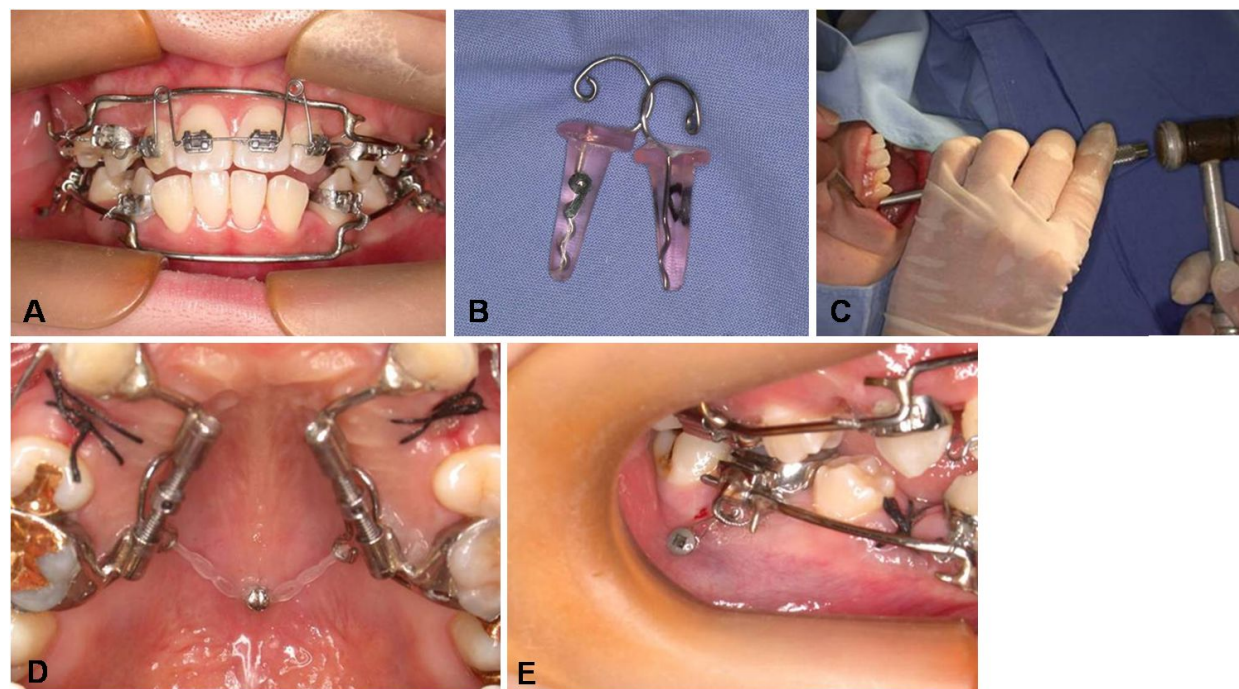
Furthermore, lingual distraction screws allow bodily translation of the canine, since the lever arms on them can be extended enough to the level of the center of resistance. The depth of the buccal vestibule greatly limits the length of the lever arm of the buccal distraction screw, which might lead to probable distal tipping of the canine during retraction (Fig 4, B and C).

### *Heavy labial guiding wire*

Heavy stainless steel guiding wires inserted in the headgear tube were designed to secure the planned distal movement of the canine (Fig 5, A). Because the distalization of the canines will be completed in a few weeks, it is crucial to maintain the path of movement without unnecessary tipping or rotation. It was often found that the orthodontic rectangular archwires may not be rigid enough to be used as guiding wires in



**Fig 4.** Radiographic evaluation for predictable and safe canine retraction. **A**, CT view of the maxilla showing thin buccal plates over the canines; **B**, relationship between the line of force and center of resistance of the canines; **C**, lingual screw with long extension arms (red dot indicates estimated center of resistance of the canine and arrow indicates the direction of force vector).



**Fig 5.** Additional apparatus and techniques for safe canine movement. **A**, Heavy labial guiding wire; **B**, canine root model; **C**, use of Summers osteotome for prevention of damage to the sinus wall; **D**, **E**, anchorage reinforcement with miniscrew implants.

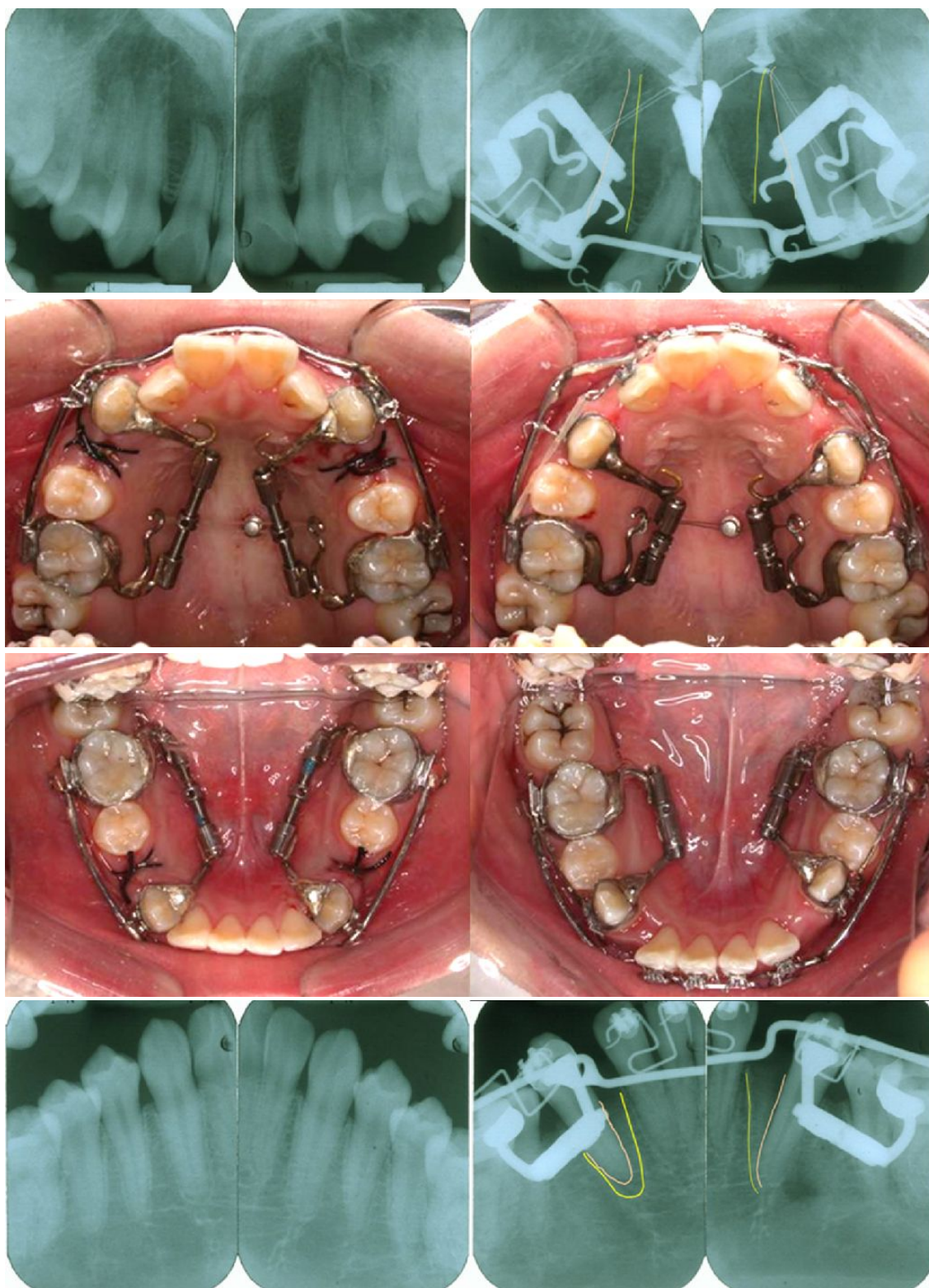rapid canine retraction cases.

#### *Precise and safe surgical procedure*

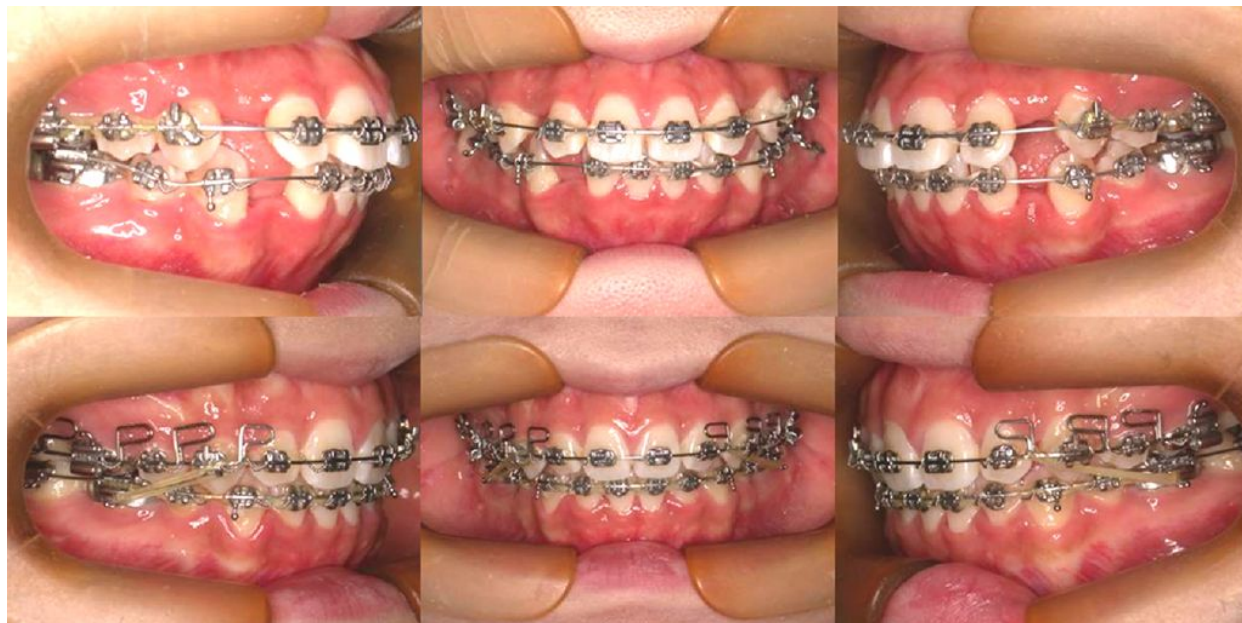
To improve both the efficiency and safety of the

surgical procedure, the following aspects were included. First, canine root models were fabricated using clear resin (Orthocryl, Dentaureum, Ispringen, Germany; Fig 5, *B*) according to the root lengths measured on the





**Fig 6.** Intraoral photographs and periapical X-rays, before and after canine retraction (pretreatment and 3 weeks after treatment).



**Fig 7.** Anterior retraction and finishing procedure.

periapical X-ray films. The root models were inserted in the extraction sockets to confirm the depth. Second, particularly in the maxilla, Summers osteotome (Implant Innovations, Palm Beach Gardens, FL, USA) was used to prevent penetration into the sinus cavity (Fig 5, C). Interdental alveolar bone was dissected and elevated onto the socket base, to protect the sinus wall.

## TREATMENT PROGRESS

Four first bicusps were extracted and adequate preparation of the extraction sockets was performed as described above. The distraction screws were cemented on the molars and canines 24 hours after extraction and surgical preparation. The screws were then activated twice a day, according to the original protocol. Maxillary and mandibular appliances were placed sequentially. Orthodontic mini-implants (Martin medizin-technik, Tuttlingen, Germany) were inserted on the midpalate in the maxilla, and on the buccal alveolar ridge in the mandible. They were then tied to the distraction screws. The mini-implant on the midpalate was placed to maintain the vertical dimension of the upper molars (Fig 6).

The retraction of the canines was completed in 3 weeks in the upper, and 4 weeks in the lower arch. Additional time was needed in the lower arch because of the distal tipping of the canine during retraction. The alignment of incisors was simultaneously performed during canine retraction. Retraction of the incisors was conducted with conventional loop mechanics (Fig 7). Following closure of the remaining spaces, the whole treatment was finished in 13 months. Fixed retainers were bonded on both arches to prevent relapse of the extraction space (Fig 8).

## TREATMENT RESULTS

The facial photograph demonstrates a notable retraction of the lips, reduced tonicidity on the lateral profile and improved competency of the lips in rest position. A more esthetic smile was established as a result of treatment. Although the underlying skeletal discrepancy still existed, the significant improvement in lip profile was enough to mask the recessive chin. Mesial movement of the molars was approximately 1 mm in both arches. Incisors' movement was achieved with controlled tipping and minor intrusion. Although



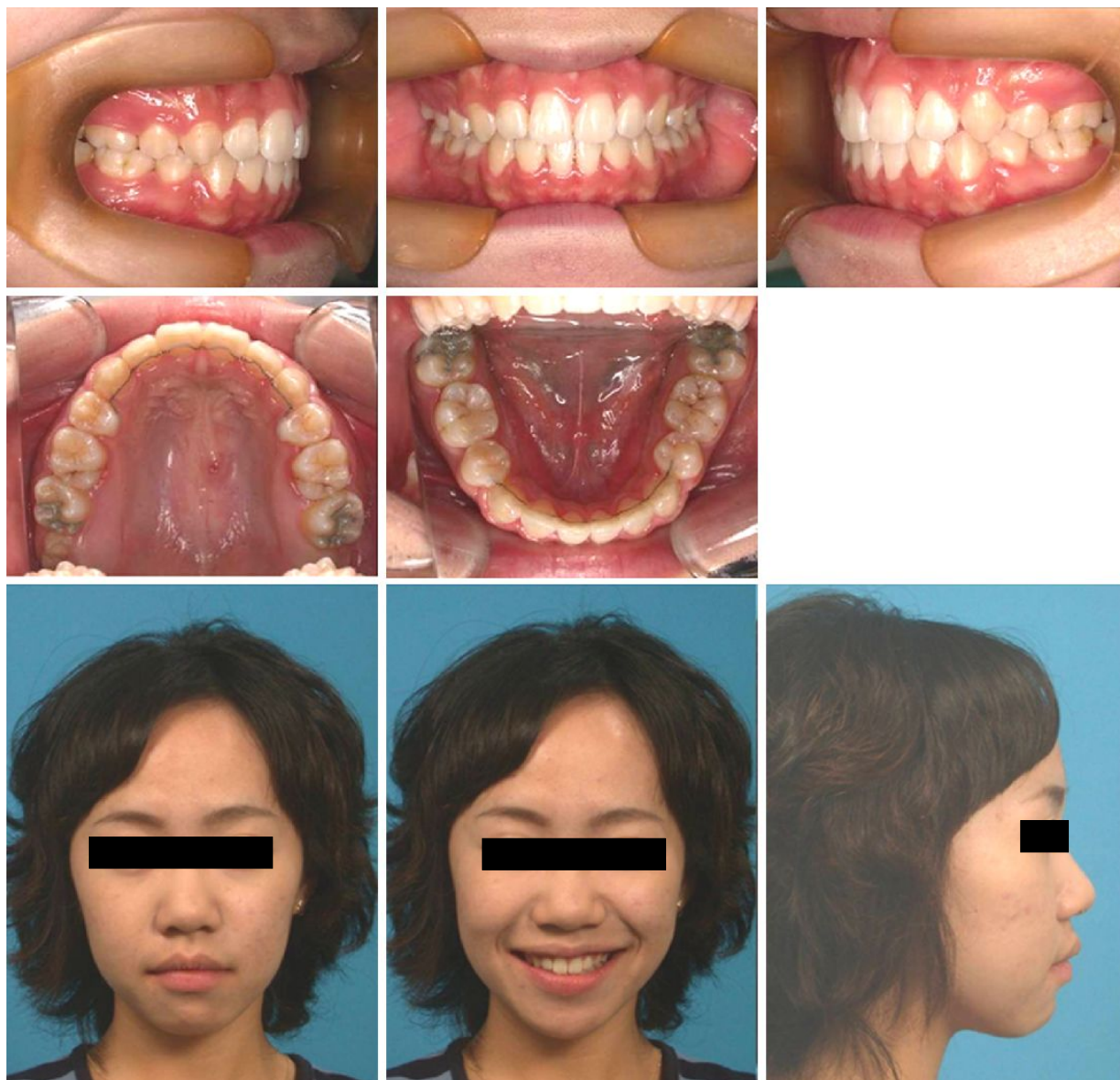

Fig 8. Facial and intraoral photographs after treatment.

the upper incisors were significantly uprighted at the end of treatment, they were still well-balanced by the long facial pattern. The patient was content with the treatment outcome (Fig 9).

The superimposition of the two lateral cephalograms demonstrates the adequate retraction of anterior teeth by the intrusion of the incisors and minimal loss of anchorage (Fig 9).

## RETENTION

The intraoral and extraoral views at 10 months after the completion of treatment show that the treatment outcome had been maintained appropriately throughout the retention time (Fig 10). The vitality and periodontal health of the canines were evaluated both in the clinical and radiological measures and they showed no abnormalities. Minor bleeding on probing on the lingual



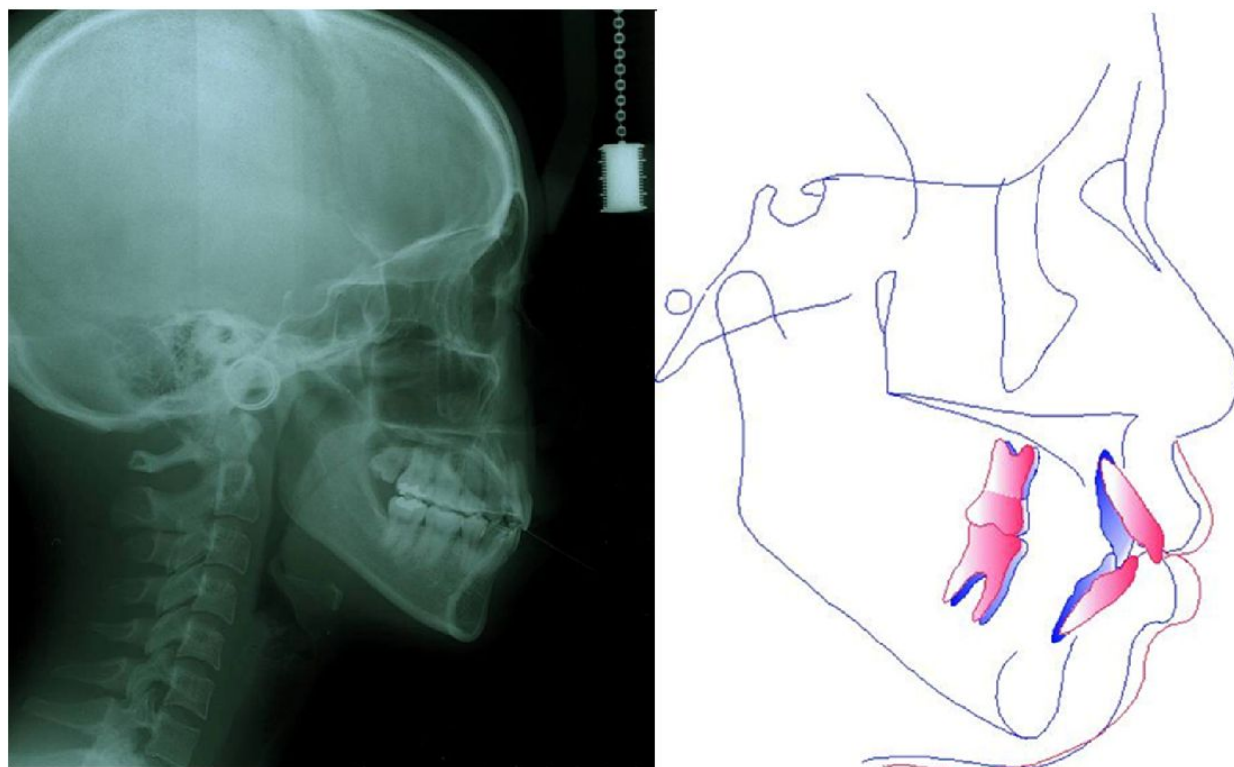


Fig 9. Cephalometric X-ray after treatment and superimposition of pre- and post-treatment cephalograms.

surfaces of the lower canines were present due to accumulation of calculus underneath the fixed retainer (Fig 11).

## DISCUSSION

The determinants for successful retraction of the canines include an effective surgical preparation with minimal trauma and a precisely adjusted distalization. The active treatment time was 13 months, but it appears that this case could have been finished much earlier if the unintended tipping and extrusion of canine had been prevented. The distalization of the canines was completed in 3-4 weeks, however, the majority of the treatment time was spent for the retraction of the remaining incisors. Therefore, the incisors need to be aligned and retracted simultaneously with the canine retraction, to minimize the treatment time. In this context, the cases with moderate to severe crowding that require minimal anterior retraction would be the best candidates for this rapid retraction protocol.

Although the vitality of the canines was maintained, as shown in previous cases,<sup>6</sup> it is not yet clear how the rapid retraction of the canines might affect the periapical nerves and blood vessels. A rationale for distraction has been that repeated distraction through a short distance at high frequency would be better for tissue remodeling, than distraction of greater distances at low frequency.<sup>9</sup> Previous reports have shown that even in the autotransplantation or replantation cases, pulpal nerves and blood vessels were occasionally regenerated, implying that the vitality of the pulp could be maintained by the anastomosis of the neurovascular tissues being supplied through various accessory canals as well as the main apical foramen.<sup>10-12</sup> Even some injury in the periapical tissue during distraction does not radically affect the vitality of the canines after treatment.

In the present case, the retraction of the mandibular canines appeared somewhat complicated. Probably it seems so because of incomplete bone removal around the apical area or due to the compact architecture of the

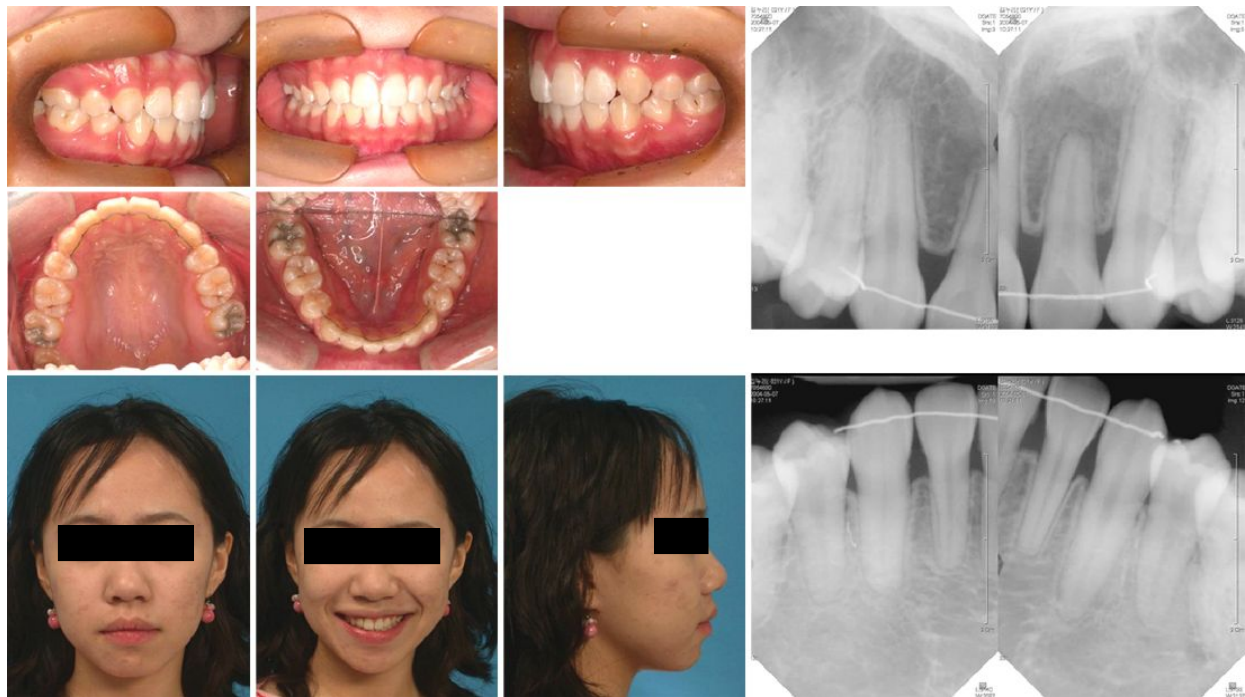

Fig 10. Facial and intraoral photographs and periapical X-rays at 10 months after debonding.

#13	Buccal	Lingual	#23	Buccal	Lingual
Probing	3 2 3	3 3 3	Probing	3 2 3	3 3 3
BOP		●	BOP		●
Cold	+	+	Cold	+	+
Mob	-	-	Mob	-	-
Per	-	-	Per	-	-
#43	Buccal	Lingual	#33	Buccal	Lingual
Probing	3 2 3	3 3 3	Probing	3 2 3	3 3 3
BOP	● ● ●	● ● ●	BOP	● ● ●	● ● ●
Cold	+	+	Cold	+	+
Mob	-	-	Mob	-	-
Per	-	-	Per	-	-

Fig 11. Endodontic and periodontal examination chart at 10 months retention. BOP, bleedings on probing; Cold, cold sensitivity; Mob, mobility; Per, percussion.

remaining bony plate which causes great resistance. Unless the unwanted displacement of the canines has been corrected at the very initial stage of retraction, healing of the extraction socket with a primary callus will take place in about 2 weeks. It will then reinforce the resistance to the movement of the canines.

Moreover, a constant distraction force will drive the clinical crown to move distally, while the apical portion is still held by the surrounding bone, worsening the tipping of its axis. Therefore, it is crucial to monitor the axis of the clinical crown as well as the remaining extraction space. Taking periapical x-rays at least once a week is also very helpful, in order to evaluate the architecture around the root apex. A more careful approach to the mandibular alveolar bone, than to the maxilla, is advised.

It is not yet clear if the mini-implants played a significant role in the reinforcement of anchorage in the present case. However, as shown in the superimposition, the anchorage loss was minimal. Further consideration is needed for better utilization of the mini-implant in the maximum anchorage cases.

The bulkiness of the appliance may cause discomfort and an unesthetic appearance. However, considering the short wearing time of at most 1 month and the remarkable progress in treatment, it is worthwhile to advise the patient to tolerate the discomfort. As for the unesthetic appearance, the lingually positioned

distraction screw is hidden in the palatal/lingual side, minimizing the exposure of the bulky screw during speech and smiling. Nonetheless, improvements in the appliance design is required to reduce discomfort.

## CONCLUSION

The philosophy of distraction osteogenesis can effectively be applied to orthodontic movement of the teeth, especially in bicuspid-extraction cases. In the present report, several modifications of the previous appliance design were introduced including the lingually extended screw, the resin models as root length indicators, the utilization of the surgical osteotome, the heavy labial guiding wires, and the reinforcement of anchorage using miniscrew implants. These concepts were efficiently applied to a clinical case displaying Class II pattern with bialveolar protrusion, successfully terminating the treatment in 13 months. Retention was satisfactory, with no significant pathologic change in the 10 months of retention.

## - 국문초록 -

### 제II급 치조 전돌 환자에서 설측 견인 장치를 이용한 금속 견치 견인술

안광석 · 주억 · 박주영 · 유영규 · 차인호 · 이기준

견인골 신장술의 개념을 치주인대 조직에 적용한 Liou의 금속 치아 이동 술식은 이동할 견치의 원심부 골 삭제에 의한 치조골 저항의 최소화 및 근심부의 치주조직 견인에 의한 골 형성으로 요약된다. 이는 주로 제1소구치 발치 후 견치의 견인을 요하는 환자들에 적용되어 효과적으로 치료 기간을 단축하고 양호한 결과를 얻을 수 있으나 견인 중 견치의 경사 및 정출 등 문제점이 발생하기 쉬우므로 견인이 완료될 때까지 치체이동을 유도하며 경로를 유지하는 것이 중요하다. 본 증례에서는 이러한 금속견인의 예측가능성을 높이기 위해 설측으로 연장된 견인스크류를 순측의 견고한 안내선과 병행 적용하였다. 발치 직후 미리 제작된 견치 치근 모델을 적용하여 발치와의 깊이를 형성하고 또한 고정용 미니스크류 임플란트를 이용하여 고정원을 보강하였다. 이러한 방법을 적용하여 골격성 II급 관계 및 전치 돌출을 보이는 성인 여환에서 효과적인 견치 및 전치부 견인을 통해 치료기간을 13개월로 단축할 수 있었다. 우려했던 치수의 실활 혹은 치주조직의 병소는 발견되지 않았으며 치료 후 10개월 유지 시에도 양호한 교합관계 및 치주조직의 건강상

태를 보였다. 본 증례에서 소개된 방법을 통하여 금속 견인을 필요로 하는 경우에 보다 예측 가능한 방법으로 효율적인 치료를 할 수 있을 것으로 사료된다.

**주요 단어:** 금속 견치 견인, 치주인대 신장술, 설측 연장 스크류, 전치 돌출

## REFERENCES

1. Proffit WR. Contemporary orthodontics. 3rd edition. St Louis: Mosby; 2000. p. 644-5.
2. Sergl HG, Klages U, Zentner A. Pain and discomfort during orthodontic treatment: causative factors and effects on compliance. Am J Orthod Dentofacial Orthop 1998;114:684-91.
3. Fink DF, Smith RJ. The duration of orthodontic treatment. Am J Orthod Dentofacial Orthop 1992;102:45-51.
4. Kole H. Surgical operations on the alveolar ridge to correct occlusal abnormalities. Oral Surg Oral Med Oral Pathol 1959;12:515-29.
5. Wilcko WM, Wilcko T, Bouquet JE, Ferguson DJ. Rapid Orthodontics with alveolar reshaping: Two case reports of decrowding. Int J Periodontics Restorative Dent 2001;21:9-19.
6. Liou EJ, Huang CS. Rapid canine retraction through distraction of the periodontal ligament. Am J Orthod Dentofacial Orthop 1998;114:372-82.
7. Bilodeau JE. Dental distraction for an adult patient. Am J Orthod Dentofacial Orthop 2003;123:683-9.
8. Liou EJW, Huang CS. Rapid canine retraction using distraction of the periodontal ligament. In: Samchukov ML, Cope JB, Cherkashin AM editors. Craniofacial distraction osteogenesis. St Louis: Mosby; 2001. p. 461-74.
9. Samchukov ML, Cope JB, Cherkashin AM. Biologic basis of new bone formation under the influence of tension stress. In: Samchukov ML, Cope JB, Cherkashin AM editors. Craniofacial distraction osteogenesis. St Louis: Mosby; 2001. p. 21-36.
10. Loescher AR, Holland GR, Robinson PP. The distribution and morphological characteristics of axons innervating the periodontal ligament of reimplanted teeth in cats. Arch oral Biol 1993;38:813-22.
11. Schendel KU, Schwartz O, Andreasen JO, Hoffmeister B. Reinnervation of autotransplanted teeth. A histologic investigation in monkeys. Int J Oral Maxillofac Surg 1990;19:247-9.
12. Skoglund A, Tronstad L, Wallenius K. A microangiographic study of vascular changes in replanted and autotransplanted teeth in young dogs. Oral Surg Oral Med Oral Pathol 1978;45:17-28.

## COMMENTARY

In this issue of the Korean Journal of Orthodontics, Ahn et al reported an 18-year-old adult case of Class II bimaxillary dentoalveolar protrusion treated with maxillary and mandibular rapid canine retractions. The maxillary and mandibular canines were successfully



retracted in 3 weeks, and subsequently the maxillary and mandibular incisors were successfully retracted with minimal loss of anchorage. The case was excellently finished in a pleasing and balancing facial profile and Class I occlusion in 13 months. The retraction results were stable, and the canines all remained vital with acceptable root resorption and probing depth 10 months after the treatment.

The authors have successfully demonstrated that the rapid canine retraction is a clinically feasible technique in accelerating orthodontic tooth movement and shortening the treatment duration, especially in adult patients with dentoalveolar protrusion. They also successfully demonstrated the philosophy of periodontal ligament distraction.

Since the introduction of rapid canine retraction in 1998,<sup>1</sup> many efforts and modifications<sup>2-8</sup> have been made accordingly to prevent the unwanted displacement during rapid canine retraction such as tipping, mesial-out rotation, and extrusion of the canine. These were mostly focused on the distraction devices, and the surgical technique in reducing the bony resistance from the interdental bone stock distal to the canine or the cortical bone plates mesial to the canine. Ahn et al also introduced their innovative modifications, including the lingually extended distraction screw (device), heavy labial guiding wire, the canine root resin model for indicating the root length of the maxillary or mandibular canines, Summers osteotome for avoiding maxillary sinus floor perforation, and the mini-implants for enhancing anchorage.

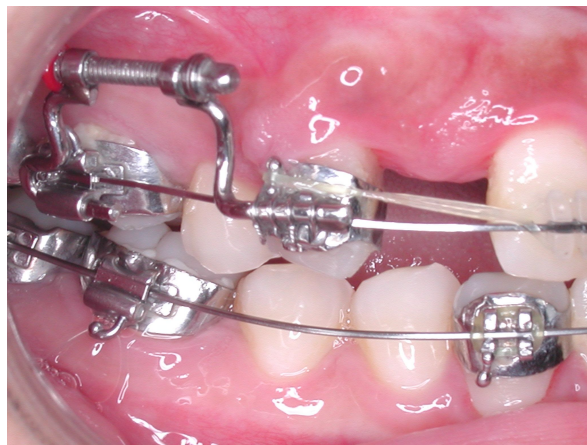One of the advantages of the lingually extended distraction device is avoidance of the mesial-out rotation of the canine, as it was revealed in this case report whose maxillary canines were labially blocked. This device was placed in a more apical position than the labial extended distraction devices<sup>1-8</sup> so that the vector of the distraction is closer to the center of resistance and has less tipping and extrusion of the canine. The maxillary canines were almost bodily retracted without extrusion in the case report. However, the mandibular canines were tipped and extruded during the retraction by the lingually extended device. The authors explained this was due to an incomplete bone

reduction of the bone stock at the apical area or a compact and thick cortical plate surrounding the mandibular canine. This could be also partly due to the anatomical fact, just like the labially positioned distraction devices, that the distraction device was not placed apical enough to the center of resistance of the mandibular canines. The other disadvantages of a lingually extended distraction device could be interference of swallowing, tongue movement, and speech, although the duration is short. However, the labially positioned distraction devices irritate the oral mucosa as well. The daily activation of the lingually positioned distraction device by the patient could be a problem.

The mechanics during rapid canine retraction of this case report was a segmental approach, except for the heavy labial guiding wire that is continuous arch wire. The heavy labial guiding wire is an innovation and has not been reported before. It worked as a second trail at the buccal side to keep the canines in the trough of the dentoalveolus during the rapid retraction. However, it may irritate the buccal mucosa, and fabrication of the labial guiding wire needs more laboratory work.

The authors also demonstrated the simultaneous relief of anterior crowding and retraction of the incisors by using a segmental arch wire and elastics on the incisors. However the segmental design may result in lingual tipping of the incisors that takes even more time and anchorage for the torque control. To be able to solve these problems mentioned above, a continuous arch wire with the labially positioned distraction device has been reported to solve the problems of mesial-out rotation, extrusion, and lingual tipping of incisors by Liou & Huang (Fig).<sup>7</sup> The labial continuous arch wire also is the second trail for the rapid canine retraction.

It has been well documented that the anchorage loss is minimal or even absent during the rapid canine retraction.<sup>1-7</sup> The use of mini-implants for the rapid canine retraction may not be necessary, but it makes sense for the subsequent anterior retraction.<sup>8</sup> After the rapid canine retraction, anchorage will move mesially while the anterior teeth are being retracted. For a severe dentoalveolar protrusion, I incorporate mini-implants as part of the treatment to ensure a greater amount of



**Fig.** Rapid canine retraction with a continuous arch wire and simultaneous anterior retraction developed by Liou.<sup>7</sup>

anterior retraction.

The canine root resin model for indicating the root length of the maxillary or mandibular canine is a brilliant innovation to ensure adequate and safe bone reduction for the bone stock distal and apical to the canine root. This is because the root length of the first premolar is always shorter than the canine and the bone stock distal and apical to the canine root has to be well reduced so that the canine can be retracted bodily with least bony resistance. The canine root resin model and the procedure of bone reduction were the most critical factors that affected the retraction results in this case report.

My personal experience in rapid canine retraction is that it is the bony resistance rather than the position of

the distraction device that ensures a bodily movement of the canine. It is the bony resistance which causes the canine to become tipped, rotated, and extruded. This is the reason why we see in the literature that the more extensive the bone reduction is the more the canine is retracted bodily and the shorter the period of retraction time is.<sup>1-7</sup> The rapid canine retraction is a "surgical-technique-sensitive" technique.

*Eric Jein-Wein Liou*

*Chang Gung Memorial Hospital Taipei, Taiwan*

## REFERENCES

1. Liou EJ, Huang CS. Rapid canine retraction through distraction of the periodontal ligament. *Am J Orthod Dentofacial Orthop* 1998;114:372-82.
2. Kisinisci RS, Iseri H, Tuz HH, Altug AT. Dentoalveolar distraction osteogenesis for rapid orthodontic canine retraction. *J Oral Maxillofac Surg* 2002;60:389-94.
3. Bilodeau JE. Dental distraction for an adult patient. *Am J Orthod Dentofacial Orthop* 2003;123:683-9.
4. Sayin S, Bengi AO, Gurton AU, Ortakoglu K. Rapid canine distalization using distraction of the periodontal ligament: a preliminary clinical validation of the original technique. *Angle Orthod* 2004;74:304-15.
5. Iseri H, Kisinisci R, Bzizi N, Tuz H. Rapid canine retraction and orthodontic treatment with dentoalveolar distraction osteogenesis. *Am J Orthod Dentofacial Orthop* 2005;127:533-41.
6. Bilodeau JE. Nonsurgical treatment with rapid canine retraction via periodontal ligament distraction in an adult with a Class III malocclusion. *Am J Orthod Dentofacial Orthop* 2005;128:388-96.
7. Liou EJ, Huang CS. Rapid canine retraction using distraction of the periodontal ligament. In: Samchukov ML, Cope JB, Cherkashin AM, editors. *Craniofacial distraction osteogenesis*. St Louis: Mosby; 2001. p. 461-74.
8. Bengi AO, Karacay S, Akin E, Olmez H, Okcu KM, Mermut S. Use of zygomatic anchors during rapid canine distalization: a preliminary report. *Angle Orthod* 2006;76:137-47.