Lateral Cephalometric Assessment in Patients with Condylar Resorption

Yun-Kyung Hur[1], D.D.S.,M.S.D., Hyo-Sang Park[2], D.D.S.,M.S.D.,Ph.D.
Jae-Kap Choi[1], D.D.S.,M.S.D.,Ph.D.

Department of Oral medicine[1], Department of Orthodontics[2],
School of Dentistry Kyungpook National University

Aims: The present study investigated the relationship between condylar resorption and craniofacial skeleton types (especially vertical relationships), the differences of craniofacial skeleton types between with open bite group and without open bite group, and the associations of anterior disc dislocation with or without reduction to condylar resorption with MRI.

Patients selection and methods: Clinical examination, magnetic resonance imaging (MRI), panorama, lateral transcranial and lateral cephalometric radiographs in 34 patients with condylar resorption were used to investigate this relationship.

Results and Conclusions: Patients with the following specific facial morphologic characteristics appear to be most susceptible to condylar resorption: (1) females were predominant, (2) patients' age ranged from 12 to 50 years old with a strong predominance for 2nd and 3rd decades, (3) patients had high mandibular plane angle and high gonial angle, (4) patients had decreased vertical height of the ramus, (5) patients had generally significant antegonial notch, (6) patients had predominance of Class I occlusal relationship with or without open bite but mandible was retruded as mean ANB 5.54 degrees, (7) condylar resorption rarely occurs in lower mandibular plane angle facial types, (8) although no statistically significant difference was found, the open bite group had a tendency more hyperdivergent skeletal pattern than the non open bite group, and (9) imaging demonstrates from small resorbing condyles to idiopathic condylar resorption and TMJ articular disc dislocations. Thus, morphologic features of patients with vertical discrepancies may represent a risk factor for the development of condylar resorption.

Key words : Condylar resorption, Open bite, Disc dislocation, Vertical discrepancy

Corresponding author : Prof. Jae-Kap Choi
Department of Oral Medicine, School of Dentistry, Kyungpook National University, Samduck 2 Ga, Jung-Gu, Daegu, 700-421, Korea
E-mail: jhchoi@mail.knu.ac.kr

received: 2006-08-30
accepted: 2006-10-26

* This research was supported by Kyungpook National University Research Fund, 2005.

I. INTRODUCTION

Condylar resorption including degenerative joint disease and idiopathic condylar resorption can be defined as alteration of condylar shape and decrease in mass. It is a poorly understood progressive disease affecting the TMJ result in malocclusion, facial disfigurement, TMJ dysfunction, and pain. Although the cause is unknown, condylar resorption has been associated with inflammatory disease such as rheumatoid arthritis[1-5] and can occur any time

when the joint is overloaded[6] and it has been commonly associated with disc dislocation[7,8] or perforation[9]. Tanaka and associates[10] investigated that stresses in the TMJ produced by clenching were substantially different from area to area and the compressive stresses were the greatest in the anterior and lateral areas of the TMJ. From a clinical aspect, deformations of the condyle such as erosion, flattening are usually observed in the anterior area of the condyle.

Tanne et al.[11] investigated stress distributions in the TMJ during clenching in patients with vertical skeletal discrepancies by finite element analysis, and described that stresses increased substantially for the condyle, the glenoid fossa, and the articular disc with greater gonial and mandibular plane angles, and those changes were more obvious in association with the divergent mandibular plane. Thus, they insisted the nature of stress distributions in the TMJ was substantially affected by vertical discrepancies of the craniofacial skeleton. From these findings, it is suggested that biomechanical changes from stresses may be associated with deformation of the hard and soft tissues in the TMJ.

However, the association of such skeletal discrepancies in the condylar resorption patients has been reported only in some patients[12] and only several parameters[13] were studied, but there was no statistical study to compare it with normal sample. The clinical research in this field is also deficient.

The purpose of this study was to investigate the associations of craniofacial skeleton types (especially vertical relationships) to condylar resorption by lateral cephalometric radiograph, the differences of craniofacial skeleton types between condylar resorption group with open bite and without open bite group, and the associations of anterior disc dislocation with or without reduction to condylar resorption with MRI.

Ⅱ. PATIENTS SELECTION AND METHODS

Retrospectively 34 consecutive patients who were treated at the Department of Oral Medicine of the Kyungpook National University Hospital, from July 2004 to July 2006 evaluated. Among the patients with condylar resorption, the only patients who had records of magnetic resonance imaging (MRI), panorama, lateral transcranial and lateral cephalometric radiographs were selected.

All patients had experienced common signs/symptoms of TMJ internal derangement. Although

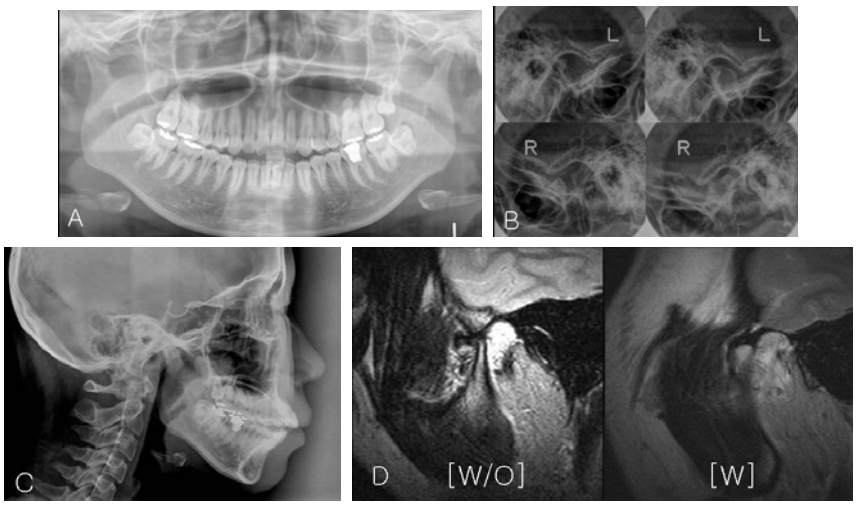

Fig. 1. A, Panoramic radiograph with condylar resorption; B, lateral transcranial radiograph; C, Lateral cephalometric radiograph; D, sagittal views of MRI on opening, ADD W/O R (anterior disc dislocation without reduction) and ADD W R (anterior disc dislocation with reduction) with condylar resorption

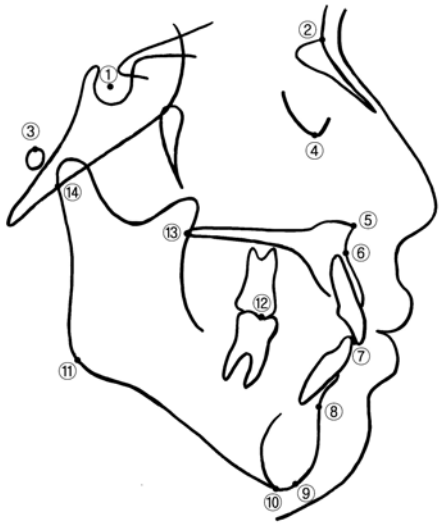

Fig. 2. Cephalometric landmarks and abbreviations: ① sella (S), ② nasion (N), ③ porion (Po), ④ orbitale (Or), ⑤ anterior nasal spine (ANS), ⑥ point A (A) ⑦ midpoint of incisor tip U1 and L1, ⑧ point B (B), ⑨ gnathion (Gn), ⑩ menton (Me); ⑪ gonion (Go); ⑫ occlusal surface L6; ⑬ posterior nasal spine (PNS); ⑭ articulare (Ar)

there were no laboratory tests specific for condylar resorption, but inflammatory signs, such as local heat, redness, or swelling, around the TMJs have not been observed clinically and other body joints are not involved. Therefore, our clinical impression of this patient population seemed to be different from those patients with inflammatory joint disorders such as rheumatoid arthritis.

Condylar resorption was first evaluated whether the diminished volume and irregularity of the condylar contour supported by panoramic and lateral transcranial radiographic examination were or not(Fig. 1A, 1B). Condylar resorption on the MRI[14] was defined by the presence of flattening, subchondral sclerosis, surface irregularities, and erosion of the condyle or presence of condylar deformities. Disc position on the MRI was also assessed at the anterior disk dislocation with or without reduction on opening (Fig. 1D).

Lateral cephalometric radiographs (Fig. 1C) were taken on all patients and traced. Cephalometric landmarks (Fig. 2), planes (Table 1) and angular and linear dimensions (Table 2) used in this study are listed. The recorded parameters were compared with established Korean adult mean normal values[15,16]. Condylar resorption group with open bite and non open bite group were also compared. Using the intraoral photographs and cephalometric radiographs, we analyzed the occlusal relationship according to Angle's classification.

Statistical analysis was performed using SPSS version 11.0. The t-test was used for comparison between patient group and normal group, between open bite patient group and non open bite group. A difference with a P value less than .05 was considered significant.

Ⅲ. RESULTS

The 34 patients for this study were selected. They consisted of 33 female and 1 male. The mean age was 23.5 years, with a range of 12 to 50 years. The

Table 1. Planes used in the study

1. Sella-nasion: the plane from sella to nasion
2. Frankfort horizontal plane: the plane from porion to orbitale
3. Palatal plane: the plane from anterior nasal spine to posterior nasal spine
4. Occlusal plane: the plane from occlusal surface of L6 molar to midpoint of incisor tip U1 and L1
5. Mandibular plane: the plane from menton and tangent to the lower border of the mandible
6. Nasion-point A: the line constrcted from nasion to point A
7. Nasion-point B: the line constrcted from nasion to point B
8. Articulare-gonion: the plane from articulare to gonion
9. Y-axis: the line from sella to gnathion

Table 2. Angular and linear dimensions used in the study

Angular dimensions
SNA: the angle between of the sella-nasion plane and the Nasion-A point line
SNB: the angle between of the sella-nasion plane and the Nasion-B point line
ANB: the angle between of the Nasion-A point and the Nasion-B point planes
Frankfort mandibular plane angle(FMA): the intersection of the FH and the mandibular plane
SN to mandibular plane angle: the intersection of the SN and the mandibular plane
FH to palatal plane angle: the intersection of the FH and the palatal plane
Maxillomandibular plane angle: the intersection of the palatal and the mandibular plane
Occlusal plane to mandibular plane angle: the intersection of the occlusal plane and the mandibular plane
Y-axis: the intersection of the FH and the sella-gnathion planes
Gonial angle: the intersection of the articulare-gonion plane and the mandibular plane
Linear dimensions
Total ant. facial height(N-Me)
Total post. facial height(S-Go)
Lower ant. facial height(ANS-Me)
ramus height(Ar-Go)
Mandibular body length(Go-Me)

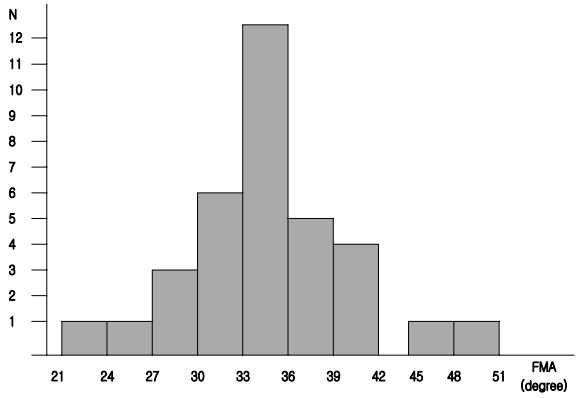

Fig. 3. The distribution of FMA (N: a number of patient)

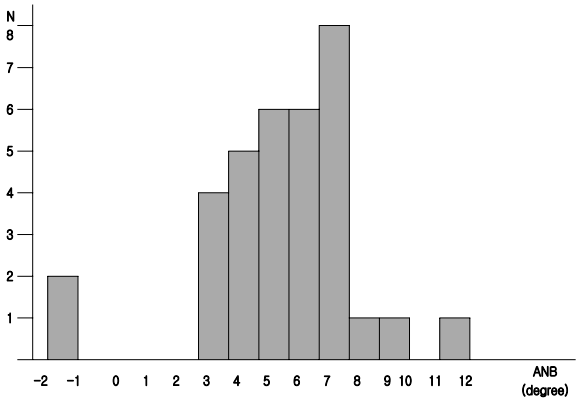

Fig. 4. The distribution of ANB (N: a number of patient)

distribution of age was as follows: (1) 13 patients were 2nd decades, (2) 16 were 3rd decades, (3) 3 were 4th decades, (4) 2 were 50 years old.

The finding of anterior disc dislocation with or without reduction in condylar resorption examined from MRI was as follows: (1) A number of condyles with resorption was 51 of 68 TMJs (34 patients), (2) 47 of 51 condyles had anterior disc dislocation without reduction (ADD W/O R) and 4 condyles had anterior disc lislocation with reduction (ADD W R), (3) A number of condyles without resorption among ADD W/O R was 8 and one showed perforation.

Lateral cephalometric radiographs of patients were recorded, parameters were compared with established Korean adult mean normal values[15,16] (Table 3). The all values except FH to palatal plane angle, total anterior facial height, and lower anterior facial height showed significant differences. The mean lower anterior facial height in patient group was larger than normal group, although significant relationship was not found.

The mean FMA, highly correlated to vertical growth, was 34.53°, with a range of 23° to 50°. The distributions of FMA are shown in Fig. 3. Patients

Table 3. Comparison of cephalometric variables of patients and normal mean values

Variables	Patients mean (S.D.)	Normal mean (S.D.)	p
SNA	80.47 (2.84)	82.05 (3.22)	*
SNB	74.92 (3.70)	79.79 (3.12)	**
ANB	5.54 (2.62)	2.26 (1.79)	**
FMA	34.53 (5.31)	23.50 (5.01)	**
SN to mandibular plane angle	43.70 (6.60)	31.80 (5.53)	**
FH to palatal plane angle#	1.16 (2.29)	1.05 (3.12)	NS
Maxillomandibular plane angle#	33.28 (5.41)	24.70 (5.60)	**
Occlusal plane to mandibular plane angle	19.80 (4.00)	15.19 (3.81)	**
Total ant. facial height	129.9 (6.67)	131.7 (7.08)	NS
Total post. facial height	77.01 (6.50)	90.24 (7.82)	**
Lower ant. facial height#	74.18 (4.65)	73.19 (5.14)	NS
Total post. facial height/Total ant. facial height(%)	59.36 (5.01)	68.52 (4.78)	**
Lower ant. facial height/Total ant. facial height(%)	57.10 (1.78)	55.54 (1.87)	**
Ramus height	43.71 (4.36)	54.61 (5.67)	**
Mandibular body length	76.48 (4.92)	80.19 (4.96)	*
Gonial angle	122.9 (6.22)	117.9 (6.38)	**
Y axis	65.51 (3.05)	61.36 (3.60)	**

normal mean : mean of Korean adult with normal occlusion[15,16]
#: comparison of longitudinal data of craniofacial growth from lateral cephalometrics in korean with normal occlusion[16]
NS: Not significant, *:$p<0.005$, **:$p<0.0001$

with FMA 33° to 36° were many as 12 cases, and low angle case was only one patient as 23°.

The mean ANB was 5.54°, with a range of -2° to 11.5°. The distribution of ANB are shown in Fig. 4. Patients with ANB 3° and over were 32 cases and mandibular protrusion patients as ANB -2° were two cases.

The patient group had decreased ratio of total posterior facial height/total anterior facial height(%) and also decreased ramus height.

The patients associated with open bite were 20 of 34 patients. Condylar resorption group with open bite and without open bite group were compared (Table 4). The patients with open bite had more increased FMA and decreased total posterior facial height/total anterior facial height(%) than non open bite group, although significant relationship was not found between two groups.

Analysis of the occlusal relationship in Angle's classification were Class I relationship predominantly; (1) 22 patients had both class I, (2) 4 patients had both Class II, (3) 4 patients had one side Class I and the other side Class II, (4) 4 patients had one side Class I and the other side Class III.

Ⅳ. DISCUSSION

Although progressive condylar resorption remains a poorly defined condition, as etiology of anterior disc displacement, Tanne et al.[11] investigated that

Table 4. Comparison of cephalometric variables of open bite patients (n=20) and non open bite (n=14) condylar resorption patients

Variables	open bite mean (S.D.)	non open bite mean (S.D.)	p
SNA	80.19 (2.82)	80.86 (2.92)	NS
SNB	74.54 (3.99)	75.47 (3.30)	NS
ANB	5.65 (2.68)	5.39 (2.62)	NS
FMA	35.23 (5.26)	33.52 (5.43)	NS
SN to mandibular plane angle	44.75 (6.56)	42.20 (6.60)	NS
FH to palatal plane angle	1.08 (2.18)	1.26 (2.51)	NS
Maxillomandibular plane angle	33.95 (5.77)	32.32 (4.92)	NS
Occlusal plane to mandibular plane angle	20.22 (3.62)	19.19 (4.55)	NS
Total ant. facial height	131.3 (6.45)	127.99(6.73)	NS
Total post. facial height	76.00 (6.18)	78.46 (6.90)	NS
Lower ant. facial height	74.80 (5.00)	73.30 (4.10)	NS
Total post. facial height/Total ant. facial height(%)	57.99 (4.91)	61.33 (4.62)	NS
Lower ant. facial height/Total ant. facial height(%)	56.97 (2.00)	57.28 (1.45)	NS
Ramus height	43.04 (4.17)	44.67 (4.60)	NS
Mandibular body length	77.38 (5.19)	75.20 (4.36)	NS
Gonial angle	122.3 (6.61)	123.7 (5.75)	NS
Y axis	65.55 (3.16)	65.46 (3.00)	NS

NS: not significant

the changes in compressive stresses were particularly greater at anterior surface of TMJ when the FMA became more than 36.5 degrees. So they suggested that the nature of stress distributions in the TMJ was substantially affected by vertical discrepancies of the craniofacial skeleton and these changes in stresses produce a lack of biomechanical equilibrium in the TMJ, which might have some association with temporomandibular disorders. Our sample had high mean FMA angle of 34.5 degrees and only one low angle patient with FMA as 23 degrees. This agrees with what Wolford and Cardenas[12] reported that idiopathic condylar resorption rarely occurs in low occlusal and mandibular plane angle facial types. An increase in physical stress (compressive stress) on the condyles in high mandibular plane angle cases is also assumed to be a factor of condylar resorption. In this concept, the greater high angle deficiency, the greater compressive stress at condyle (especially anterior surface), and the greater chance a disc dislocation and condylar resorption, because this may exceed that the normal adaptive capacity of the articular structures. When we compared to the normal group, the group of condylar resorption had the increased FMA and the decreased ratio of total posterior facial height/total anterior facial height(%), which contributed to more hyperdivergent skeletal pattern. The reports[17-22] stated that individuals with a vertical dysplasia of

the long-face type have considerably less occlusal force than individuals with normal vertical dentofacial proportions. In the long-face individuals, we thought that condylar resorption is a result shown by concentration of force and the occlusal force may not be well distributed rather than occlusal force and muscle force itself is strong.

In the studies by Wolford[12] and Huang[13], it was reported that patients with condylar resorption showed skeletal and occlusal Class II deformity. However, the results of occlusion analysis of our study indicate that Class I relationship was predominant, which is different from the finding of Wolford[12] and Huang[13], which could be explained by racial skeletal differences. That is, it might be attributed to the difference in which the caucasians tend to be Class II, while Asians are more of skeletal Class I with hyperdivergent tendency, so it is expected that condylar resorption are more found among Asians with a stronger tendency of vertical discrpancies than the Caucasians. The mean ANB of patients was 5.54 degrees, which means the retrusion of mandible.

Condylar resorption rarely occurs in low occlusal and mandibular plane angle. In actual clinical cases, disc dislocation is frequently discovered among Class II division I with low angle, but cases of condylar resorption are rarely reported. Therefore, we thought that the associations of craniofacial skeleton types and condylar resorption indicate that vertical relationships may be more important than horizontal relationships. As reason of patients with condylar resorption had a lot of Class II type facial morphology, we hypothesized if condylar resorptions are progressed from skeletal Class I with significant vertical growth, vertical height of the ramus will be decreased and mandible will be retruded, and resultantly it changes to Class II skeletal pattern. Thus morpology of Class II type may be many expressed by appearances. The occlusion may not represent skeletal pattern and the occlusion itself may not have close relationships with temporomandibular disorders. Therefore, we thought that estimation of skeletal pattern is needed.

The relationship between disc displacement and morphologic features of the face has been studied in the past[23-25]. Stringert and Worms[23] examined patients with clinically diagnosed internal derangement and reported an increase in the frequency of high plane angles and a decrease in the frequency of low plane angles in the experimental group. Muto et al.[24] assessed the relationship between disc displacement and facial morphologic features in 48 patients with skeletal Class III malocclusion. They suggested that patients with signs of disc displacement had a significantly larger gonial angle and/or sella nasion-mandibular plane angle. Nebbe et al.[25], in their study on adolescent girls, compared the craniofacial morphology of the normal disc position group with that of advanced bilateral TMJ disc displacement group, and reported that the group with bilateral total disc displacement exhibited an increased mandibular plane relative to sella-nasion and total posterior facial height and ramus height were reduced in the group whose disc is totally displaced. Our research results also agree with the findings of the previous studies on disc displacement and facial morphology.

The patients associated with open bite were 20 of 34 patients and no statistically significant difference was found between the open bite group and the non open bite group, but the mean FMA was higher in the open bite group; the mean values of total posterior facial height/ total anterior facial height(%) were lower. Therefore the open bite group had more hyperdivergent skeletal pattern than the non open bite group.

The FH to palatal plane angle did not have significant difference between condylar resorption patients and normal group, as well as between the open bite group and the non open bite group. In the open bite group, 4 out of 20 patients showed negative values; 3 out of 14 patients in the non open bite group showed negative values. The result of this study indicates that open bite is caused by vertical skeletal patterns of lower jaw rather than upper jaw.

The relationship between disc dislocation and condylar resorption has been studied[7,26]. Chen et al.[26] examined MRIs of the temporomandibular joints at 13 acquired open bite patients. They reported that all affected TMJs had anteriorly dislocation disc and degenerative changes. DE Bont et al.[7] found degenerative changes in 80% of the subjects with a dislocated disc in an autopsy study of an elderly population. We also investigated the associations of ADD W R or ADD W/O R in condylar resorption patients. From the results by use of MRI, a number of condyles with resorption was 51 of 68 condyles (34 patients) and 47 of 51 condyles had ADD W/O R and 4 condyles had ADD W R. This is strong evidence suggesting that internal derangements are often associated with condylar resorption of the TMJ, particularly in patients with nonreducing disc dislocation.

Only 1 out of 34 research subjects was man, with predominantly women in the group. From medical orthopedic viewpoint, we thought that this is consistent with the reason why temporomandibular disorders is more prevalent among women, and we presumed that it is caused by women's musculoskeletal weakness compared to men.

From these results, patients with the following specific facial morphologic characteristics appear to be most susceptible to condylar resorption: (1) females were predominant, (2) patients' age ranged from 12 to 50 years old with a strong predominance for 2nd and 3rd decades, (3) patients had high mandibular plane angle and high gonial angle, (4) patients had decreased vertical height of the ramus, (5) patients had generally significant antegonial notch, (6) patients had predominance of Class I occlusal relationship with or without open bite but mandible was retruded as mean ANB 5.54 degrees, (7) condylar resorption rarely occurs in lower mandibular plane angle facial types, (8) although no statistically significant difference was found, the open bite group had a tendency more hyperdivergent skeletal pattern than the non open bite group, and (9) Imaging demonstrates from small resorbing condyles to idiopathic condylar resorption and TMJ articular disc dislocations. Thus, morphologic features of patients with vertical discrepancies may represent a risk factor for the development of condylar resorption.

V. CONCLUSIONS

The 34 patients with condylar resorption were to investigated the associations of craniofacial skeleton types and condylar resorption by use of lateral cephalometric radiograph and the associations of anterior disc dislocation with or without reduction in condylar resorption patients by use of MRI.

Patients with the following specific facial morphologic characteristics appear to be most susceptible to condylar resorption: (1) females were predominant, (2) patients' age ranged from 12 to 50 years old with a strong predominance for 2nd and 3rd decades, (3) patients had high mandibular plane angle and high gonial angle, (4) patients had decreased vertical height of the ramus, (5) patients had generally significant antegonial notch, (6) patients had predominance of Class I occlusal relationship with or without open bite but mandible was retruded as mean ANB 5.54 degrees, (7) condylar resorption rarely occurs in lower mandibular plane angle facial types, (8) although no statistically significant difference was found, the open bite group had a tendency more hyperdivergent skeletal pattern than the non open bite group, and (9) Imaging demonstrates from small resorbing condyles to idiopathic condylar resorption and TMJ articular disc dislocations. Thus, morphologic features of patients with vertical discrepancies may represent a risk factor for the development of condylar resorption.

REFERENCES

1. Guyuron B. Facial deformity of juvenile rheumatoid arthritis. Plast Reconstr Surg 1988;81:948-95,
2. Marini I, Vecchiet F, Spiazzi L, Capurso U. Stomatognathic function in juvenile rheumatoid arthritis and in developmental open-bite subjects. ASDC J Dent Child 1999;66:12,30-35.

3. Harper RP, Brown CM, Triplett MM, Villasenor A, Gatchel RJ. Masticatory function in patients with juvenile rheumatoid arthritis. Pediatr Dent 2000;22:200-206,
4. Lanigan DT, Myall RW, West RA, McNeill RW. Condylysis in a patient with a mixed collagen vascular disease. Oral Surg Oral Med Oral Pathol 1979;48:198-204.
5. Haers and Sailer HF. Mandibular resorption due to systemic sclerosis: Case report of surgical correction of a secondary open bite deformity. Int J Oral Maxillofac Surg, 1995;24:261-267,
6. Stegenga B, de Bont LGM, Boering G. Osteoarthrosis as the cause of craniomandibular pain and dysfunction: a unifying concept. J Oral Maxillofac Surg 1989;47:249-256,
7. DeBont LGM, Boering G, Liem RSB, Eulderink F, Westesson PL et al. Osteoarthritis and internal derangement of the temporomandibular joint: a light microscopic study. J Oral Maxillofac Surg 1986;44: 634-643,
8. Mills DK, Daniel JC, Herzog S, Scapino RP. An animal model for studying mechanism in human temporomandibular joint disc derangement. J Oral Maxillofac Surg 1994;52:1279-1292.
9. Helmy E, Bays R, Sharawy M. Osteoarthrosis of the temporomandibular joint following experimental disc perforation in macaca fascicularis. J Oral Maxillofac Surg 1988;46:979-990,
10. Tanaka E, Tanne K, Sakuda M. A three-dimensional finite element model of the mandible including the TMJ and its application to stress analysis in the TMJ during clenching. Med Eng Phys 1994;16:316-322,
11. Tanne K, Tanaka E, Sakuda M. Stress distributions in the TMJ during clenching in patients with vertical discrepancies of the craniofacial complex. J of Orofacial Pain 1995;9:153-160,
12. Wolford LM, Cardenas L. Idiopathic condylar resorption: Diagnosis, treatment protocol, and outcomes. Am J orthod Dentofacial Orthop, 116:667-677, 1999.
13. Huang YL, Pogrel MA, Kaban LB. Diagnosis and management of condylar resorption. J Oral Maxillofac Surg 55:114-119, 1997.
14. Emshoff R, Brandimaier I, Bertram S, Rudisch A. Magnetic resonance imaging findings of osteoarthrosis and effusion in patients with unilateral temporomandibular joint pain. Int J Oral Maxillofac Surg, 2002;31:598-602.
15. Baek HS, Park YC, Sohn BH, Yoo YK. Cephalometrics. Seoul: Jee Sung Publishing 1999;193-210,
16. Sung JH, Kwon OW, Kyung HM, Park KD. Longitudinal data of craniofacial growth from lateral cephalometrics in Korean with normal occlusion. Seoul: Jung Won Publishing 2001.
17. Proffit WR, Fields HW. Occlusal forces in normal and long-face children, J Dent Res 1983;62(5):571-574.
18. Bakke M, Michler L. Temporalis and masseter muscle activity in patients with anterior open bite and craniomandibular disorders. Scand J Dent Res 1991;99:219-228.
19. Kayukawa H. Malocclusion and masticatory muscle activity: A comparison of four types of malocclusion. J Clinical Pediatric Dentistry 1992;16(3):162-177.
20. Udea HM, Miyamoto K, Tanne K. Relationship between masticatory muscle activity and vertical craniofacial morphology. The Angle Orthodontist 1998;68(3):233-238,
21. Raadsheer MC, van Eijden TMGJ, van Ginkel FC, Prahl-Andersen B. Contribution of jaw muscle size and craniofacial morphology to human bite force magnitude. J Dent Res 1999;78(1):31-42,
22. Tuxen A, Bakke M, Pinholt EM. Comparative data from young men and women on masseter muscle fibers, function and facial morphology. Archives of Oral Biology 1999;44:509-518,
23. Stringert HG, Worms FW. Variations in skeletal and dental patterns with structural and functional alterations of the temporomandibular joint: A preliminary report. Am J Orthod 1986;89:285-297,
24. Muto T, Kawakami J, Kanazawa M, Ishii H, Uga S, Yokoyama K, Takeuchi M. Relationship between disc displacement and morphologic features of skeletal Class III malocclusion. Int J Adult Orthodon Orthognath Surg 1998;13(2):145-151.
25. Nebbe B, Major PW, Prasad NG. Adolescent female craniofacial morphology associated with advanced bilateral TMJ disc displacement. Eur J Orthod 1998;20(6):701-712.
26. Chen YJ, Shih TTF, Wang JS, Wang HY, Shiau YY. Magnetic resonance images of the temporomandibular joints of patients with acquired open bite. Oral Surg Oral Med Oral Pathol Oral Radiol Endod 2005;99:734-42,

국문요약

과두흡수가 있는 환자의 측방 두부방사선 계측

경북대학교 치의학전문 대학원 구강내과학[1], 교정학[2]교실

허윤경[1] · 박효상[2] · 최재갑[1]

이 논문은 2년 동안 경북대학병원 구강내과를 턱관절 질환을 주소로 내원한 환자 중에 과두흡수가 있는 환자들로서 자기공명영상, 파노라마, 측방횡두개상 그리고 측방 두부방사선 사진들을 모두 촬영한 34명의 환자들만 선택하여, 측방두부방사선 계측으로 과두흡수와 안면부 골격형태의 연관성을 한국인 정상 교합자들의 평균치와 비교 조사하였고, 전치부 개교합이 동반된 군과 개교합이 없는 군을 서로 비교하였으며, 또한 자기공명영상으로 과두흡수와 관절원판변위와의 관련성을 조사한 결과 과두흡수가 잘 발생될 수 있는 환자들은 다음과 같은 특징을 가졌다: (1) 34명중 1명만이 남자로 여자가 대부분이었다, (2) 연령대는 어느 연령에서나 발생가능하나 10대와 20대에서 발병률이 높았다, (3) 환자들은 높은 하악하연각과 높은 하악각을 가졌다. (4) 하악지의 높이는 작게 나타났으며, (5) 전악각 함요(antegonial notch)가 대체적으로 저명하였다, (6) 구치부 교합은 Angle's Class I 관계가 많았으나, ANB각도는 평균 5.54도로 하악의 후퇴를 나타내었다. (7) 과두흡수는 하악하연각이 낮은 경우에는 거의 발생하지 않았다, (8) 통계학적 유의한 차이는 없었으나 개교합이 동반된 군이 개교합이 없는 군보다 hyperdivergent한 골격형태를 가졌다, (9) 자기공명영상사진에서 과두흡수는 대부분 비정복성 관절원판전위와 연관되어 있었다. 수직적 골격성장이 큰 경우 관절원판 전방변위와 과두흡수의 원인이 될 수 있으리라 생각된다.

주제어 : 과두흡수, 개교합, 관절원판전위, 수직적 골격성장