

## EXPRESSION OF P2X<sub>3</sub> AND ITS COLOCALIZATION WITH TRPV1 IN THE HUMAN DENTAL PULP

Young Kyung Kim, Sung Kyo Kim\*

*Department of Conservative Dentistry, School of Dentistry, Kyungpook National University, Daegu, Korea*

### ABSTRACT

The purinoreceptor, P2X<sub>3</sub> is a ligand-gated cation channel activated by extracellular ATP. It has been reported that ATP can be released during inflammation and tissue damage, which in turn may activate P2X<sub>3</sub> receptors to initiate nociceptive signals. However, little is known about the contribution of P2X<sub>3</sub> to the dental pain during pulpal inflammation. Therefore, the purpose of this study was to investigate the expression of P2X<sub>3</sub> and its colocalization with TRPV1 to understand the mechanism of pain transmission through P2X<sub>3</sub> in the human dental pulp with double labeling immunofluorescence method.

In the human dental pulp, intense P2X<sub>3</sub> immunoreactivity was observed throughout the coronal and radicular pulp. Of all P2X<sub>3</sub>-positive fibers examined, 79.4% coexpressed TRPV1.

This result suggests that P2X<sub>3</sub> along with TRPV1 may be involved in the transmission of pain and potentiation of noxious stimuli during pulpal inflammation. (J Kor Acad Cons Dent 32(6):514-521, 2007)

**Key words** : P2X<sub>3</sub> receptor, Immunofluorescence method, Human dental pulp, TRPV1, Transmission of pain

- Received 2007.8.14., revised 2007.9.30., accepted 2007.10.22.-

### 1. INTRODUCTION

Nociceptors express ion channels and receptors that respond to noxious stimuli and so are involved in the initiation of pain. Among several receptors, ATP purinoreceptor P2X<sub>3</sub> and Vanilloid

receptor TRPV1 are 2 key molecules in pain mechanism<sup>1,2)</sup>.

P2X<sub>3</sub> receptor is one of the many ligand-gated ion channels and is activated by extracellular ATP<sup>3)</sup>. To date, 7 P2X receptor subunits have been identified by molecular cloning. In particular, attention has focused on P2X<sub>3</sub> receptors because they are expressed selectively in a subset of sensory neurons which are potentially nociceptors<sup>4,5)</sup>. ATP is well recognized as an energy source and a modulator of cellular function. In the nervous system, ATP acts as a neurotransmitter and serves as a mediator of pain through binding to

---

\* Corresponding Author: **Sung Kyo Kim**

*Department of Conservative Dentistry,  
School of Dentistry, Kyungpook National University,  
Samduck 2ga, Jung-gu, Daegu, 700-422, Korea  
Tel: 82-53-420-5935 Fax: 82-53-426-8958  
E-mail: skykim@knu.ac.kr*

---

※ This work was supported by BioMedical Research Institute grant, Kyungpook National University Hospital (2006).

P2X<sub>3</sub> receptor. ATP can be released actively or passively by cell lysis during tissue damage, which in turn may activate P2X<sub>3</sub> receptors to initiate nociceptive signals. This effect may be exaggerated under conditions of inflammation<sup>6,7</sup>.

Many previous studies showed the expression of P2X<sub>3</sub> in the central and peripheral neurons<sup>1,4,8-10</sup>. In the orofacial region, it has been reported that P2X<sub>3</sub> immunoreactivity exists in dental pulp<sup>3</sup>, taste bud<sup>8</sup>, and temporomandibular joint<sup>11</sup> of the rat. The presence of P2X<sub>3</sub> in the human dental pulp was also documented in some studies<sup>12,13</sup>. The presence of P2X<sub>3</sub> in fibers of human dental pulp suggested that they may play a role in the perception of dental pain.

The vanilloid receptor TRPV1 is a marker of nociceptive primary afferent neurons. TRPV1 has been suggested as a molecular integrator of chemical and physical stimuli that elicit pain<sup>14</sup>. Functionally, TRPV1 is essential for the development and maintenance of thermal hyperalgesia and allodynia, which are associated with inflammation and tissue injury<sup>15</sup>. Previous studies showed the expression and potential role of TRPV1 in the human dental pulp<sup>12,16,17</sup>. It was suggested that TRPV1 may play an important role in neurogenic inflammation and pain transmission<sup>17</sup> and involved in inflammatory hyperalgesia and thermal nociception in the human dental pulp<sup>16</sup>.

Based on the contribution of P2X<sub>3</sub> and TRPV1 to pain mechanism, several studies were performed to investigate the coexpression of P2X<sub>3</sub> and TRPV1. However, they showed variable results. At the microscopic level, it was reported that many P2X<sub>3</sub>-positive cells coexpress TRPV1 in the dorsal root ganglion and trigeminal ganglion of the rat<sup>18</sup>. In this study, 75% of P2X<sub>3</sub>-positive neuron was costained with TRPV1 in the dorsal root ganglion, and 96% in the trigeminal ganglion. This result is inconsistent with that of other study showing that 35% and 9% of P2X<sub>3</sub>-positive neuron, respectively in the trigeminal ganglion and dental pulp of the rat, were costained with TRPV1<sup>19</sup>. It seems that a surprising feature of this result is that the coexpression of P2X<sub>3</sub> and

TRPV1 is rare in the dental pulp, peripheral terminal of trigeminal sensory system, while frequent in the trigeminal ganglion. It is also questionable that this result can be applicable to the human dental pulp. The coexpression pattern of P2X<sub>3</sub> and TRPV1 in the human dental pulp is still unknown.

Therefore, the aim of this study was to investigate the colocalization of P2X<sub>3</sub> and TRPV1 in the human dental pulp with double labeling immunofluorescence method.

## II. MATERIALS AND METHODS

### Tissue preparation

Human first or second premolars without caries, restorations or periodontal disease that had been extracted for orthodontic treatment were used in this study (n = 10). Subsequent to the extraction process within a time lapse of 1 hour, the teeth were split longitudinally with a water-cooled high speed diamond bur to take out pulp tissues. The tissues were post-fixed for 2 hours with 4% (w/v) paraformaldehyde in 0.1 M phosphate buffer, pH 7.4, and were cryoprotected in 30% sucrose in 0.1 M phosphate buffer, pH 7.4 overnight at 4°C. On the following day, cryoprotected pulp tissues were frozen on dry ice and 60 µm-thick sections were cut on a freezing microtome and the sections were immersed in 0.1 M phosphate buffer, pH 7.4.

### Double labeling fluorescence immunocytochemistry

All incubations for light microscopic immunocytochemistry were carried out on a shaker at room temperature. Sections of the tooth pulp were permeabilized with 50% ethanol for 30 min, blocked with 10% normal donkey serum for 30 min (Jackson Immunoresearch, West Grove, PA, USA) to mask secondary antibody binding site, and incubated overnight in primary antibodies in phosphate-buffered saline (0.01 M, pH 7.2). We used the following primary antibodies in double combinations: anti-P2X<sub>3</sub> (raised in rabbit; 1 :

7,000; Neuromics, Northfield, MN, USA), anti-TRPV1 (raised in goat; 1 : 700; Santa Cruz Biotechnology, Santa Cruz, CA, USA). After several rinses in phosphate-buffered saline (0.01 M, pH 7.2) and distilled water, and incubation with 2% normal donkey serum for 30 min, sections were transferred to a mixture of the secondary antibodies containing Cy3-conjugated anti-rabbit, fluorescence isothiocyanate-conjugated anti-goat (1 : 200; Jackson immunoresearch, West Grove, PA, USA) for 3 hr. After several rinses, sections were mounted on slides and dried in 50°C oven for 10 min. Sections were coverslipped with Vectashield (Vecta laboratories, Burlingame, CA, USA), and were examined on a confocal microscope (LSM 510 Meta, Carl Zeiss Inc., Germany). Confocal images were saved in TIFF format, contrast and brightness were adjusted, and final plates were composed using Photoshop software (version 7.0, Adobe Systems, San Jose, CA, USA). Control sections were processed as described above, except that primary or secondary antibodies were omitted or replaced by control antisera. Omission of primary or secondary antibodies eliminated a specific staining.

Colocalization of P2X<sub>3</sub> and TRPV1 was quantitatively analyzed. P2X<sub>3</sub> and TRPV1 immunoreactivities in nerve fibers were examined and quantified by computerized image analysis (*i*-solution, iMTechnology, Daejeon, Korea). Counts of P2X<sub>3</sub> immunopositive fibers were taken from the random fields (100 × 100 μm<sup>2</sup> in each field) of two or three areas in each section. In every image, the number of P2X<sub>3</sub>-positive fibers showing colocalization with TRPV1 was counted. Results were expressed as percentages of TRPV1-positive fibers to P2X<sub>3</sub>-positive fibers in given areas. Inter-teeth variability in the colocalization was insignificant and thus the data were pooled.

### III. RESULTS

P2X<sub>3</sub>-positive fibers were identified in the human dental pulp. Intense P2X<sub>3</sub> immunoreactivity was observed throughout the pulp. The distribution of P2X<sub>3</sub> immunoreactive nerve fibers in the

human dental pulp is shown in Figure 1. There was no apparent difference in the expression of P2X<sub>3</sub> in the central and peripheral portion of the pulp. Immunoreactive nerves were seen traveling in bundles throughout the bulk of the tissues (Figure 1B), sometimes accompanying blood vessels (Figure 1A).

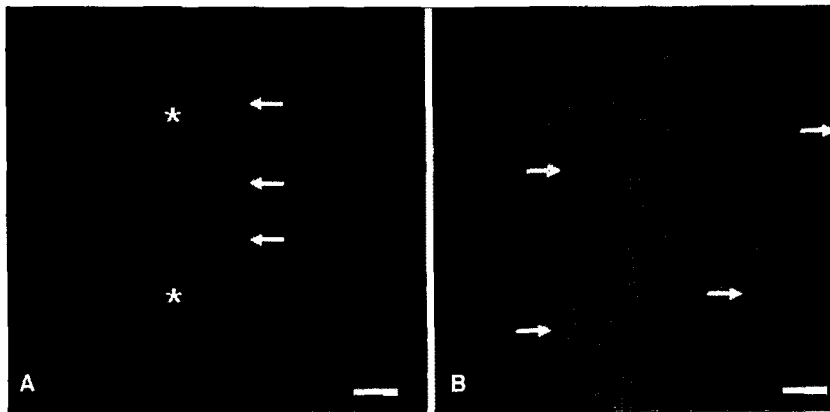
Double immunofluorescence revealed that P2X<sub>3</sub>-positive fibers were frequently costained with TRPV1 (Figure 2). There was no apparent difference between the central and peripheral portion of the pulp in the colocalization of P2X<sub>3</sub> with TRPV1. Of a total of 199 P2X<sub>3</sub>-positive fibers examined, 79.4% (158/199) coexpressed TRPV1. Only 20.6% (41/199) did not coexpress TRPV1. Figure 3 shows confocal micrographs presenting the nerve fibers stained for P2X<sub>3</sub> only.

### IV. DISCUSSION

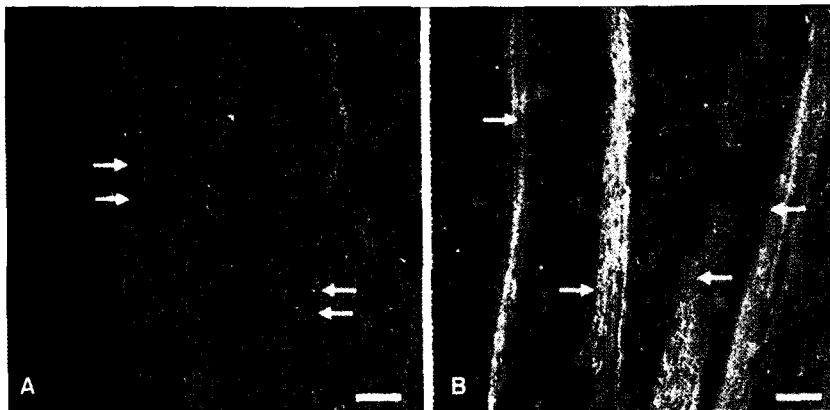
This study demonstrated that P2X<sub>3</sub> immunoreactivity is present in the human dental pulp and numerous P2X<sub>3</sub>-positive nerve fibers coexpress TRPV1.

Alavi et al.<sup>12)</sup> investigated the levels of the P2X<sub>3</sub> in the human dental pulp. They showed that intense P2X<sub>3</sub> immunoreactivity was observed in main body of the pulp, in the subodontoblastic plexus of Raschkow, and within the odontoblastic area. This observation is consistent with our finding showing Intense P2X<sub>3</sub> immunoreactivity throughout the pulp. However, Renton et al.<sup>13)</sup> reported that P2X<sub>3</sub> immunoreactive fibers were found throughout the pulp and the expression was weak. They attributed the differences of results to experimental design. They used peripheral subodontoblastic layer instead of densely innervated central area and that might account for some differences with the other results.

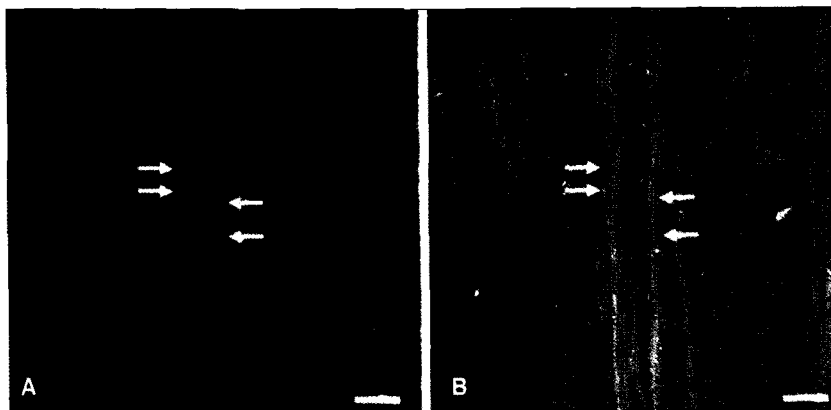
P2X<sub>3</sub> is expressed primarily in nociceptive afferent nerve terminals<sup>4,5)</sup> and they have small to medium-sized cell bodies in sensory ganglia<sup>18-20)</sup>. Earlier study demonstrated that P2X<sub>3</sub> receptors are present on both myelinated (A $\delta$ ) and unmyelinated (C) nerve fibers in the human dental pulp and may play a role in dental pain mechanism<sup>12)</sup>.



**Figure 1.** Photomicrographs of P2X<sub>3</sub> immunoreactive nerve fibers in the human dental pulp ( $\times 200$ ). **A** shows P2X<sub>3</sub> immunoreactive nerve fibers (arrows) accompanying blood vessel (asterisks) in the coronal pulp, and **B** shows P2X<sub>3</sub> immunoreactive nerve fibers (arrows) in the radicular pulp. Scale bars in A and B = 50  $\mu\text{m}$ .



**Figure 2.** Photomicrographs showing the colocalization of P2X<sub>3</sub> with TRPV1 ( $\times 200$ ). **A** and **B** show nerve fibers those are double stained with antibodies against P2X<sub>3</sub> (red), and TRPV1 (green). Scale bars in A and B = 50  $\mu\text{m}$ .



**Figure 3.** Photomicrographs showing the nerve fibers stained for P2X<sub>3</sub> only ( $\times 200$ ). **A** shows P2X<sub>3</sub> immunoreactive nerve fibers (arrows). **B** shows no double stained fiber at the same positions in A (arrows). Scale bars in A and B = 50  $\mu\text{m}$ .

Lesion study showed that P2X<sub>3</sub> immunoreactivity traffics both centrally and peripherally. As for the peripheral projections, P2X<sub>3</sub> immunoreactivity has been reported in fine unmyelinated fibers in tongue, viscera, tooth pulp and skin<sup>21</sup>. In the present study, P2X<sub>3</sub>-positive fibers were identified in the human dental pulp and intense P2X<sub>3</sub> immunoreactivity was observed throughout the pulp. This result is consistent with that of previous study by Renton et al.<sup>12</sup> and may indicate the possible role of P2X<sub>3</sub> in the human dental pulp.

In many previous studies on the expression of P2X<sub>3</sub>, normal tissues without inflammation were used and the role of P2X<sub>3</sub> was inferred from the results of the studies. It was also reported that the expression of P2X<sub>3</sub> is upregulated in the pathologic condition<sup>22,23</sup>. Thus, we used the healthy pulp tissue with the idea that the expression of P2X<sub>3</sub> itself in the healthy pulp would indicate the involvement of P2X<sub>3</sub> in pain transmission. And we found that it was very difficult to get proper stage of inflammation we want through the pilot study.

In the present study, majority of P2X<sub>3</sub>-positive nerve fibers also expressed TRPV1. However, in the previous study using temporomandibular joint of the rat, coexpression of P2X<sub>3</sub> and TRPV1 was abundant in facial skin and relatively rare (6%) in tooth pulp neuron<sup>19</sup>. In the trigeminal ganglion of the rat, a large number of P2X<sub>3</sub>-positive neuron (96%) also expressed TRPV1 and 92.9% of the P2X<sub>3</sub>-positive fibers were unmyelinated and 7.1% were myelinated in the sensory root just proximal to the trigeminal ganglion<sup>20</sup>. This discrepancy of coexpression pattern may reflect species difference (rat vs. human) and difference between peripheral and central distribution of these markers.

It is important that how we can apply these results to explain the mechanism of pain transmission. In our previous studies, we demonstrated that TRPV1 is expressed in human dental pulp and may be involved in pain transmission during pulpal inflammation<sup>16,17</sup>. On the ultrastructure of TRPV1-positive nerve terminals in the human dental pulp, there were two types of TRPV1

immunoreactive nerve fibers identified: one containing clear round vesicles and many dense-cored vesicles, the other containing clear round vesicles and few dense-cored vesicles. It is known that dense-cored vesicles contain neuropeptides such as substance P and calcitonin gene-related peptide, and clear round vesicles contain neurotransmitter such as glutamate<sup>24-26</sup>. In the previous study using human dental pulp, 40% of P2X<sub>3</sub>-positive nerve fibers were IB4-binding and non-peptidergic<sup>12</sup>. Moreover, P2X<sub>3</sub>-positive nerve fibers and terminals in the trigeminal sensory nuclei contained many clear, round, synaptic vesicles with few dense-cored vesicle<sup>27</sup>. From the described above, it is assumed that P2X<sub>3</sub> may present in the TRPV1-positive nerve fiber containing clear round vesicles and involved in pain transmission with similar mechanism of non-peptidergic TRPV1. When the stimulus is present, glutamate which is released from nerve ending binds glutamate receptor such as  $\alpha$ -amino-3-hydroxy-5-methyl-4-isoxazole-propionic acid (AMPA), N-methyl-D-aspartate (NMDA) receptor of adjacent nerve fibers. Consequently, it is thought that noxious stimulus is potentiated by release of glutamate from adjacent nerve ending simultaneously with transmission of stimulus centrally. On the other hand, peptidergic TRPV1 may be involved in sustained pain and hyperalgesia during pulpal inflammation. TRPV1-positive pulpal fibers activated by inflammatory mediators may release neuropeptides from their terminals through the axon reflex<sup>28</sup>. These neuropeptides induce vasodilation and increased capillary permeability, which in turn induce the release of inflammatory mediators such as bradykinin, histamine, prostaglandin E<sup>29</sup>. These cyclic processes may attribute to sustained pain and hyperalgesia during pulpal inflammation.

However, there are accumulating evidences demonstrating the direct involvement of P2X<sub>3</sub> in hyperalgesia and allodynia. Studies with antagonists selective for P2X<sub>3</sub>-containing receptor showed marked reduction in chronic inflammation induced by thermal<sup>30</sup> and mechanical<sup>31</sup> hyperalgesia, and spinal nerve ligation-induced mechanical

allodynia<sup>30</sup>). Moreover, it has been reported that nociceptive action of ATP are markedly augmented in the presence of inflammation or inflammatory mediators. Paukert et al.<sup>32</sup> showed that inflammatory mediator such as substance P and bradykinin potentiate the ATP-evoked currents in oocytes expressing P2X<sub>3</sub> by lowering the desensitization rate through phosphorylation of P2X<sub>3</sub>. Hamilton et al.<sup>7</sup> also reported that nociceptive action of ATP are markedly augmented in the presence of inflammation or inflammatory mediators and it was attributed that extracellular levels of ATP will reach levels capable of activating nociceptors in inflamed tissue. There are several ways in which the enhanced responses might arise. One possibility is changes in the pH of the extracellular environment, since there is ample evidence that pH can modify responses of P2X receptors when studied in culture. Inflammation can also be associated with tissue acidosis. Another possibility is that inflammatory stimuli might upregulate receptor levels in nociceptor. As a result, it is possible that P2X<sub>3</sub> can be directly involved in hyperalgesia and allodynia during pulpal inflammation. Therefore, further studies are needed to elucidate the specific role played by P2X<sub>3</sub> in the mediation of pain in the human dental pulp besides above explanation. In the present study, overall colocalization of P2X<sub>3</sub> and TRPV1 was investigated. However, no study was performed on the identification of the types of P2X<sub>3</sub> immunoreactive nerve fibers. The relative proportion of peptidergic and nonpeptidergic nerve fibers among P2X<sub>3</sub> immunoreactive nerve fibers coexpressing TRPV1 and the ultrastructural characteristics of P2X<sub>3</sub> immunoreactive nerve fiber through preembedding immunocytochemistry are also needed to elucidate the more detailed mechanism of pain transmission through P2X<sub>3</sub> receptor in the human dental pulp.

Taken together, our findings suggest that the expression of P2X<sub>3</sub> and frequent colocalization with TRPV1 in the human dental pulp may account for their important roles in pain transmission during pulpal inflammation.

## V. CONCLUSION

Based on the results of this study, P2X<sub>3</sub> immunoreactivity is present in the human dental pulp and numerous P2X<sub>3</sub>-positive nerve fibers coexpress TRPV1. It is suggested that P2X<sub>3</sub> along with TRPV1 may be involved in the transmission of pain and potentiation of noxious stimuli during pulpal inflammation.

## REFERENCES

1. Chen CC, Akopian AN, Sivilotti L, Colquhoun D, Burnstock G, Wood JN. A P2X purinoreceptor expressed by a subset of sensory neurons. *Nature* 377(6548):428-431, 1995.
2. Caterina MJ, Schumacher MA, Tominaga M, Rosen TA, Levin JD, Julius D. The capsaicin receptor: A heat-activated ion channel in the pain pathway. *Nature* 389(6653):816-824, 1997.
3. Cook SP, Vulchanova L, Hargreaves KM, Wide R, McClesky EW. Distinct ATP receptors on pain-sensing and stretch-sensing neurons. *Nature* 387(6632):505-508, 1997.
4. Dunn PM, Zhing Y, Burnstock G. P2X receptors in peripheral neurons. *Prog neurobiol* 65:107-134, 2001.
5. North RA, Surprenant A. Pharmacology of cloned P2X receptors. *Annu Rev Pharmacol Toxicol* 40:563-580, 2000.
6. Ding Y, Cesare P, Drew L, Nikitaki D, Wood JN. ATP, P2X receptors and pain pathway. *J Auton Nerv Syst* 82:289-294, 2000.
7. Hamilton SG, Wade A, McMahon SB. The effect of inflammation and inflammatory mediators on nociceptive behaviour induced by ATP analogues in the rat. *Brit J Pharmacol* 126:326-332, 1999.
8. Bo X, Alavi A, Xiang Z, Oglesby I, Ford A, Burnstock G. Localization of ATP-gated P2X<sub>2</sub> and P2X<sub>3</sub> receptor immunoreactive nerves in rat taste buds. *Neuroreport* 10(5):1107-1111, 1999.
9. North RA. P2X<sub>3</sub> receptors and peripheral pain mechanism. *J Physiol* 554(2): 301-308, 2003.
10. Liewellyn-Smith IJ, Burnstock G. Ultrastructural localization of P2X<sub>3</sub> receptors in rat sensory neuron. *Nueroreport* 9:2545-2550, 1998.
11. Ichikawa H, Fukunaga T, Jin HW, Fujita M, Takana-Yamamoto M, Sugimoto T. VR1- and VRL-1- and P2X<sub>3</sub> receptor-immunoreactive innervation of the rat temporomandibular joint. *Brain Res* 1008(1):131-136, 2004.
12. Alavi AM, DUBYAK GR, Burnstock G. Immunohistochemical evidence for ATP receptors in human dental pulp. *J Dent Res* 80(2):476-483, 2001.
13. Renton T, Yiangou Y, Baecker PA, Ford AP, Anand P. Capsaicin receptor VR1 and ATP Purinoreceptor P2X<sub>3</sub> in painful and nonpainful human tooth pulp. *J Orofac Pain* 17:245-250, 2003.
14. Tominaga M, Caterina MJ, Malmberg AB, Rosen TA, Gilbert H, Skinner K, Raumann BE, Basbaum AI, Julius D. The cloned capsaicin receptor integrates mul-

- tiple pain-producing stimuli. *Neuron* 21:531-543, 1998.
15. Davis JB, Gray J, Gunthorpe MJ, Hatcher JP, Davey PT, Overend P, Harris MH, Latcham J, Clapham C, Atkinson K, Hugfies SA, Rance K, Grau E, Harper AJ, Pugh PL, Rogers DC, Bingham S, Randall A, Sheardown SA. Vanilloid receptor-1 is essential for inflammatory thermal hyperalgesia. *Nature* 405:183-187, 2000.
  16. Kim YK, Ma SK, Jin MU, Kim SK, Bae YC. The ultrastructure of TRPV1-positive nerve terminals in the human tooth pulp. *The Korean J Anat* 39(4):297-303, 2006.
  17. Kim YK, Kim SK. Immunocytochemical study on the expression of TRPV1 in the human dental pulp. *The Journal of Korean Academy of Endodontics* 8(1):79-87, 2007.
  18. Guo A, Vulchanova L, Wang J, Li X, Elde R. Immunocytochemical localization of the vanilloid receptor 1 (VR1): relationship to neuropeptides, the P2X<sub>3</sub> purinoreceptor and IB4 binding sites. *Eur J Neurosci* 11:46-958, 1999.
  19. Ichikawa H, Sugimoto T. The co-expression of P2X<sub>3</sub> receptors with VR1 and VRL-1 in the rat trigeminal ganglion. *Brain Res* 998:130-135, 2004.
  20. Moon C, Bae JY, Paik SK, Heo JY, Yeo EJ, Kim SY, Ma SK, Whang SJ, Valtchanoff J, Moritani M, Yoshida A, Shigenaga Y, Bae Y. Expression of P2X<sub>3</sub> receptor in the trigeminal sensory nuclei of the rat. *Soc Neurosci Abstr* 50.3/J16, 2006.
  21. Bradbury EJ, Burnstock G, McMahon SB. The expression of P2X<sub>3</sub> purinoreceptors in sensory neurons: effects of axotomy and glial derived neurotrophic factor. *Mol Cell Neurosci* 12:256-268, 1998.
  22. Brady CM, Apostolidis A, Yiangou Y, Baecker PA, Ford AP, Freeman A, Jacques TS, Fowler CJ, Anand P. P2X<sub>3</sub>-immunoreactive nerve fibers in neurogenic detrusor overactivity and the effect of intravesical resiniferatoxin. *Eur Urol* 46:247-253, 2004.
  23. Eriksson J, Bongenhielm U, Kidd E, Matthews B, Fried K. Distribution of P2X<sub>3</sub> receptors in the rat trigeminal ganglion after inferior alveolar nerve injury. *Neurosci Lett* 254:37-40, 1998.
  24. Bae YC, Ihn HJ, Park MJ, Ottersen OP, Moritani M, Yoshida A, Shigenaga Y. Identification of signal substances in synapses made between primary afferents and their associated axon terminals in the rat trigeminal sensory nuclei. *J Comp Neurol* 418:299-309, 2000.
  25. Johnson MD, Yee AG. Ultrastructure of electrophysiologically-characterized synapses formed by serotonergic raphe neurons in culture. *Neuroscience* 67:609-623, 1995.
  26. Tachibana M, Wenthold RJ, Morioka H, Petralia RS. Light and electron microscopic immunocytochemical localization of AMPA-selective glutamate receptors in the rat spinal cord. *J Comp Neurol* 344:431-454, 1994.
  27. Jin YH, Bailey TW, Li BY, Schild JH, Andresen MC. Purinergic and Vanilloid receptor activation releases glutamate from separate cranial afferent terminals in nucleus tractus solitarius. *J Neurosci* 24(20):4709-4717, 2004.
  28. Kim S. Neurovascular interaction in the dental pulp in health and inflammation. *J Endodont* 16:48-53, 1990.
  29. Foreman JC, Jordan CC. Neurogenic inflammation. *Trends Pharmacol Sci* 5:116-119, 1984.
  30. Barclay J, Patel S, Dorn G, Wotherspoon G, Moffatt S, Eunson L, Abdel' al S, Natt F, Hall J, Winter J, Bevans S, Wishart W, Fox A, Ganju P. Functional downregulation of P2X<sub>3</sub> receptor subunit in rat sensory neurons reveals a significant role in chronic neuropathic and inflammatory pain. *J Neurosci* 22(8):8139-8147, 2002.
  31. Honore P, Mikusa J, Bianchi B, McDonald H, Cartmell J, Faltynek C, Jarvis MF. TNP-ATP, a potent P2X<sub>3</sub> receptor antagonist, block acetic acid-induced abdominal constriction in mice: comparison with reference analgesics. *Pain* 96:99-105, 2002.
  32. Paukert M, Osteroth R, Geisler HS, Brandle U, Glowatzki E, Ruppertsberg JP, Grunder S. Inflammatory mediators potentiate ATP-gated channels through the P2X<sub>3</sub> subunit. *J Biol Chem* 276:21077-21082, 2001.

**국문초록**사람치수에서 P2X<sub>3</sub>의 발현 및 TRPV1과의 공존에 관한 면역조직화학적 연구

김영경 · 김성교\*

경북대학교 치의학전문대학원 치과보존학교실

P2X<sub>3</sub> 수용기는 세포 외에 존재하는 ATP에 의하여 활성화되는 ligand-gated cation channel로서 염증 혹은 조직 손상 시 세포에서 유리된 ATP가 P2X<sub>3</sub> 수용기와 결합하여 동통을 유발하는 것으로 알려져 있다. 이에 본 연구는 형광면역조직화학적 방법을 통하여 사람의 치수에서 P2X<sub>3</sub>의 발현과 바닐로이드 수용기인 TRPV1과의 공존 양상을 확인함으로써 이들의 치수동통전달 기전을 밝히고자 시행되었다.

사람의 치수에서는 치관부 및 치근부 전체에 걸쳐 다수의 P2X<sub>3</sub> 면역양성 신경섬유가 관찰되었으며 이 중 약 79.4%에서 TRPV1과의 공존을 보였다. 이상의 결과로 사람의 치수에서 P2X<sub>3</sub>는 TRPV1과 더불어 치수염증 시 중추로의 동통전달과 유해자극의 증폭에 있어서 중요한 역할을 할 것으로 사료된다.

**주요어:** P2X<sub>3</sub> 수용기, 형광면역조직화학적 방법, 사람의 치수, TRPV1, 동통의 전달