

New maxillary anterior ridge classification according to ideal implant restorative position determined by CAT

Young-Sang Park¹, Sang-Choon Cho², Kyoung-Nam Kim¹, Kwang-Mahn Kim¹,
Seong-Ho Choi³, Hong-Seok Moon⁴, Yong-Keun Lee^{1*}

1. Department and Research Institute of Dental Biomaterials and Bioengineering, Yonsei University College of Dentistry
2. Department of Periodontology and Implant Dentistry, New York University College of Dentistry
3. Department of Periodontology, Yonsei University College of Dentistry
4. Department of Prosthodontics, Yonsei University College of Dentistry

I. INTRODUCTION

When considering the various modalities of treatment for the prosthetic replacement of teeth following tooth loss, the end goal of therapy is to provide a functional restoration that is in harmony with the adjacent natural dentition. To achieve this goal of therapy, it is desirable to provide treatment that will aim at preservation of the natural tissue contours in preparation for the proposed implant prosthesis¹⁾.

Implant therapy in the anterior maxilla is challenging for the clinician because of the esthetic demands of patients and difficult pre-existing anatomy. In this area of the mouth, the clinician is often confronted with

tissue deficiencies caused by various conditions. These conditions can be divided into 2 categories: anatomic and pathologic (Table 1)²⁾.

Several published reports classified ridge defects to help plan the treatment regimen for clinical correction. Seibert classified ridge deformities into three broad categories. A class I defect has bucco-lingual loss of tissue with normal ridge height in an apico-coronal direction. A class II defect has apico-coronal loss of tissue with normal ridge width in a bucco-lingual direction. A class III defect has a combination bucco-lingual and apico-coronal loss of tissue resulting in loss of height and width³⁾. Allen et al. proposed 3 different types of ridge deformities and also further described the ridge

* This study was supported by the Medical Science and Engineering Research Program of the Korea Science & Engineering Foundation (KOSEF) grant funded by the Korea government (MOST) (No. R13-2003-13).

* Correspondence: Yong-Keun Lee, Department of Dental Biomaterials and Bioengineering, Yonsei University College of Dentistry, 250 Seongsanno, Seodaemun-gu, Seoul 120-752 (E-mail: leeyk@yuhs.ac)

Table 1. Clinical conditions presenting tissue deficiencies in the anterior maxilla

Etiology	Conditions	Remarks
Anatomic	Narrow alveolar crest and/or facial undercut of alveolar process	Congenitally missing teeth
Pathologic	Dental trauma	Tooth avulsion with fracture of the facial bone plate
	Post traumatic conditions	Root ankylosis with infraocclusion, root resorption, root fractures
	Acute or chronic infections	Periodontal disease, periapical lesions, endo/periodontal lesions
	Disuse bone atrophy	Long-standing tooth loss

deformity by assessing the depth of the defect relative to the adjacent ridge⁴). Recently, Wang and Al-Shammari described a new system, HVC classification, which is a modification of Seibert's classification⁵). These H (horizontal), V (vertical), and C (combination) defects were subdivided into S (small), M (medium), and L (large) subcategories. They also described treatment options based on this HVC classification.

The advent and widespread use of dental implants mandated careful evaluation of available bony ridge volume and dimensions. Lekholm and Zarb's classification includes five stages of bone resorption, from minimal to severe⁶). Misch and Judy's classification describes four divisions of available bone with treatment options based on the amount of available bone height, width, and angulation⁷). Tinti and Parma-Benfenati introduced a clinical classification of bone defects. They focused on the "envelope of bone", or likelihood of the remaining bone housing protecting the organized blood clot. They assumed that the envelope of bone will direct

the treatment methods and be a significant factor in determining the prognosis for future site development to place implants. They categorized "the envelope of bone" into five categories: extraction wounds, fenestrations, dehiscences, horizontal ridge deficiencies, and vertical ridge deficiencies⁸). They also proposed treatment based on this classification.

To date, no published report has classified ridge deformities according to the position of the projected implant restoration. Currently, 3-dimensional radiographic images are available to evaluate hard tissue and to plan implant placement prior to surgery. Clinicians must focus on the 3D bone-to-implant relationship to establish the basis for an ideal and harmonic soft tissue situation that is stable over a long period. Furthermore, many authors discussed the importance of at least 2 mm of facial plate thickness⁹⁻¹⁰). When the facial plate is less than this critical thickness, the clinician may expect frequent and greater loss of vertical height of the facial plate.

The purpose of present study was to classify ridge deformities utilizing Computerized Axial Tomographic (CAT) scan images based on the ideal implant restorative position as determined by implant simulation.

II. MATERIALS AND METHODS

Clinical and CAT-scan data in this study were obtained from the Implant Dentistry Database (IDD) established at the Department of Periodontology and Implant Dentistry at New York University College of Dentistry (NYUCD). This data set was extracted as de-identified information from the routine treatment of patients. The IDD was certified by the Office of Quality Assurance at NYUCD. This study is in compliance with the Health Insurance Portability and Accountability Act requirements.

1. CAT-scans selection

CAT-scans were selected with the following criteria. One thousand and five hundred CAT-scans were screened. Fifty five cases satisfied the selection criteria. In these 55 subjects, 144 implant sites were evaluated.

- Only maxillary anterior missing teeth were included.
- At least two consecutive missing teeth were required.
- Images had to show at least one remaining anterior tooth, which was used as a guide for angulation.
- Radiographic templates used during tak-

ing of the CAT-scan were a prerequisite for this study.

- Unclear CAT-scan images were excluded from this study.

2. Characteristics of the measurements

All the measurements were performed and documented using CAT-scan software (Simplant 8.0, Materialise, Glen Burnie, MD, USA). In all CAT-scan images, one 3.25×10 mm parallel side simulated implant was positioned for every single edentulous area. Every simulated implant was placed in the ideal tooth position according to following protocol and without regard to the bone anatomy.

The implants were placed according to the tooth position outlined by the radiographic template. In the mesio-distal direction, the implants were placed according to the adjacent existing tooth position. In the bucco-lingual direction, the implants were placed using the adjacent existing tooth/teeth and the tooth position outlined by the radiographic template allowing a variation of long axis ending either in the incisal edges or the cingulum. In the apico-coronal direction, the implants were placed 3 mm below the buccal cemento-enamel junction (CEJ) of the tooth position outlined by the radiographic template.

III. RESULTS

A new proposed classification system was

Table 2. Proposed new classification system of ridge deformities

Class	Explanation
I-A	The implant is completely surrounded by bone. No dehiscence or fenestration present. ≥ 2 mm of facial plate of thickness.
I-B	The implant is completely surrounded by bone. No dehiscence or fenestration present. < 2 mm of facial plate of thickness.
II-A	Dehiscences are detected but no fenestrations are present. Only buccal or palatal dehiscence is present.
II-B	Dehiscences are detected but no fenestrations are present. Both buccal and palatal dehiscences are present.
III-A	Fenestrations are detected but no dehiscence is present. Only buccal or palatal fenestration is present.
III-B	Fenestrations are detected but no dehiscence is present. both buccal and palatal fenestrations are present.
IV	Both dehiscences and fenestrations are present.

categorized into seven classes from the results (Table 2).

When the implant was completely surrounded by bone without any dehiscence or fenestration, it was defined Class I. In case of Class I, when there was more than 2 mm of facial plate, it was categorized Class I-A. On the other hand, when there was less than 2 mm of that, it was designated Class I-B (Figure 1).

When dehiscences were detected without any fenestrations, it was defined Class II. Class II-A was designated when only buccal or palatal dehiscence was present (Figure 2). When both buccal and palatal dehiscences, however, were present, it was categorized Class II-B (Figure 3). When fenestrations were detected without any dehiscence, it was defined Class III. Class III-A and Class III-B were defined same as the classification

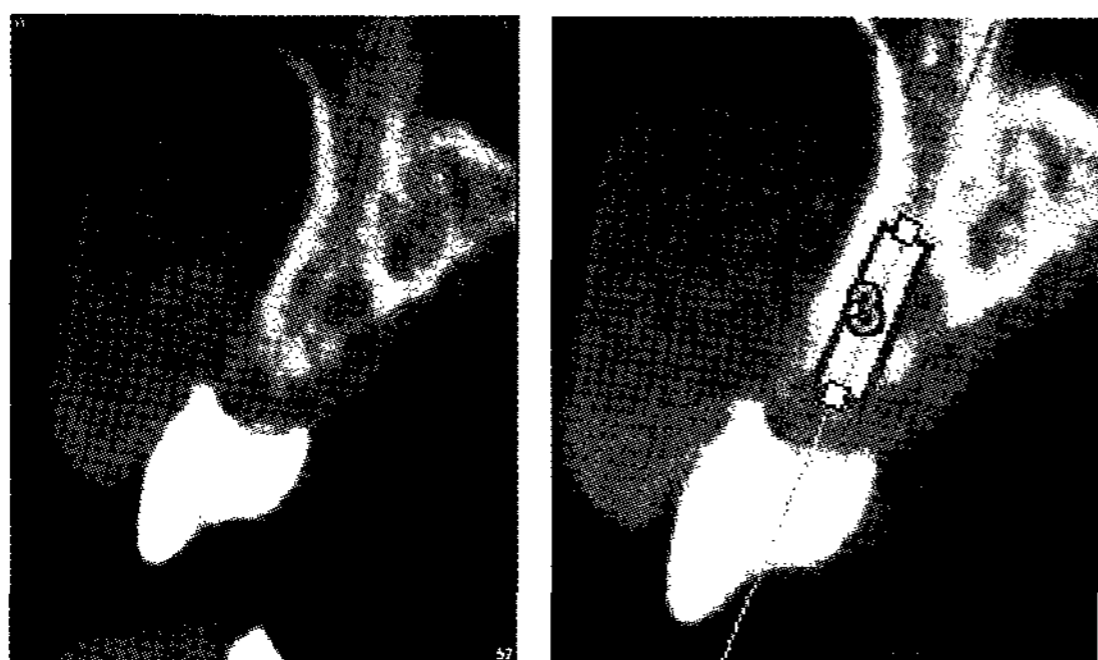


Figure 1. Implants were surrounded by bone, no dehiscence and no fenestrations (Class I).

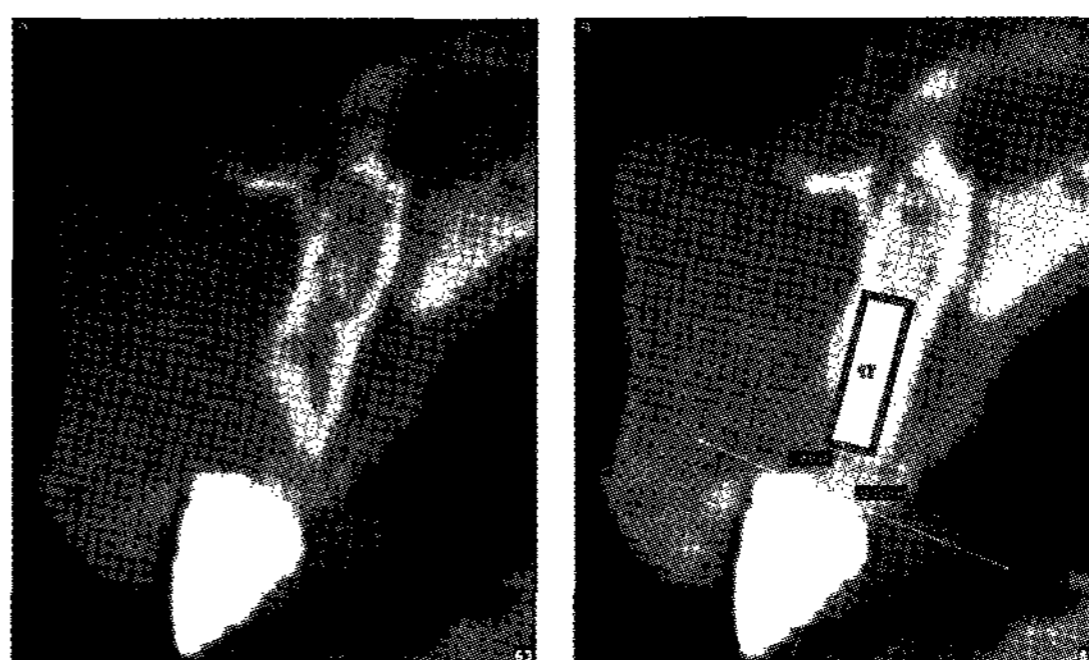


Figure 2. Dehiscence was detected but no fenestrations, only buccal or palatal dehiscence was noticed (Class II-A).

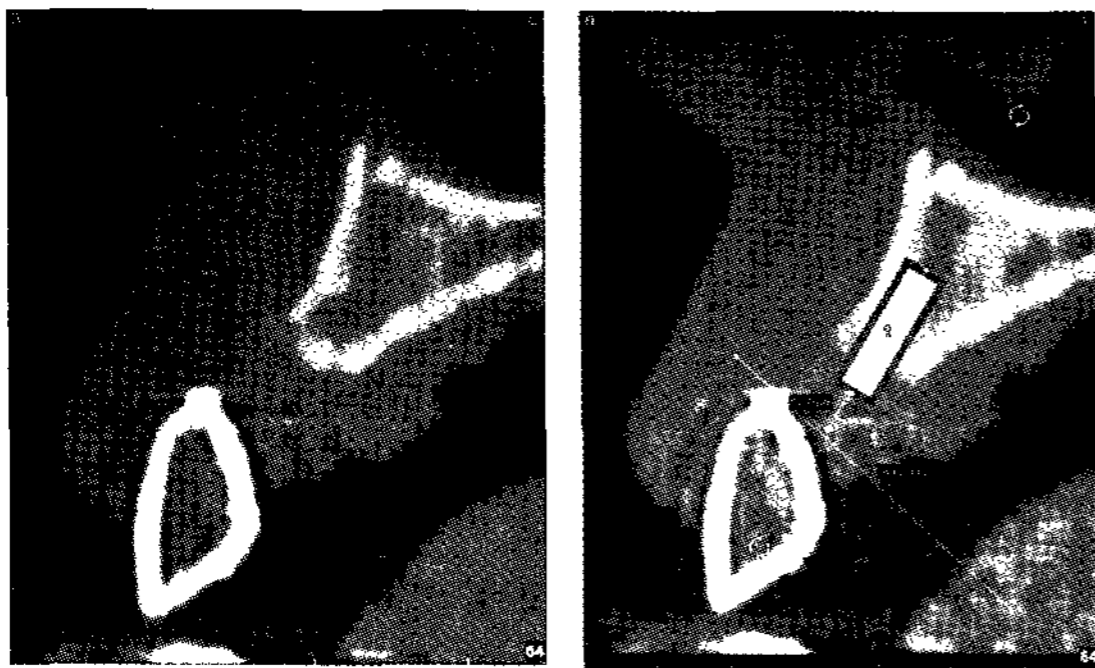


Figure 3. Dehiscence was detected but no fenestrations, both buccal and palatal dehiscence was noticed (Class II-B).

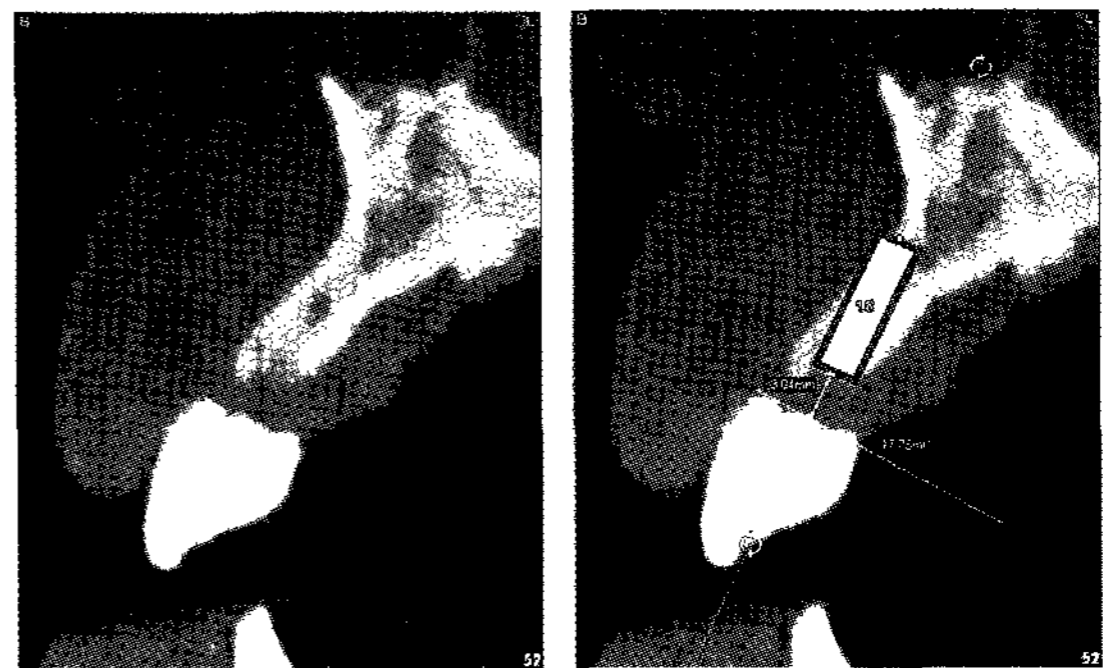


Figure 4. Fenestrations were detected but no dehiscence (Class III).

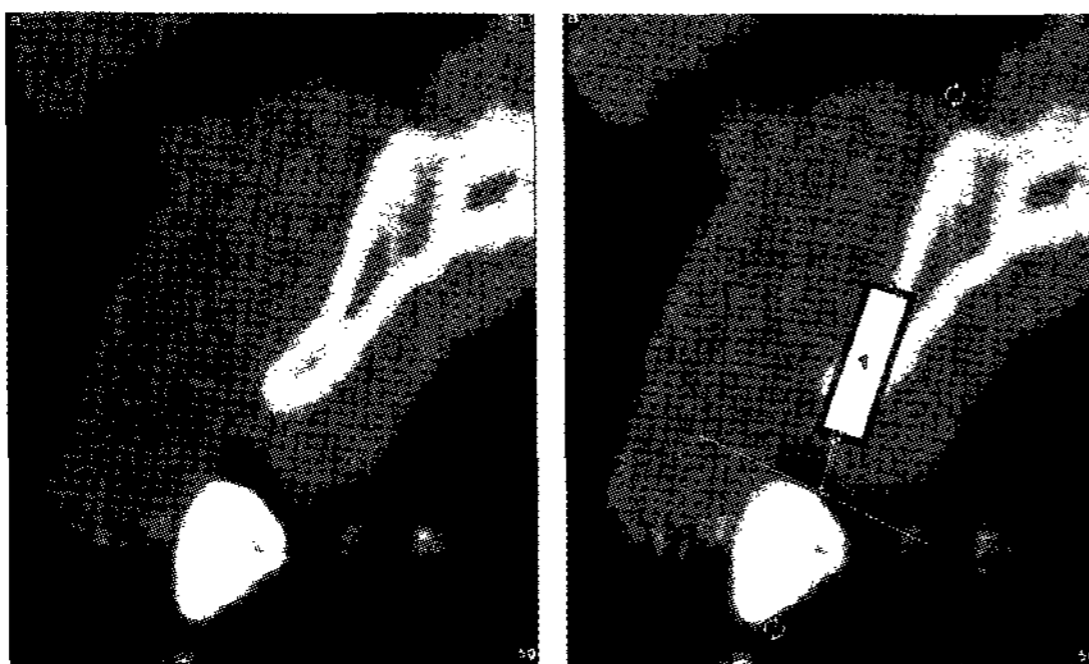


Figure 5. Both dehiscence and fenestrations were detected (Class IV).

of Class II-A and Class II-B (Figure 4). Class IV was defined when both dehiscences and fenestrations were present (Figure 5).

All 144 implants were shown as followed; 30.6 % of them was classified Class IV as the highest. The rest of them were shown in order of Class II-A, Class I-A, Class II-B,

Class I-B and Class III as 20.8 %, 19.4 %, 12.5 %, 10.4 % and 6.3 %, respectively (Table 3). Class IV was the highest in that ridge deformities were detected in their first medical examinations, so that the computer scanning was requested.

IV. DISCUSSION

The ultimate goal of implant treatment is to surgically place implants in the most desirable position compatible with esthetics, phonetics, and function. Identification of the “optimal final tooth position” allows the restorative dentist and surgeon to analyze the impact of pathologic alterations and to determine if soft or hard tissues need to be re-

Table 3. Distribution of ridge deformities of 144 CAT images

Class	Number	Rate (%)
I-A	28	19.4
I-B	15	10.4
II-A	30	20.8
II-B	18	12.5
III	9	6.3
IV	44	30.6

constructed to maximize function and esthetics¹¹⁾. The esthetic replacement of anterior teeth is a difficult challenge, especially in the maxillary arch. This situation can be further complicated by the presence of a ridge deformity. These anatomic defects may seriously compromise the esthetics of the final restoration. The defect should be carefully examined and classified before any attempt at restoration. The treatment modality used will depend to a great extent upon the type of deformity¹²⁾.

Alveolar ridge defects and deformities can be the results of trauma, periodontal disease, surgical treatment or congenital maldevelopment. Resorption after tooth loss has been shown to follow a certain pattern: the labial site of alveolar crest is primarily resorbed, which first reduces its width and later the height¹³⁻¹⁵⁾. Atwood described six residual alveolar ridge stages after tooth extraction, ranging from initial to severe ridge resorption. Longitudinal cephalometric studies have provided excellent visualization of the gross patterns of the bone loss¹⁶⁾.

Alveolar bone is resorbed after tooth extraction or avulsion most rapidly during the first years. Extraction of anterior maxillary teeth is associated with a progressive loss of bone mainly from the labial side¹⁵⁾. The loss is estimated to be 40~60 % during the first 3 years and decreases to 0.25~0.5 % annual loss thereafter¹⁷⁾. The cause for resorption of alveolar bone has been assumed to be due to disuse atrophy, decreased blood supply, localized inflammation or prosthesis pres-

sure¹⁸⁾.

The osseous topography of the anterior sextants, and their relation in space relative to the cranium, plays a leading role in shaping dentofacial aesthetics. In health, the alveolus in these regions not only serves as the foundation for the natural dentition and associated gingival tissues but is also responsible for supporting the lips as well as directly affecting the facial profile.

Much more prevalent in everyday practice are patients with normal skeletal pattern who have lost a substantial degree of their original osseous dimensions due to tooth loss or trauma. Reconstructing any resulting aesthetic deficiencies through purely prosthetic means often proves impossible or, at best, inadequate for patients with high smile lines and those demanding a fixed restorative option. If the fixed restoration is to be implant supported, reconstructing the deformed osseous ridge may be necessary to allow for functionally and esthetically oriented placement of the implants.

The minimal requirements for predictable success in implant therapy include an edentulous ridge that manifests an osseous dimension capable of fully housing the diameter of the fixture buttressed by 1mm of bone buccally and lingually. Although gingival augmentation procedures are capable of significantly enhancing soft tissue ridge profiles for conventional pontics in fixed prosthodontics, they are ineffective in preparing deficient osseous ridges for implant placement. If the potential implant receptor sites are thus

compromised, alternative osseous augmentation techniques need to be used.

Soft and hard tissue ridge deformities are prevalent in areas of tooth loss and trauma and significantly compromise aesthetics outcomes. Only a full understanding of the severity of the dimensional defects, the surgical techniques available and the aesthetic and functional needs of the final implant or fixed prosthetic restoration will allow the design of a treatment approach that will achieve the desired outcome¹⁹⁾.

Pre-operative estimation of the width and height of alveolar bone before implantation is important. Computerized tomography (CT) scans have been used in estimating bone quality and quantity before implantation and the gain of new bone in sinus floor augmentations as well as in integration of interpositional bone grafts. The analysis requires multiple thin axial CT slices through the jaws. The data obtained is reformatted with special software packages to produce cross-sectional and panoramic views²⁰⁾.

To achieve a long-lasting, ideal esthetic result with implants, in light of circumferential bone resorption that usually occurs as part of the healing response around the implant head, the thickness of the bone on the buccal side of an implant should be at least 2 mm¹⁰⁾. Having a facial bone wall of sufficient height and thickness is important for long-term stability of harmonious gingival margins around implants and adjacent teeth. Attempts to place implants in sites with facial bone defects in the absence of

reconstruction will frequently result in soft tissue recession, potentially exposing implant collars and leading to loss of the harmonious gingival margin.

Deficient alveolar crest width and /or facial bone atrophy require a bone augmentation procedure so that the implant can be positioned in a correct orofacial position. Depending on the extent and morphology of the bone defect, a simultaneous or staged approach is necessary. Clinical sounding and sophisticated radiographic techniques such as conventional tomograms, dental computerized tomograms (CTs) or volume CTs can assist in diagnosing deficiencies in this dimension²⁾.

The bone augmentation technique employed to reconstruct these different ridge defects is dependent on the horizontal and vertical extent of the defect. The predictability of the corrective reconstructive procedures is influenced by the span of the edentulous ridge and the amount of attachment on the neighboring teeth; typically, reconstructive procedures are less favorable in defects that exhibit horizontal and vertical components. The extent of the anticipated bone resorption varies between the mandible and maxilla and at sites within the arches²¹⁾.

Using the proposed new classification system, ridge classification of the bone defects may be identified and complications avoided due to more accurate treatment planning of implant size and position. The relationship between the adjacent teeth and bone can also be observed by utilizing the radiographic template, which was worn by the patient

when taking the CAT-scan.

The advantages of this new Implant Oriented Classification System (IOCS) include: 1) more accurate evaluation of the clinical situation prior to surgery to determine treatment options. 2) the ability to evaluate the need for hard tissue augmentation and simulate the necessary augmentation prior to surgery. 3) allowing selection of appropriate implant type and size before surgery. 4) using the radiographic template as a surgical guide. 5) ability to communicate with restorative dentists and patients concerning treatment procedures and the expected outcomes.

A 3.25×10 mm implant was selected as a guide implant for the new IOCS because, according to the literature, this is the smallest permanent implant with a high success rate^{22,23}). This study indicated that narrow-diameter implants used in the anterior region of the maxilla as support for single-tooth replacements show results that are comparable to standard-diameter implants placed the same region²²). The reason for the use of the smallest permanent implant in this study was to avoid any ridge augmentation procedures. A variety of successful grafting techniques have been developed, but they often require multiple surgical procedures and prolonged healing time.

Evaluation of a residual ridge deformity begins with the determination of the optimal final tooth position. An assessment of ridge alteration can only be made by completing a clinically tested diagnostic wax-up in which

the parameters of tooth size and coronal form have been established. Implant diagnostic methods using computed tomography with barium-coated templates have revealed the relationship between the optimal final tooth position and the residual alveolar process or ridge. This information can assist the implant team in the development of realistic treatment objectives and in more accurately addressing the needs and concerns of the patient during presurgical treatment planning¹¹).

The ideal implant position in this study was based on the radiographic template. The simulated implants were placed 3 mm below the ideal CEJ as determined from the wax-up and radiographic template in order to provide enough apicocoronal room for esthetic prosthetic replacement²).

The results reported in the present study revealed that 29.8 % of the deformities were classified as Class I. Almost 66 % of Class I deformities were classified as Class I-A. The remaining 34 % of the Class I defects would require some form of bone augmentation procedure for a successful long term prognosis. On the other hand 30 % of the deformities were classified as Class IV according to the CAT-scan simulation. This high number of Class IV deformities may be due to the fact that when these patients were evaluated at the time of intra-oral examination the treating clinician noting the ridge defect subsequently sent the patient for CAT-scan evaluation. Nevertheless, these findings indicate that a significant number of implant cases would require ridge augmenta-

tion for implant placement or a modification in the treatment plan which may preclude the use of an implant in these sites.

According to our IDD CAT-scan data, 81% (116 of the total 144) of the implant sites and 92.7% (51 of 55) of the cases studied were identified as requiring grafting procedures. This may be due to the pre-existing anatomy and ridge resorption pattern in the maxillary anterior area^{16,24}). However, deformities in the anterior part of the maxilla may be related to the tooth biotype, genetic disorders, trauma, iatrogenic damage of the bone, or other reasons independent of the maxillary resorption. The limited number of cases present in our study that did not require graft procedures with the 3.25 mm diameter template may be of importance for clinicians placing implants in the maxillary anterior area. Moreover, the use of conventional diameter implants would have resulted in a greater number of ridge defects and complications than that reported in the present study population. In addition this may have increased the number of patients with more advanced classifications of deformities. Based on the number of ridge deformity complications documented in the present study, a knowledge and training in procedures for ridge augmentation may be necessary for clinicians to obtain predictable results and manage surgical complications.

V. SUMMARY

This study proposed a new classification

system for maxillary anterior alveolar ridge deformities based on CAT-scan implant simulation as a useful concept in order to more precisely predict treatment outcomes and the necessity for ridge augmentation prior to implant placement. The results indicate that a high number of cases in the maxillary anterior area would require augmentation procedures in order to achieve ideal implant placement and restoration.

VI. REFERENCES

1. Tarnow DP, Eskow RN, Zamzok J. Aesthetics and implant dentistry. *Periodontol* 2000 1996; 11:85-94.
2. Buser D, Martin W, Belser UC. Optimising esthetics for implant restorations in the anterior maxilla: anatomic and surgical considerations. *Int J Oral Max Impl* 2004;19(suppl):43-61.
3. Seibert JS. Reconstruction of deformed, partially edentulous ridges, using full thickness onlay grafts. Part I. Technique and wound healing. *Comp Cont Educ Dent* 1983;4:437-453.
4. Allen EP, Gainza CS, Farthing GG, Newbold DA. Improved technique for localized ridge augmentation. A report of 21 cases. *J Periodontol* 1985;56:195-199.
5. Wang HL, Shammari KA. HVC ridge deficiency classification: a therapeutically oriented classification. *Int J Periodont Rest* 2002;22:335-343.
6. Lekholm U, Zarb GA. Patient selection and preparation. *Tissue Integr Prosthesis* 1985;1:199-209.
7. Misch CE, Judy KW. Classification of partially edentulous arches for implant dentistry.

- Int J Oral Impl 1987;4:7-13.
8. Tinti C, Parma-Benfenati S. Clinical classification of bone defects concerning the placement of dental implants. *Int J Periodont Rest* 2003;23:147-155.
 9. Spray JR, Black CG, Morris HF, Ochi S. The influence of bone thickness facial marginal bone response: stage 1 placement through stage 2 uncovering. *Ann Periodontol* 2000;5:119-128.
 10. Grunder U, Gracis S, Capelli M. Influence of the 3-D bone-to-implant relationship on esthetics. *Int J Periodont Rest* 2005;25:113-119.
 11. Meccall RA, Rosenfeld AL. Influence of residual ridge resorption patterns on fixture placement and tooth position, part III: Presurgical assessment of ridge augmentation requirements. *Int J Periodont Rest* 1996;16:323-337.
 12. Abrams H, Kopezyk RA, Kaplan A. Incidence of anterior ridge deformities in partially edentulous patients. *J Prothet Dent* 1987;57:191-194.
 13. Truhlar RS, Orenstein IH, Morris HF, Ochi S. Distribution of bone quality in patients receiving endosseous dental implants. *J Oral Max Surg* 1997;55:38-45.
 14. Atwood DA. Reduction of residual ridges in the partially edentulous patient. *Dent Clin North Am* 1983;17:747-754.
 15. Cawood JI, Howell RA. A classification of the edentulous jaws. *Int J Oral Max Surg* 1988;17:232-236.
 16. Atwood DA. Reduction of residual ridges: A major oral disease entity. *J Prothet Dent* 1971;26:266-279.
 17. Ashman A, Rosenlicht J. Ridge preservation: addressing a major problem in dentistry. *Dent Today* 1993;12:80-84.
 18. Ashman A. Postextraction ridge preservation using synthetic alloplast. *Impl Dent* 2000;9:168-176.
 19. Seibert JS, Salama H. Alveolar ridge preservation and reconstruction. *Periodontol* 2000 1996;11:69-84.
 20. Oikarinen KS, Sandor GKB, Kainulainen VT, Salonen-Kemppi M. Augmentation of the narrow traumatized anterior alveolar ridge to facilitate dental implant placement. *Dent Traumatol* 2003;19:19-29.
 21. McAllister BS, Haghghat K. Bone augmentation techniques. *J Periodontol* 2007;78:377-396.
 22. Andersen E, Saxegaard E, Knutsen BM, Haanaes HR. A prospective clinical study evaluating the safety and effectiveness of narrow-diameter threaded implants in the anterior region of the maxilla. *Int J Oral Max Impl* 2001;16:217-224.
 23. Lekholm U, Gunne J, Henry P et al. Survival of the Branemark implant in partially edentulous jaws: A 10-year prospective multicenter study. *Int J Oral Max Impl* 1999;14:639-645.
 24. Atwood DA, Coy W. Clinical, cephalometric, and densitometric study of reduction of residual ridges. *J Prothet Dent* 1971;26:280-295.

전산화단층영상을 이용한 이상적 임플란트 수복 위치에 따른 상악 전치부 치조제의 새로운 분류

박영상¹, 조상준², 김경남¹, 김광만¹, 최성호³, 문용석⁴, 이용근^{1*}

1. 연세대학교 치과대학 치과생체재료공학교실 및 연구소
2. 뉴욕대학교 치과대학 치주 및 임플란트과
3. 연세대학교 치과대학 치주과학교실
4. 연세대학교 치과대학 보철과학교실

손상된 부분 무치악제는 임플란트 식립에 많은 어려움을 야기한다. 이런 치조제의 손상은 외상성 발치, 안면 외상, 치근단 수술, 만성 치주염으로 인한 발거, 임플란트 실패 등에 기인하며, 특히 상악 전치부의 경우는 큰 좌절을 유발할 수 있다. 치조제 손상의 분류 및 임상 처리 방법에 대한 많은 보고가 있었으나, 수술에 앞서 방사선 영상을 통해 경조직을 평가하여 심미적이고 연조직과 조화로운 임플란트 시술을 위한 임플란트의 이상적인 수복 위치에 따른 분류법은 소개된 적이 없었다. 본 논문의 목적은 컴퓨터 단층촬영 분석을 이용하여 이상적 임플란트 수복위치에 따른 상악 전치부 치조제의 손상을 분류하고자 하는 것이다.

본 논문에서는 뉴욕대학교 치주·임플란트과의 데이터를 이용했으며, 다음 경우에 한하여 자료를 수집한 후, Siplant 8.0과 3.25(10 mm)의 가상 임플란트를 이용하여 55개의 증례를 통한 144개의 임플란트 수복 부위를 평가하였다.

- (1) 상실된 상악 전치부 증례만 포함
- (2) 최소 2개의 인접 치아가 상실된 증례
- (3) 원래의 치아 각도를 알 수 있는 최소 1개의 잔존 치아 존재
- (4) 치아외형 형판을 컴퓨터 단층 촬영시 착용

분석 결과, 2 mm 이상의 순측골을 가지며 열개나 창이 없는 경우를 제1군 A, 2 mm 이하의 순측골을 가지며 열개나 창이 없는 경우를 제1군 B, 한쪽 편의 열개를 가지고 있고 창은 없는 경우를 제2군 A, 협/설측 모두 열개를 보이며 창은 없는 경우를 제2군 B, 열개는 없고 한쪽 편의 창을 보이는 경우를 제3군 A, 열개는 없고 협/설측 모두 창을 보이는 경우를 제3군 B, 열개 및 창을 모두 보이는 경우를 제4군으로 분류하였다.

144개의 임플란트 수복 부위를 분류해보면, 제4군이 30.6 %로 가장 많았으며, 제2군 A가 20.8 %, 제1군 A가 19.4 %, 제2군 B가 12.5 %, 제1군 B가 10.4 %, 제3군이 6.3% 순이었다. 제4군이 가장 많은 것은 초진시 치조제 변형을 감지하여 컴퓨터 촬영을 의뢰했기 때문으로 여겨진다.

본 연구에서 사용한 임플란트보다 큰 일반적 크기의 임플란트 적용시 더 많은 숫자의 치조제 손상을 보일 것으로 예상되므로, 임상가들은 이런 손상된 치조제 증례에서도 좋은 예후를 보일 수 있도록 정확한 진단과 골 증대술과 같은 수술적 접근법에도 익숙해질 수 있도록 노력해야 할 것이다.