

## Clinical Article

Jong-Young Lee, M.D.

Moon-Kyu Kim, M.D.

Byung-Moon Cho, M.D.

Se-Hyuck Park, M.D.

Sae-Moon Oh, M.D.

Department of Neurosurgery  
College of Medicine  
Hallym University  
Kangdong Sacred Heart  
Hospital, Seoul, Korea

# Surgical Experience of the Ruptured Distal Anterior Cerebral Artery Aneurysms

**Objective :** Distal anterior cerebral artery (DACA) aneurysms are fragile and known to have high risks for intraoperative premature rupture and a relatively high associated morbidity. To improve surgical outcomes of DACA aneurysms, we reviewed our surgical strategy and its results postoperatively.

**Methods :** A total of 845 patients with ruptured cerebral aneurysms were operated in our hospital from January 1991 to December 2005. Twenty-three of 845 patients had ruptured DACA aneurysms which were operated on according to our surgical strategy. Our surgical strategy was as follows; early surgery, appropriate releasing of CSF, appropriate surgical approach, using neuronavigating system, securing the bridging veins, using temporary clipping and/or tentative clipping, meticulous manipulation of aneurysm, and using micro-Doppler flow probe. Twenty of 23 patients who had complete medical records were studied retrospectively. We observed the postoperative radiographic findings and checked Glasgow Outcome Scale score sixth months after the operation.

**Results :** Nineteen DACA aneurysms were clipped through a unilateral interhemispheric approach and one DACA aneurysm was clipped through a pterional approach. Postoperative radiographic findings revealed complete clipping of aneurysmal neck without stenosis or occlusion of parent arteries. In two patients, a residual neck of aneurysm was visualized. Seventeen patients showed good recovery, one patient resulted in moderate disability, while 2 patients died.

**Conclusion :** With our surgical strategy it was possible to achieve acceptable surgical morbidity and mortality rates in patients with DACA aneurysms. Appropriate use of tentative clipping, temporary clipping and neuro-navigating systems can give great help for safe approach and clipping of DACA aneurysm.

**KEY WORDS :** Distal anterior cerebral artery · Aneurysm · Subarachnoid hemorrhage · Interhemispheric approach · Neuro-navigating system.

## INTRODUCTION

Distal anterior cerebral artery (DACA) aneurysms are a particular group of the aneurysms involving the anterior circle of Willis. The incidence of this aneurysm has been estimated to be from 1.5 to 9.0% of all intracranial aneurysms based on a large series of reports cited in the literature<sup>3-5,11,14,17,18,21,24,28</sup>. These aneurysms are fragile, frequently rupture prematurely during exposure, and have a higher morbidity rate than expected from their angiographic appearance and location. These characteristics bring a considerable technical challenge to a neurosurgeon<sup>21</sup>. To assess the surgical outcomes of DACA aneurysms we reviewed our surgical results based on our surgical strategy.

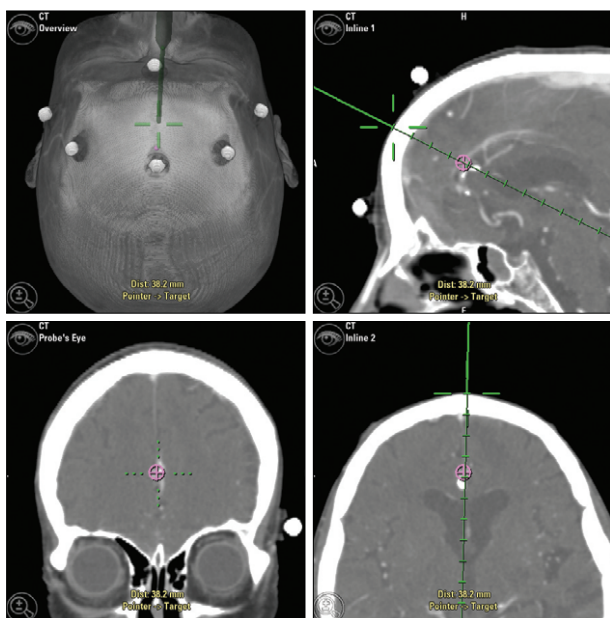
## MATERIALS AND METHODS

A total of 845 patients with ruptured cerebral aneurysms were operated in our hospital from January 1991 to December 2005. Twenty three (2.7%) of those 845 patients had ruptured DACA aneurysms. Among those 23 patients, 20 patients who had complete medical records were studied retrospectively. Data reviewed included the patient's age, gender, Hunt and Hess grade(H-H Gr.), Fischer grade, characteristics of the imaging study including multiplicity, operative data (surgical approach, premature rupture, temporary clipping, tentative clipping and use of micro-Doppler probe), postoperative complications and final radiographic and clinical outcomes.

### Surgical strategy

Our surgical strategy for DACA aneurysms involved early surgical intervention to prevent rebleeding and to cope with vasospasm aggressively. We routinely performed an external lumbar drainage of cerebrospinal fluid (CSF) to achieve a slack brain. Surgical approach was modified

• Received : May 28, 2007  
• Accepted : August 22, 2007  
• Address for reprints :  
Sae-Moon Oh, M.D.  
Department of Neurosurgery  
College of Medicine  
Hallym University  
Kangdong Sacred Heart Hospital  
445 Gil-dong, Gangdong-gu  
Seoul 134-701, Korea  
Tel : +82-2-2224-2236  
Fax : +82-2-473-7387  
E-mail : osm@hallym.or.kr



**Fig. 1.** The picture demonstrating how to decide upon a craniotomy site in order to gain a safe surgical corridor in patient with distal anterior cerebral artery aneurysm using a neuro-navigating system.

according to location and multiplicity of aneurysms. Pterional approach was selected in DACA aneurysm at the origin of the frontobasal artery, and a unilateral interhemispheric approach was chosen in DACA aneurysms at the origin of the callosomarginal artery. In cases with multiple aneurysms, unruptured aneurysms were treated with the second scheduled operation.

We used a neuro-navigating system in more recent cases to help deciding the proper craniotomy site to achieve a safe surgical corridor (Fig. 1). We attempted to preserve bridging veins during dissection to prevent venous infarctions. Temporary clipping of parent arteries, tentative clipping and meticulous manipulation of aneurysms were general practice guidelines to prevent premature rupture. We also used a micro-Doppler probe to confirm the patency of parent arteries after clipping of aneurysms.

**Evaluation of outcome**

To evaluate the outcome, we reviewed the postoperative radiographic findings with computerized tomographic angiography (CTA) and/or digital subtraction angiography (DSA) 1-2 weeks postoperatively. Patients were evaluated six months after the operation clinically with the Glasgow Outcome Scale score.

**RESULTS**

**Clinical characteristics**

Among the 20 patients who were included in the study, 15 patients (75%) were female and 5 patients (25%) were

**Table 1.** Clinical grades of 20 patients with distal anterior cerebral artery aneurysms

H-H Gr.*	No. of patient
I	3
II	9
III	3
IV	5

\*H-H Gr. : Hunt and Hess grade

male. The patients' age ranged from 41 to 80, with a mean age of 55.2. In this study, 15 patients were categorized with good grade (H-H Gr. I to III), and 5 patients were rated as H-H Gr. IV (Table 1).

**Radiographic features**

All patients had subarachnoid hemorrhage (SAH), while 3 patients (15%) had additional intracerebral hemorrhage (ICH) and 2 patients (10%) had additional intraventricular hemorrhage (IVH) on initial brain computerized tomography (CT) scan. There were 2 patients with hydrocephalus on initial brain CT scan.

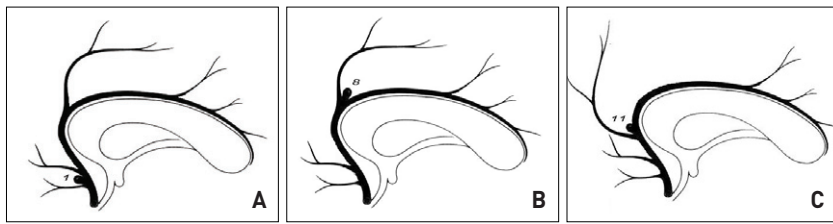
The size of aneurysms ranged from 2 mm to 15 mm, with a mean size of 6.3 mm. Seven patients (35%) had multiple aneurysms. Three patients had the left middle cerebral artery (MCA) bifurcation aneurysm, and 4 had the right MCA bifurcation aneurysm.

In 19 patients (95%), the DACA aneurysms were located at the origin of callosomarginal artery (left : 4 and right : 15) which were located at the supracallosal region (supracallosal type) in 8 patients (42.1%) and the infracallosal region (infracallosal type) in 11 patients (57.9%) (Fig. 2).

These 19 DACA aneurysms were clipped through a unilateral interhemispheric approach. One patient (5%) had a DACA aneurysm at the origin of the frontobasal artery and the aneurysm was clipped via a pterional approach.

**Surgical outcome**

Postoperative radiographic findings showed complete clipping of the aneurysmal neck in 18 patients (90%). However, a small residual aneurysmal neck was observed in 2 patients who had clipping and wrapping of aneurysms. There was no narrowing of parent arteries. In cases of multiple aneurysm, all 7 unruptured MCA aneurysms were clipped completely with second operation via pterional approach. Seventeen patients (85%) showed good recovery and 1 patient (5%) showed moderate disability, while 2 patients (10%) died (Table 2). In patients with preoperative good Hunt and Hess grade (H-H Gr. I to III), good results were seen in 100% of these patients. In the 5 patients with H-H Gr. IV who had SAH with ICH or IVH, 2 patients had full recovery, 1 patient showed moderate disability and



**Fig. 2.** Schematic representation of the location of a distal anterior cerebral artery aneurysm in 20 patients. A : Aneurysm located at the origin of the frontobasal artery. B : Aneurysms located at the origin of callosomarginal artery (supracallosal type). C : Aneurysms located at the origin of callosomarginal artery (infracallosal type).

**Table 2.** Clinical outcome of 20 patients with distal anterior cerebral artery aneurysms

H-H Gr.*	Glasgow outcome scale score				
	1	2	3	4	5
I	-	-	-	-	3
II	-	-	-	-	9
III	-	-	-	-	3
IV	2	-	1	-	2
Total	2	-	1	-	17

\*H-H Gr. : Hunt and Hess grade

2 patients died. The cause of death of the 2 patients was sepsis associated with pneumonia. There were no premature rupture of aneurysm, and no mortality and morbidity directly related to the aneurysmal surgery.

## DISCUSSION

The incidence of DACA aneurysms has been estimated to be from 1.5% to 9.0 % of all intracranial aneurysms based on the large series in the literature<sup>3-5,11,14,17,18,21,24,28</sup>. The average incidence of DACA aneurysms is 4.1% in the current Korean literature<sup>2,6,9,10,19,23</sup>. Incidence from our series was 2.7%. The smaller size of DACA aneurysms relative to more common aneurysms has been reported<sup>3-5,14</sup>. In our study, the mean diameter of ruptured DACA aneurysms was 6.3 mm, similar to previous reports. Several authors have reported high incidence of multiplicity of aneurysms associated with DACA aneurysm<sup>10,14,21</sup>. In our series, 7 patients (35%) had multiple aneurysms and all of them were middle cerebral artery bifurcation aneurysms. In previous reports, the patients with ruptured DACA aneurysms showed high incidence of having ICH<sup>11,20,25</sup>. The small pericallosal cistern and the intimate relationship of these aneurysms to the adjacent cerebral cortex would be plausible causes for the ICH formation<sup>21</sup>. In our series, 3 patients (15%) had ICH and all of them were in poor H-H Gr. and dismal surgical outcomes. Sindou et al.<sup>20</sup> reported that there was a high incidence of rebleeding compared to the aneurysms of other locations. Although we performed early surgeries in only 75% patients, there were no rebleedings in patients with delayed surgery. An attempt

was always made to perform surgery as early as possible to prevent rebleeding and to aggressively cope with vasospasm.

Surgical approaches of DACA aneurysms vary depending on the location and multiplicity of aneurysms. Various surgical approaches and their main indications have been discussed extensively in previous reports<sup>1-3,6,7,21,23,28</sup>. We

used the pterional approach in case of DACA aneurysm at the origin of the frontobasal artery and an interhemispheric approach in case of DACA aneurysm at the origin of the callosomarginal artery. There are some unique problems in the surgery of DACA aneurysms which make the surgery difficult. As Yasargil<sup>26,27</sup> indicated, a narrow surgical corridor in the interhemispheric fissure and callosal cistern and dense adhesions between the cingulate gyri are troublesome problems. Achieving a slack brain is mandatory and through external lumbar drainage it is possible to obtain adequate brain relaxation. Projection of aneurysmal dome toward the surgeon, broad-based and sclerotic aneurysm are additional troublesome problems which make it very difficult to establish proximal control especially infracallosal type of DACA aneurysm at the origin of callosomarginal artery. Treynelis and Dunker<sup>24</sup> proposed an interhemispheric approach with partial resection of the genu of the corpus callosum to get the proximal control more safely and easily. Previously, several authors have recommended an anterior interhemispheric approach or bifrontal basal anterior interhemispheric approach to get proximal control safely<sup>1,7,15</sup>. However, callosal resection may cause unexpected neurological problems and dissection of cortical adhesions in an anterior interhemispheric approach or a bifrontal basal anterior interhemispheric approach is very difficult and requires tedious work. To cope with these problems, we used tentative clipping of aneurysmal dome and/or parent artery without callosal resection when proximal control was difficult especially in patients with infracallosal type DACA aneurysms at the origin of the callosomarginal artery. After tentative clipping was done, we dissected proximally followed by proximal control of the DACA without risk of premature rupture of aneurysm. The clip was then readjusted properly after the proximal arterial clipping to get complete clipping of the aneurysmal neck. Absence of surgical landmarks is another problem intraoperatively. In this case, neuro-navigating system is very useful. In more recent series, we used the neuro-navigating system and found out very helpful to decide the appropriate site of craniotomy and to achieve a safe surgical corridor.

Sundt<sup>22</sup> reported that division of bridging vein anterior

to the coronal suture was of no consequence. However, Park and Hamm<sup>15)</sup> suggested that the operator who plans a DACA aneurysm surgery using an anterior interhemispheric approach should carefully consider the venous anatomy, its draining area and venous collateralization to prevent postoperative venous infarction when a bridging vein is sacrificed. Before we made a bone flap, we thoroughly reviewed both arterial and venous phases of cerebral angiography in an attempt to preserve bridging veins during dissection to prevent venous infarction.

With these surgical difficulties in mind, endovascular management of these aneurysms is appealing. In earlier series<sup>16)</sup>, the outcomes were unsatisfactory, while more recent investigators<sup>8,12)</sup> reported much higher rates of success.

Our surgical results are relatively satisfactory especially in the group of patients with good clinical grades when compared to the previous reports despite the difficulties associated with aneurysms in this location<sup>3-5,13,17,20,21,24,26)</sup>. We clipped the aneurysmal neck completely without a residual neck in 90% of patients. We observed a good recovery in 85%, moderate disability in 5% and a 10% mortality rate. Poor results were correlated to a poor preoperative clinical grade as previously reported by Miyazawa et al.<sup>13)</sup> Our 2 expired patients also had a poor clinical grade (H-H Gr.IV) and their causes of death were due to sepsis associated with pneumonia. Intraoperative premature rupture is a frequent complication in patients with DACA aneurysms and many papers reported relatively high incidence of premature rupture compared to the other supratentorial aneurysms<sup>4,13)</sup>. We did not have such complications and this might partially contribute to the good surgical outcome seen in our series. We think that using temporary clipping of parent arteries, tentative clipping and meticulous manipulation of aneurysms can help to prevent premature rupture.

## CONCLUSION

DACA aneurysms are known to have higher morbidity and mortality rates than other supratentorial aneurysms. With surgical strategies described, we have achieved acceptable surgical morbidity and mortality rates. Appropriate use of tentative clipping and temporary clipping can give great help for safe approach and clipping of DACA aneurysms. Use of a neuro-navigating system is recommended to facilitate a safe operation of DACA aneurysms.

## References

1. Chhabra R, Gupta SK, Mohindra S, Mukherjee KK, Bapuraj R, Khandelwal N, et al : Distal anterior cerebral artery aneurysm : bifrontal basal anterior interhemispheric approach. *Surg Neurol* 64 : 315-320, 2005
2. Choi HK, Lee SH, Lee KS, Ko KC, Chung UW, Park SW : Clinical features and surgical results of distal anterior cerebral artery aneurysm.

3. de Sousa AA, Dantas FL, de Cardoso GT, Costa BS : Distal anterior cerebral artery aneurysms. *Surg Neurol* 52 : 128-136, 1999
4. Hernesniemi JA, Tapaninaho A, Vapalahti MP, Niskanen M, Kari A, Luukkonen M : Saccular aneurysms of the distal anterior cerebral artery and its branches. *Neurosurgery* 31 : 994-999, 1992
5. Inci S, Erbenli A, Ozgen T : Aneurysms of the distal anterior cerebral artery : Report of 14 cases and a review of the literature. *Surg Neurol* 50 : 130-140, 1998
6. Kang TH, Sung JN, Kim YJ, Cho MK : Surgical treatment of distal anterior cerebral artery aneurysms. *J Korean Neurosurg Soc* 27 : 1379-1384, 1998
7. Kawashima M, Matsushima T, Sasaki T : Surgical strategy for distal anterior cerebral artery aneurysm : microsurgical anatomy. *J Neurosurg* 99 : 517-525, 2003
8. Keston P, White PM, Horribine L, Sellar R : The endovascular management of pericallosal artery aneurysms. *J Neuroradiol* 31 : 384-390, 2004
9. Kim SB, Yi HJ, Kim JM, Pak KH, Kim CH, Oh SJ : Surgical clues of distal anterior cerebral artery aneurysms. *J Korean Neurosurg Soc* 29 : 1555-1562, 2000
10. Lee SH, Han DH : Microsurgical treatment of distal anterior cerebral artery aneurysm. *J Korean Neurosurg Soc* 20 : 41-48, 1991
11. Mann KS, Yue CP, Wong G : Aneurysms of the pericallosal-callosomarginal junction. *Surg Neurol* 21 : 261-266, 1984
12. Menovsky T, van Rooij WJ, Sluzewski M, Wijnalda D : Coiling of ruptured pericallosal artery aneurysms. *Neurosurgery* 50 : 11-15, 2002
13. Miyazawa N, Nukui H, Yagi S, Yamagata Z, Hirokoshi T, Yagishita T, et al : Statistical analysis of factors affecting the outcome of patients with ruptured distal anterior cerebral artery aneurysms. *Acta Neurochir (Wien)* 142 : 1241-1246, 2000
14. Ohno K, Monma S, Suzuki R, Masaoka H, Matsushima Y, Hirakawa K : Saccular aneurysms of the distal anterior cerebral artery. *Neurosurgery* 27 : 907-913, 1990
15. Park J, Hamm IS : Anterior interhemispheric approach for distal anterior cerebral artery aneurysm surgery : preoperative analysis of the venous anatomy can help to avoid venous infarction. *Acta Neurochir (Wien)* 146 : 973-977, 2004
16. Pierot L, Boulin A, Castaings L, Rey A, Moret J : Endovascular treatment of pericallosal artery aneurysms. *Neurol Res* 18 : 49-53, 1996
17. Proust F, Toussaint P, Hannequin D, Rabenoina C, Le Gars D, Freger P : Outcome in 43 patients with distal anterior cerebral artery aneurysms. *Stroke* 28 : 2405-2409, 1997
18. Royand F, Carter L, Guthkelch A : Distal anterior cerebral artery aneurysms, in Carter L, Spetzler RF, Hamilton M (eds) : *Neurovascular Surgery*. New York, McGraw-Hill, pp717-728, 1995
19. Shim CS, Lim YJ, Kim TS, Kim GK, Lee BA, Leem W : Ligation of anterior superior sagittal sinus in approaching distal anterior cerebral artery aneurysm. *J Korean Neurosurg Soc* 23 : 1019-1027, 1994
20. Sindou M, Pelissou-Guyotat I, Mertens P, Keravel Y, Athayde AA : Pericallosal aneurysms. *Surg Neurol* 30 : 434-440, 1988
21. Steven DA, Lownie SP, Ferguson GG : Aneurysms of the distal anterior cerebral artery : Results in 59 consecutively managed patients. *Neurosurgery* 60 : 227-234, 2007
22. Sundt Jr TM : Pericallosal artery, in Sundt Jr TM(ed) : *Surgical techniques for saccular and giant intracranial aneurysms*. Baltimore : Williams & Wilkin, pp173-178, 1990
23. Sung KH, Doh JO, Kang JK, Kim KU : Surgical management of the distal anterior cerebral artery aneurysms. *J Korean Neurosurg Soc* 19 : 785-790, 1990
24. Traynelis VC, Dunker RO : Interhemispheric approach with callosal resection for distal anterior cerebral artery aneurysms. *J Neurosurg* 77 : 481-483, 1992
25. Wisoff JH, Flamm ES : Aneurysms of the distal anterior cerebral artery and associated vascular anomalies. *Neurosurgery* 20 : 735-741, 1987
26. Yasargil MG : Distal anterior cerebral artery aneurysms, in Yasargil MG (ed) : *Microneurosurgery*. Stuttgart, Georg Thieme Verlag, Vol 2, pp224-231, 1984
27. Yasargil MG, Carter LP : Saccular aneurysms of the distal anterior cerebral artery. *J Neurosurg* 40 : 218-223, 1974
28. Yoshimoto T, Uchida K, Suzuki J : Surgical treatment of distal anterior cerebral artery aneurysms. *J Neurosurg* 50 : 40-44, 1979

## COMMENTARY

The authors' experiences of the distal anterior cerebral artery aneurysms, which are relatively infrequent, representing approximately 2~5% of all intracranial aneurysms, can be useful to other young neurosurgeons in the management the patients with these aneurysms. Among the surgical strategies presented in this paper, the use of neuronavigation may be helpful, especial for young neurosurgeons with relatively less experience, in planning the craniotomy site and locating the aneurysm during surgical approach. Surgery of these aneurysms should be performed within limited space and also with less anatomical land marks until pericallosal arteries are visualized, and the neuronavigation can help neurosurgeons to determine the direction of approach with ease and certainty. In the stage of planning surgery, if the bridging veins draining into superior sagittal sinus are visualized, the craniotomy site can be designed more precisely with neuronavigation.

Neurosurgeons with more experience, however, naturally will have less demand for the help of neuronavigation.

This paper describes well the routine surgical procedure for these aneurysms, especially maneuvers to get as much space as possible, such as use of hyperosmolar agents and lumbar CSF drainage. For cases in which limited surgical space are expected, such as severe brain swelling, endovascular therapy may considered as an alternative way of management.

Chang Wan Oh, M.D.  
Department of Neurosurgery  
Seoul National University

## References

1. Kim TS, Joo SP, Lee JK : Neuronavigation-assisted surgery for distal anterior cerebral artery aneurysm. *Minim Invasive Neurosurg* 50 : 77-81, 2007
2. Proust F, Toussaint P, Hannequin D : Outcome in 43 patients with distal anterior cerebral artery aneurysm. *Stroke* 28 : 2405, 1997