

Carpal Bone Segmentation Using Modified Multi-Seed Based Region Growing

Kyungmin Choi^{1,2}, Sungmin Kim^{1,2}, Young Soo Kim^{1,3}, In Young Kim², Sun Il Kim²

¹Center for Intelligent Surgery System,

²Department of Biomedical Engineering,

³Department of Neurosurgery, School of Medicine, Hanyang University

(Received March 19, 2007. Accepted May 8, 2007)

Abstract

In the early twenty-first century, minimally invasive surgery is the mainstay of various kinds of surgical fields. Surgeons gave percutaneously surgical treatment of the screw directly using a fluoroscopic view in the past. The latest date, they began to operate the fractured carpal bone surgery using Computerized Tomography (CT). Carpal bones composed of wrist joint consist of eight small bones which have hexahedron and sponge shape. Because of these shape, it is difficult to grasp the shape of carpal bones using only CT image data. Although several image segmentation studies have been conducted with carpal bone CT image data, more studies about carpal bone using CT data are still required. Especially, to apply the software implemented from the studies to clinical field, the outcomes should be user friendly and very accurate. To satisfy those conditions, we propose modified multi-seed region growing segmentation method which uses simple threshold and the canny edge detector for finding edge information more accurately. This method is able to use very easily and gives us high accuracy and high speed for extracting the edge information of carpal bones. Especially, using multi-seed points, multi-bone objects of the carpal bone are extracted simultaneously.

Key words : multi-seed based region growing, Carpal bone image segmentation

I. INTRODUCTION

A. Background

The segmentation of anatomic structures from radiography as a part of the process of diagnosis and surgical planning has become an issue in these days. Anatomic objects need to be visualized in order to assist accurate diagnosis, surgical planning in preoperative time and operation in intraoperative time. As the target objects which are extracted from 3D volume data are displayed distinguishably from normal objects with 3D modeling technique, surgeons can look around the lesion as if real part of patient. This procedure helps diagnoses and operations more accurate. The studies using 3D model for diagnosis, surgical planning and surgical navigation are increased steadily [1-2].

There are many kinds of bone surgery. All of these surgeries, carpal bone fracture surgery is one of the most difficult operations. This is the reason why we choose carpal bones as the target application of our practical method. In order to plan for carpal bone fracture surgery, image segmentation is essential procedure. But because carpal bones have very complex structure and each carpal bone is adjacent very closely, segmentation of each bone object is very difficult and challenging process. And also each bone has similar intensity values and the boundaries are ambiguous caused by image blurring, which make the segmentation more complicate (Figure 1).

Current commercial surgical planning systems offer auto-contouring options and contour interpolation between slice, these tools have significant limitations such as low accuracy. The manual based segmentation also has limitation which is repetitive, tedious, and time-consuming.

For this reason, we develop the modified carpal bone segmentation method to extract carpal bones accurately and fast. Through this method, interaction is reduced dramatically comparing to manual segmentation and the accuracy is better than any other automatic methods.

This study was supported by a grant of the Korea Health 21 R&D Project, Ministry of Health & Welfare, Republic of Korea. (A020603)

Corresponding Author : Young Soo Kim,

Department of Neurosurgery, School of Medicine, Hanyang University, 17 Haengdang-dong, Seongdong-gu, Seoul, 133-791, Korea.

Tel : +82-2-2220-1553 / Fax : +82-2-2291-8498

E-mail : ksy8498@hanyang.ac.kr

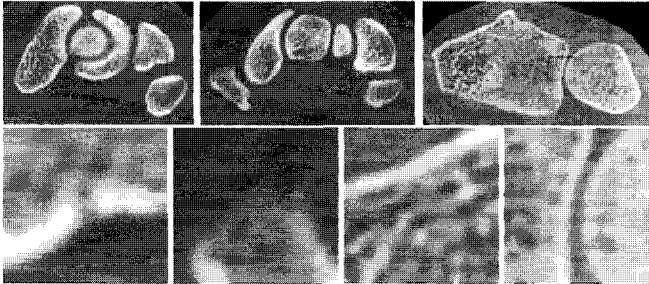


Fig. 1. Carpal bone of 3D CT image: The structure of carpal bones is complex and has very closed adjacencies between carpal bones.

B. Substances of the Study

This paper introduces region growing segmentation method using multi-seed points. Region growing is a procedure that divides pixels or sub-regions into larger regions which have similar intensity values with predefined criteria. The basic approach is to start with a set of "seed" points and regions are growing as connecting neighbor pixels which are in the predefined tolerance range of intensity.

In addition, we use "multi seed points" to extract multiple image objects simultaneously. This has advantage to apply our method to carpal bone structure which has multiple objects.

C. Review

There are several image segmentation methods for medical image [3-12]. Image segmentation subdivides an image into its constituent regions or objects. The level to which the subdivision is carried depends on the problem being solved. That is, segmentation should stop when the objects of interest in an application have been isolated. Here there are two kinds of method. One is method using region and the other is method using edge. There are image threshold, region growing, watershed segmentation algorithm in region based method. Gradient method is Edge based method

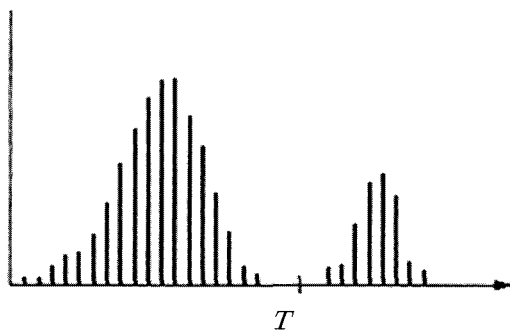


Fig. 2. Pixel value histogram that can be separated using threshold

Image Threshold

Image threshold occupies a central position in application of image segmentation. Figure 2 corresponds to an image, $f(x, y)$ composed of light objects on a dark background into two dominant modes. One obvious way to extract the objects from the backgrounds is to select a threshold T that separates these modes. A $f(x, y)$ is the gray level of each position (x, y) and a threshold image is defined as

$$g(x, y) = \begin{cases} 1 & f(x, y) \geq T \\ 0 & f(x, y) < T \end{cases} \quad (1)$$

Thus, pixels labeled 1 correspond to objects, whereas pixels labeled 0 correspond to the background.

Edge Using the Gradient

Figure 3 shows a horizontal gray-level profile of the edge between the two regions. This figure also shows the first and second derivatives for the gray-level profile. The first derivative is positive at the points of transition into and out of the ramp as we move from left to right along the profile, it is constant for points in the ramp, and is zero in areas of constant gray level. The second derivative is positive at the transition associated with the dark side of the edge, negative at the transition associated with the light side of the edge, and zero along the ramp and in areas of constant gray level. The sign of the derivatives in Figure 3 would be reversed for an edge that transitions from light to dark.

First derivatives in image processing are implemented using the magnitude of the gradient. For a function, the gradient of f at coordinates (x, y) is defined as the two-dimensional column vector. The magnitude ∇f of this vector is given by

$$\nabla f = \begin{bmatrix} G_x \\ G_y \end{bmatrix} = \begin{bmatrix} \frac{\partial f}{\partial x} \\ \frac{\partial f}{\partial y} \end{bmatrix} \quad (2)$$

This value has direction which is same as the biggest derivatives of $f(x, y)$. The direction of vector is also important factor. A $f(x, y)$ expresses the direction of the vector at the position (x, y) .

Region Growing

Region growing is a procedure that group pixels or sub-regions into larger regions based on predefined criteria. The basic approach is to start with a set of "seed" points and from these grow regions by appending to each seed those neighboring pixels that have properties (contrast, color) similar to the seed.




Fig. 3. Edge image (left) and the result of derivative operation (right)

Previous Works

Several segmentation methods have been applied to medical image field [3-12]. The fields, however, are still limited to some parts of clinical applications. Especially, in the carpal bone study, segmentation studies have not been conducted frequently. Although segmentation studies of carpal bones using deformable models is conducted with 3D CT data (T.B. Sebastial et al., 2003; P. Lin et al., 2004), these studies couldn't be applied to the clinical field [8-9]. So, more researches about carpal bone segmentation are still needed.

II. METHODOLOGY

In this paper, the method has following steps. At first, canny edge detector and image threshold are conducted as a pre-process step. Then, using region growing method, segmentation of carpal bones is conducted as a main process step.

In our method, modified region growing method starts as seed point in the background image which is the part of soft tissue. Because the carpal bones have complex structure and inhomogeneous intensity values, we try to use the soft tissue

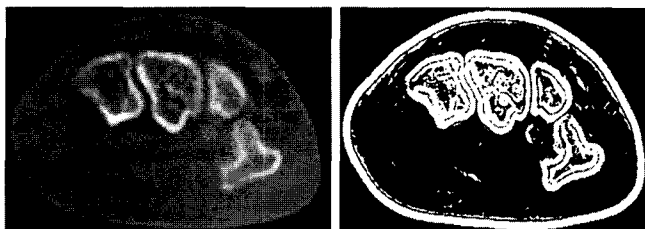


Fig. 4. Original image (left) and the result of gradient operation (right)

intensity information. And also other seed points to separate each carpal bone are used, so multi object in the carpal bones can be extracted simultaneously.

The procedure of our method is shown in Fig 5.

This paper contains canny edge detector to find object edge, threshold and region growing to strip the soft tissue and finding connectivity of each object in carpal bone image.

A. Canny Edge Detector

The Canny edge detector is optimal for finding noisy step edge under the following assumptions.

- (1) The edge filter is linear.
- (2) Some noise, white (uncorrelated) and Gaussian, is included in the image

The optimal criterion proposed by Canny conducts good edge detection and localization. So, the Canny edge detecting algorithm is known as the optimal edge detector. The Canny edge detector needs four steps to perform edge detection, that is, image smoothing, computing gradient, non-maximal suppression and hysteresis threshold shown in Fig 8.

At first, this filter makes the bone image smoothing to reduce noise. Then, to find edge region, the image gradient is computed and the region which has high spatial derivatives is selected as edge region. The algorithm tracks along these regions and suppresses any pixel that is not at the maximum (non-maximum suppression). The gradient array is further reduced by hysteresis. Hysteresis is used to track along the remaining pixels that have not been suppressed. Hysteresis uses two thresholds. If the magnitude is below the first threshold, it is set to zero (made a non-edge) and if the magnitude is above the high threshold, it is made an edge. Finally, if the magnitude is between the 2 thresholds, then it is set to zero unless there is a path from this pixel to a pixel with a gradient above T2. Here, the threshold values, T1 and T2, are selected interactively by user with respect to the histogram of each slice. So, the values of T1 and T2 are changed as the conditions of image data.

B. Image Threshold

We use the threshold image data with the edge data from Canny edge detector to enhance the accuracy of our study. Segmented data set is obtained by comparing the threshold region with edge area.

C. Stripping Soft Tissue

Now, we apply region growing method to the image. The inner carpal bone delineated on CT images is uneven and rugged. For these reason, there are many problems when using general region growing method. So, modified region growing

method proposed in this paper is applied. Soft tissue of CT images is generally homogeneous comparing to bone structure, so soft tissue region is proper to apply region growing more easily than bone area. When region grows, start seed point is selected on the soft tissue and apply region growing. This can be separate soft tissue and object tissue. Then, if the region is ambiguous cause of a little difference at the boundary, the edge information is used to make better decision.

D. Obtaining the Carpal bone Objects from Image

To obtain carpal bone objects from images, we have to find connectivity from stripped image. Finding connectivity between pixels is fundamental to separate regions and boundaries. If two pixels are connected and satisfy a specific criterion of similarity, it must be determined neighbors. In our study, 8 neighbors are used to define the connectivity.

In segmented image, using multi seed point, the bone objects can be separated with respect to the connectivity and define each bone structure.

E. GUI Composition

The software, so called CarpalSegmenter, is implemented under Visual C++ environment to apply carpal bone segmentation to clinical application.

This Software can detect canny edge, threshold, strip soft tissue in the image and distinguish carpal bones. And in order to adjust image at final step, add to manually drawing function. In our study, however, the manual editing function does not apply to evaluate our method. In addition, some basic functions for image processing are implemented in CarpalSegmenter.

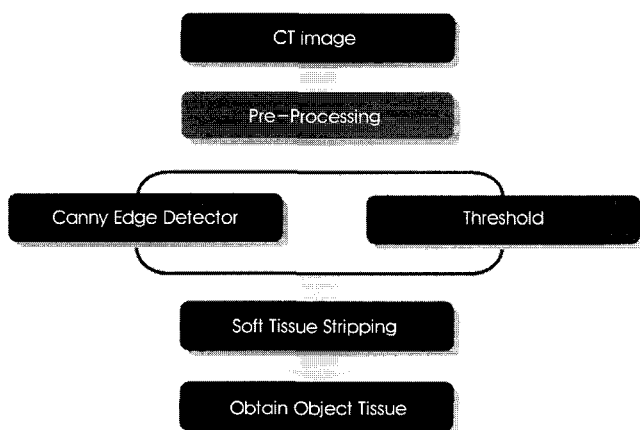


Fig. 5. Procedures of our method: In our method, canny edge detector and threshold are used to enhance the result of segmentation.

III. EXPERIMENTS

Ten different patient 3D CT data sets (193 slides) with 2 or 3mm slice interval are applied to experiments for evaluating. In our study, two kinds of experiments are conducted. The first one is comparison with other segmentation methods, and the other is comparison with the result of gold standard method which is performed manually by experts.

A. Comparison with other Segmentation Methods

This comparison test is conducted with simple threshold and gradient segmentation method. Using each result from these three segmentation methods include to our method, we can see how the segmentation result presents the original carpal bone objects well.

B. Comparison with gold Standard

This comparison test is conducted with the result of gold standard. In our study, gold standard means the result of manual segmentation method by experts. So, through comparing two results from our method and gold standard method, we can see the accuracy of our method. And also we can make decision whether our method can be applicable in clinical field.

IV. RESULTS

A. The Results of Comparison with other Segmentation Methods

Threshold segmentation method uses just pixel values, and the gradient method performs with only gradient map.

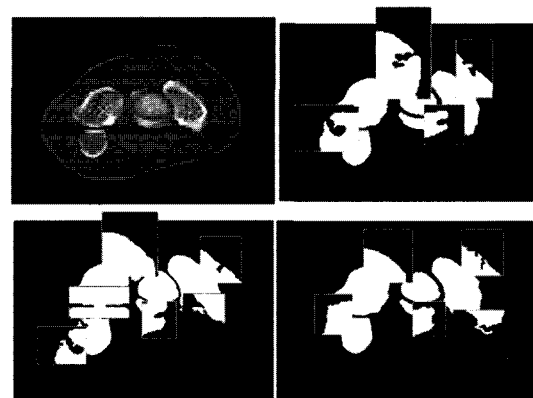


Fig. 6. The comparison results: The upper left image is a source, the upper right image is the result of threshold. And the lower left is the result of gradient operation, the lower right is the result of our method. From these figures, our method shows better result than any other segmentation methods.

Table 1. The criterion (proposed method vs. the gold standard).

Success	Failure
TRUE-POSITIVE Pixel is in the two results.	TRUE-NEGATIVE Pixel is in the only the result of gold standard.
Not consider FALSE-NEGATIVE!	FALSE-POSITIVE Pixel is in the only the result image of our method

Because of insufficient information, those two methods show worse results than our proposed method (Fig.6).

B. The Results of Comparison with Gold Standard

This second experiment is comparison test between our proposed method and gold standard method, manually segmentation.

To compare these results, we separate 2 parts as success and failure. Success is True-positive result and failure is True-negative and False-positive results (table 1).

We get satisfied results, the total error is 1.476(%) shown in table 2. This result is applicable to apply to clinical field. Because the gold standard result is performed by expert, the result of second experiment means that our method has high accurate performance.

IV. CONCLUSIONS

In carpal bone fracture surgery, generally, surgeons want to use adjacent several bones to know about accurate surgical path with respect to the neighbors, it is the reason why we extract multi objects simultaneously. Select a seed points in the bone structure and soft tissue area in image, then strip the soft tissue pixel value and finally the objects are defined with respect to the connectivity information of the bone objects.

We can get acceptable result when we apply this method to carpal bone image segmentation. The reason is due to using more information such as edge information from canny edge

Table 2. The comparison result

No.	Success(unit : %)	Failure (unit : %)
Case1	97.031	2.969
Case2	99.938	0.062
Case3	97.459	2.541
Case4	99.970	0.030
Case5	99.856	0.144
Case6	98.193	1.807
Case7	99.571	0.429
Case8	99.291	0.709
Case10	99.180	0.820
Total	97.639	2.361

detector and soft tissue region growing comparing to other simple segmentation methods. The result of the canny edge detection is moderate in segmentation problems, because it has processes such as non-maximum suppression and hysteresis threshold as thinning procedure. The Canny edge detection uses an optimal edge detector based on a set of criteria which include finding the most edges by minimizing the error rate, marking edges as closely as possible to the actual edges to maximize localization, and marking edges only once when a single edge exists for minimal response non-maximum suppression and hysteresis threshold.

Soft tissue stripping which is a kind of region growing segmentation method operates well in even and un-rugged images. Because of this fact, it performs well in background of carpal bone segmentation, and the accuracy is very acceptable comparing to manually segmentation method as a gold standard method.

In this study, although, high technologies or novel algorithms aren't applied, the purpose which is developing very meaningful software in clinical field is satisfied. Using the CarpalSegmenter, more case studies will be conducted and upgrading of our software will be continued to adapt on the clinical environment.

REFERENCES

- [1] T. Murase, H. Moritomo, A. Goto, K. Sugamoto, H. Yoshikawa, "Does three-dimensional computer simulation improve results of scaphoid nonunion surgery?," *Clinical Orthopaedics and Related Research*, no. 434, pp.143-150, 2005.
- [2] H. Kobatake, "Future CAD in multi-dimensional medical images:Project on multi-organ, multi-disease CAD system," *Computerized Medical Imaging and Graphics*, vol. 31, no. 4-5, pp.258-266, 2007.
- [3] F. Gelaude, J.V. Sloten, B. Lauwers, "Semi-automated segmentation and visualization of outer bone cortex from medical images," *Computer Methods in Biomechanics and Biomedical Engineering*, vol. 9, no. 1, pp.65-77, 2006.
- [4] D.L. Pham, C. Xu, J. L. Prince, "A survey of current methods in medical image segmentation," *Annual Review of Biomedical Engineering*, vol. 2, pp315-337, 1998.
- [5] T.C. Huanga, G. Zhanga, T. Guerrerob, G.Starkschall , K.P. Linc, K. Forster, "Semi-automated CT segmentation using optic flow and Fourier interpolation techniques," *Computer Methods and Programs in Biomedicine*, vol. 84, no. 2, pp123-134, 2006.
- [6] J.F Canny, "A computational approach to edge detection," *IEEE Trans Pattern Analysis and Machine Intelligence*, vol. 8, no. 6, pp.679-698, 1986.
- [7] B.S. Sharif, S.A. Zaroug, E.G. Chester, J.P. Owen, E.J. Lee, "Bone Edge Detection in Hand Radiographic Images," in *Proc. 16th Annual International Conference of the IEEE, Baltimore, MD, USA, Nov. 1994*, pp.514-5.

- [8] T.B. Sebastiana, H. Teka, J. J. Criscob, B.B. Kimia, "Segmentation of carpal bones from CT images using skeletally coupled deformable models," *Medical Image Analysis*, vol. 7, pp 2145, 2003.
- [9] P. Lin, F. Zhang, Y. Yang, C. Zheng, "Carpal-bone feature extraction analysis in skeletal age assessment based on deformable model," *J. Computer Science & Technology*, vol. 4, no. 3, pp.152-156.
- [10] T. Pavlidis, Y. Liow, "Integrating region growing and edge detection," *IEEE Trans Pattern Analysis and Machine Intelligence*, vol. 12, no. 3, pp.225-233, 1990.
- [11] D. Kim, "Convenient semi-automatic segmentation tool," *J. Biomed Eng Res*, vol. 26, no. 6, pp.407-12, 2005.
- [12] K. Seo, S. Park, "Automatic liver segmentation of a contrast enhanced CT image using and improved partial histogram threshold algorithm," *J. Biomed Eng Res*, vol. 26, no. 3, pp171-6, 2005.