

## Clinical Article

# The Treatment Outcome of Elderly Patients with Idiopathic Trigeminal Neuralgia : Micro-Vascular Decompression versus Gamma Knife Radiosurgery

In Ho Oh, M.D., Seok Keun Choi, M.D., Bong Jin Park, M.D., Tae Sung Kim, M.D., Bong Arm Rhee, M.D., Young Jin Lim, M.D.

Department of Neurosurgery, Kyung Hee University Hospital, Seoul, Korea

**Objective :** This study was designed to compare the efficacy of micro-vascular decompression (MVD) and Gamma knife radiosurgery (GKRS) for elderly idiopathic trigeminal neuralgia patients by analyzing the clinical outcome.

**Methods :** In the past 10 years, 27 elderly patients were treated with MVD while 18 patients were treated with GKRS (>65-years-old). We reviewed their clinical characteristics and clinical courses after treatment as well as the treatment outcomes. For patients who were treated with MVD, additional treatment methods such as rhizotomy were combined in some areas. In GKRS, we radiated the root entry zone (REZ) with the mean maximum dose of 77.8 (70-84.3) Gy and one 4 mm collimator.

**Results :** The mean age was 68.1 years for MVD, and 71.1 years for GKS group. The average time interval between first presenting symptom and surgery was 84.1 (1-361) months, and 51.4 (1-120) months, respectively. The mean follow-up period after the surgery was 35.9 months for MVD, and 33.1 months for GKRS. According to Pain Intensity Scale, MVD group showed better prognosis with 17 (63%) cases in grade I-II versus 10 (55.6%) cases in GKRS group after the treatment. The pain recurrence rate during follow up did not show much difference with 3 (11.1%) in MVD, and 2 (11.1%) in GKRS. After the treatment, 2 cases of facial numbness, and 1 case each of herpes zoster, cerebrospinal fluid (CSF) leakage, hearing disturbance, and subdural hematoma occurred in MVD Group. In GKRS, there was 1 (5.6%) case of dysesthesia but was not permanent. Three cases were retreated by GKRS but the prognosis was not as good as when the surgery was used as primary treatment, with 1 case of grade I-II, and 1 case of recurrence. The maximal relieve of pain was seen just after surgery in MVD group, and 1 year after treatment in GKRS group.

**Conclusion :** For trigeminal neuralgia patients with advanced age, MVD showed advantages in immediately relieving the pain. However, in overall, GKRS was preferable, despite the delayed pain relief, due to the lower rate of surgical complications that arise owing to the old age.

**KEY WORDS :** Elderly patient · Idiopathic trigeminal neuralgia · Micro-vascular decompression · Gamma knife radiosurgery.

## INTRODUCTION

Idiopathic trigeminal neuralgia (TN) is a cranial nerve dysfunction where pain is induced by increased excitability of the nerve fiber affecting adjoining fibers to overreact to usual sensory signals. It is known that TN occurs due to focal demyelination of trigeminal nerve root caused by vascular compression and nerve degeneration due to increase in age<sup>19,21,23,25</sup>. Current treatments are mainly divided into two different methods involving medical treatments and surgery. But, the medical treatments have higher recurrence rates

and adverse side effects and moreover, many cases of drug intolerance can be seen in patients with advanced age. Therefore, surgical treatments such as percutaneous administration of medicine, percutaneous ablative procedure, micro-vascular decompression (MVD), and gamma knife radiosurgery (GKRS) are routinely being applied<sup>121,23,32</sup>.

In our department, MVD and GKRS are mainly used for idiopathic TN. This study was designed to see which method is better for elderly patients. On the basis of the retrospective clinical analysis, the authors compared two groups for the efficacy and the characteristics of clinical course after the treatment.

## MATERIALS AND METHODS

A total of 104 patients diagnosed with TN from March,

• Received : May 28, 2008 • Accepted : September 17, 2008

• Address for reprints : Seok Keun Choi, M.D.

Department of Neurosurgery, Kyung Hee University Hospital, 1 Hoegi-dong, Dongdaemun-gu, Seoul 130-702, Korea

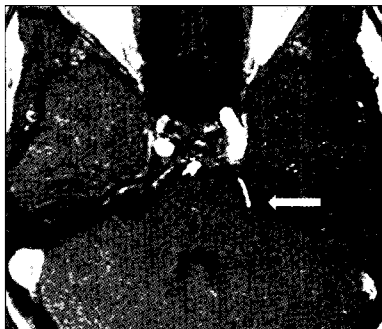Tel : +82-2-958-8385, Fax : +82-2-958-8380

E-mail : nsck@hanmail.net

1995 to December, 2005, and 79 MVDs and 25 GKRSs underwent for the idiopathic TN in our institute. Seventy-nine out of 104 were treated with MVD and among the 79, 27 (34.2%) were elderly patients with the age above 65. For the 25 patients who underwent GKRS, 18 (72%) were above the age 65. A comparative analysis of these two groups was done using parameters such as age, duration of symptoms before surgery, range of presenting symptoms and treatment outcome.

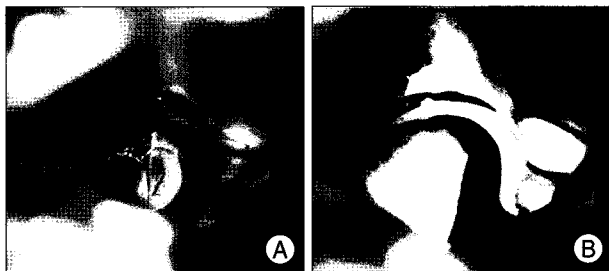
**Radiographical and Clinical Studies**

Brain magnetic resonance image (MRI) was taken for all patients. Short-range three dimensional MRI technique (Fig. 1) was used to define the vessels around the brain stem

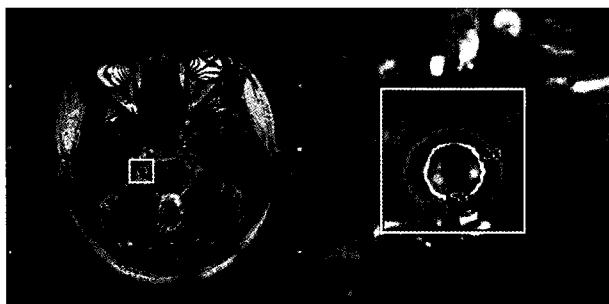


**Fig. 1.** Short-range three dimensional magnetic resonance image technique demonstrates that left superior cerebellar artery is compressing trigeminal nerve root (arrow).

and nerve structures. After MVD, in order to make sure there is no hemorrhagic complications developing, brain computed tomography (CT) was taken within 2 to 3 days after the surgery in all cases. For all cases, neurological examinations were given before



**Fig. 2.** The operative findings of micro-vascular decompression for the trigeminal neuralgia at V2 and V3 area via left suboccipital retromastoid approach. A : Left superior cerebellar artery compressing REZ. B : Offending vessel is decompressed with Teflon pledget.



**Fig. 3.** Targeting root entry zone of trigeminal nerve using Gamma plan.

treatment to check clinical symptoms. To estimate the change of symptoms, the degree of immediate pain relief was recorded during hospital stay and the intensity of pain were checked carefully by outpatient follow up. The degree of pain was checked using Barrow Neurological Institute (BNI) Pain Intensity Scale, and Gr I+II was considered as a favorable outcome<sup>8)</sup> (Table 1).

**Surgical Procedure**

**Microvascular decompression**

After general anesthesia, conventional suboccipital craniectomy was done. To preserve the venous return from the brain, we made sure that jugular vein was not compressed. And then, 2×3 cm sized craniotomy was performed and the dura was incised in Y-shape. With the cerebellum retracted caudal and backward, we could find the sensory and motor branch of trigeminal nerve after sharply dissecting arachnoid membrane. When offending vessel was present, MVD was performed using Teflon (Fig. 2). During this process, patient was monitored carefully in order to avoid hypotension and bradycardia that might occur by excitement of parasympathetic nerve due to compressed trigeminal nerve ganglion. For all patients, cranioplasty was done with hydroxyl-apatite bone cement<sup>30)</sup>.

**Gamma knife radiosurgery**

Under local anesthesia, brain MRI was checked in all cases after setting stereotactic frame (Leksell Gamma Knife frame, Elekta, Sweden). In order to observe the trigeminal nerve root entry zone (REZ) more thoroughly, CISS (constructive interference in steady state) image technique and FIESTA

**Table 1.** Barrow neurological institute pain intensity scale<sup>8)</sup>

| Grade | Description                        | Outcome   |
|-------|------------------------------------|-----------|
| I     | No pain, no medication             | Excellent |
| II    | No pain with medication            | Good      |
| III   | >50% improved pain with medication | Fair      |
| IV    | <50% improved pain with medication | Poor      |
| V     | No pain relief                     |           |

**Table 2.** Distribution of the affected branches of trigeminal nerve

| Affected area | Number of patients |      |
|---------------|--------------------|------|
|               | MVD                | GKRS |
| V1            | 2                  | 1    |
| V2            | 2                  | 1    |
| V3            | 6                  | 3    |
| V1+V2         | 4                  | 4    |
| V2+V3         | 11                 | 8    |
| V1+V2+V3      | 2                  | 1    |

MVD : micro-vascular decompression, GKRS : Gamma knife radio surgery

(fast imaging employing steady-state acquisition) image technique were used<sup>7,33</sup>. For all cases, REZ of the trigeminal nerve was decided as the target, 4 mm-collimator was used for isocenter (Fig. 3) and mean maximal dose was 77.8 Gy (range : 70.0-84.3).

**RESULTS**

**Clinical Characteristics**

Of the 27 patients treated with MVD, 7 were male and 20 were female. The mean duration of symptom was 84.1 months, the mean follow-up period was 35.9 months, and the mean age was 68.1 (65-74) years old. Of the 18 patients treated with GKRS, 6 were male and 12 were female. The mean duration of symptom was 51.4 months, the mean follow-up period was 33.1 months, with mean age being 71.1 (61-85) years.

In both groups, V2+V3 were found to be the most common area of pain based on trigeminal nerve distribution (Table 2). On the first visit to the hospital for treatment, 3 patients presented light degree of facial nerve paralysis and 1 patient presented facial paralysis with hearing loss on the same side. In both groups, all had history of receiving medical treatments, but symptom improvement to Grade I+II based on Pain Intensity Scale, a favorable outcome regarding the relief of pain was not observed. Re-treatment cases after receiving previous percutaneous method and surgical treatment were 3 in MVD group, and 2 in GKRS group.

For 24 (88.9%) of the 27 patients treated with MVD, definite offending vessels were confirmed in surgical field, but for 18 patients treated with GKRS, offending vessels were identified on MRI only in 7 (38.9%) cases.

In MVD group, 10 (37%) patients had underlying medical problems including 6 cases of hypertension, 2 cases of diabetes, 1 heart disease and 1 hepatitis. For GKRS group, 12 (55.6%) patients had combined medical problems including 4 cases of hypertension, 2 cases of diabetes, 1 heart disease and 1 pulmonary disease, and 3 cases of other medical problems. When these two groups were compared, GKRS was more frequently applied to patients with underlying medical problems (Table 3).

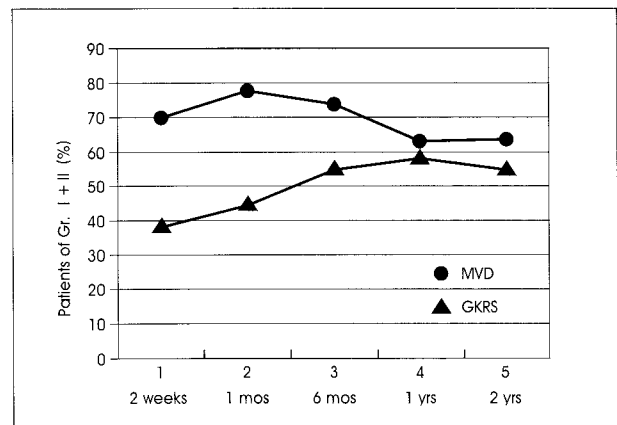
**Treatment results**

In all patients, pain intensity was measured immediately after MVD or GKRS, during the 2 weeks of hospital stay, and at the last follow up visit at out-patient clinic. When

**Table 3.** Clinical characteristics of two groups

| Characteristics                  | MVD (n=27)   | GKRS (n=18)  | p-value |
|----------------------------------|--------------|--------------|---------|
| Mean age (yrs)                   | 68.1 (65-73) | 71.1 (65-85) |         |
| >65 years old patient (%)        | 34.2         | 72           |         |
| Male/Female                      | 7/20         | 6/12         | 0.59    |
| Symptom Duration (months)        | 84.1         | 51.4         |         |
| Mean follow-up duration (months) | 35.9         | 33.1         |         |
| Medical problem (%)              | 10 (37%)     | 11 (61.1%)   | 0.11    |
| Hypertension                     | 6            | 4            |         |
| Diabetes                         | 2            | 2            |         |
| Cardiac disease                  | 1            | 1            |         |
| Pulmonary disease                | 0            | 1            |         |
| Others                           | 1            | 3            |         |
| Previous percutaneous Tx/Op      | 3            | 2            |         |
| Definite offending vessel (+)    | 88.9%*       | 38.9%**      | <0.001  |
| Pain location (V2+V3)            | 11 (39.3%)   | 8 (44.5%)    | 0.81    |

\*operative finding, \*\*imaging study. MVD : micro-vascular decompression, GKRS : Gamma knife radiosurgery. Tx: treatment, OP : operation



**Fig. 4.** Favorable outcomes of trigeminal neuralgia in micro-vascular decompression and Gamma knife radiosurgery. MVD : micro-vascular decompression, GKRS : Gamma knife radiosurgery, Gr : grade.

comparing the rate of favorable outcome (Grade I+II based on pain intensity scale), regardless of the duration of prior medical treatment, 70.3% of patients showed favorable outcome just after the treatment in MVD group. But, the rate decreased to 63.0% at the last follow-up. On the other hand, 40.9% of patients in GKRS group showed favorable outcome at first follow up of 2 weeks, but increased to 55.6% during the 2 years of follow-up period. Finally, among the 27 cases treated with MVD, 17 (63.0%) showed favorable outcome regardless of drug treatment, presenting better outcome compared to GKRS group's 10 (55.6%) out of 18 patients (Fig. 4).

Recurrence of pain occurred in 3 (11.1%) cases of MVD group and 2 (11.1%) cases of GKRS group, respectively. The mean duration between the treatments and recurrence was 17.7 months in MVD group and 6 months in GKRS group, showing comparatively longer duration in MVD

**Table 4.** Recurrence for trigeminal neuralgia according to treatment modality

| Parameter                 | MVD (n=27) | GKRS (n=18) |
|---------------------------|------------|-------------|
| Recurrence (%)            | 3 (11.1)   | 2 (11.1)    |
| Time interval (months)    | 17.7       | 6           |
| Management for recurrence |            |             |
| MVD                       | 0          | 0           |
| GKRS                      | 1          | 0           |
| Radiofrequency            | 0          | 0           |
| Medication                | 2          | 2           |

MVD : micro-vascular decompression, GKRS : Gamma knife radio surgery

group. Regarding patients whose symptoms recurred, in 2 of the 3 cases treated with MVD, conservative medication was given and in 1 case, patient was treated by GKRS. On the other hand, medical treatment was given for the 2 cases with recurrent pain after GKRS (Table 4).

### Complications

Complications after MVD include constant headache in 11 patients, and facial paresthesia in 5 patients but during follow-up visits, all patients except one showed improvement. Two patients complained of paresthesia of the tongue and one had infection at the incision site. A scanty amount of acute subdural hemorrhage at supratentorial area occurred in 1 case, but disappeared with conservative management. Furthermore, there was one case each of temporary hearing disturbance, and otitis media with cerebrospinal fluid leakage, but except for the 4 cases of paresthesia of face and tongue, all other symptoms improved.

For complications of GKRS, there were 2 case of paresthesia, but adverse radiation effect was not seen on follow up, and there were no other specific complications observed except for the transient pin site infection.

### DISCUSSION

In idiopathic TN, excitability of nerve fiber is increased, and adjoining fibers overreact to a normal sensory signal, leading to sporadic and electrical facial pain. It is known to occur due to focal demyelination caused by vascular compression of trigeminal nerve root<sup>19, 25</sup>. TN can be induced by many other causative factors classified as secondary causes including tumor, multiple sclerosis, herpes virus, Lyme disease, and Wallenberg syndrome<sup>6</sup>.

The fact that MVD is very effective at reducing early symptoms of TN suggests that vascular compression is an important causative factor in TN. Dissimilar from the cause of hemifacial spasm which is almost always induced by vascular compression, TN can occur without compression of a definite offending vessel or other causative factors

mentioned in some cases. Therefore, as for the treatment of TN, other treatment methods besides MVD are more commonly being applied. Treatment of TN is largely divided into two categories, medical treatment and surgical treatment. Because medical treatment has high rate of recurrence and complication and drug intolerance in elderly patients, surgical treatments such as MVD, GKRS, rhizotomy, and percutaneous ablative surgery should be considered in majority of advanced aged patients<sup>32</sup>.

TN is reported to be more common in elderly. The proportion of older age (>65 years) in each group is that 34.2% (27/79) in MVD group and 72% (18/25) in GKRS group. Due to the high proportion of the elderly patients, having one or more medical problems, GKRS was preferred in our study in spite of their success rate. In the selection of treatment methods, it is believed to be of some significance<sup>15,16,32</sup>.

Due to the pre-existing age related medical conditions, for older patients surgical treatment performed under general anesthesia was often not affordable and thus, radiosurgery was applied primarily as an alternative treatment method. Since 1951, when radiosurgery was first employed on TN patient, the number of patients having radiosurgery has been greatly increasing due to its use as a primary treatment method for those patients who are not responsive to drug treatments. The exact mechanism of how radiosurgery alleviates pain is not clearly known, but it is thought that decreased pain at the beginning of radiation treatment is due to blockage of neuron's ephaptic transmission, while continued pain reduction is thought to be due to the radiation blocking the neuron's microvasculature, leading to nerve degeneration, in turn blocking neurotransmission<sup>23</sup>.

Surgical treatment of TN includes MVD based on vascular compression theory. And, when there is no evidence of vascular compression, or when compression is undetermined despite the presence of a probable offending vessel, as well as in order to give a better outcome, rhizotomy is used concurrently.

Based on many studies, the pain loss rate of MVD for TN widely ranges between 53 to 95%, and the pain recurrence rate during follow up is reported to be 3-32.3%<sup>11,13,29</sup>. Barker et al.<sup>1</sup> in a research which analyzed 1,204 patients over relatively long term average follow up of 6.2 years, reported that pain loss rate was 70%. But, other research done by Elias et al.<sup>10</sup> where 8.5 years of follow up results on 40 older patient were reported, the outcome was not as favorable with 47% of the patients continuously complained of pain, and the disease recurring in 31% of the patients. The fact that the recurrence rate varies between 6-23%, and that the treatment results varies widely between each report is due

to different surgical methods used as well as the difference between the length of follow up period<sup>26)</sup>. In this research, analysis was based on 2-years follow up for each patient and the results were similar to other studies with 70.3% showing initial favorable outcome regarding the pain intensity (I+II on Pain Intensity Scale), and 63.8% showing complete resolution (Fig. 4).

Methods such as compressing Meckel's cave are diversely implemented in surgery. Researches on this method are based on Correa's<sup>9)</sup> balloon compression, and although there is no established theory, the purpose of the process is to preserve the nerve fibers that were myelinated.

GKRS is reported by many authors to have 41-76.4% success rate<sup>12,14,16-19,27,28,31)</sup>, and is being more frequently used despite its lower success rate compared to MVD, because GKRS is relatively simple to perform, safe, and surgical complications are rare owing to its noninvasiveness.

Regarding radiation dosage, the maximal dose is thought to be between 70 to 90 Gy based on many reports and treatment experiences<sup>16,18,19,22,28)</sup>. When lower dose (60-65 Gy) is used, injury to the brain stem can be minimized, but it is not enough to control the pain. On the other hand, when high dose (80-90 Gy) is used, although it is enough to control the pain, more adverse side effects than benefits are seen.

During the early years, 8 mm collimator was used for targeting the Gasserian ganglion, but with the development of CT and MRI methods, visualization of proximal trigeminal nerve in detail became possible. As root entry zone (REZ) near by the pons was seen clearly, precise targeting became possible, enabling GKS with 4-mm collimator (Fig. 3).

Based on experimental results to date, the most important fact in targeting is that pain control is more effective as it gets closer to the brain stem, but that the risk of development of side effects is much greater if radiation dosage is excessive. Pollock et al.<sup>27)</sup> in a report suggesting the correlation between radiation dosage and trigeminal nerve dysfunction, stated that higher rate of side effects was seen among the patients who were treated with 90 Gy, compared to 70 Gy. Thus, it can be proposed that with the appropriate mean maximal radiation dose given, targeting is safer with longer trigeminal REZ. But, targeting complications are becoming less problematic as precise targeting is possible due to superior imaging technology, and proximal portion of trigeminal nerve is being considered as a good targeting area without serious side effects. For this study, treatment using mean maximal radiation dosage of 77.8 Gy (70-84.3 Gy), with the area 2-4 mm from REZ's brain stem as the target, using 4 mm diameter helmet, was planned.

In this study where treatment results from 18 patients were analyzed, the results were not significantly different

from other studies. At the beginning of regular follow-up, favorable outcome of Grade I+II based on Pain intensity scale, was seen in 7 patients (38.9%), and after 2 years, it was seen in 10 patients (55.6%)<sup>1)</sup>.

In many studies, MVD is reported to be better than radiosurgery regarding initial pain loss. When choosing a treatment method for patients of advanced age, general condition of the patient, the cause of pain, and the intensity of pain should be considered. However, on the basis of reported results until now, recurrence of pain, and complications should also be considered<sup>2,3)</sup>.

Study results show that surgical treatments such as MVD have good initial pain loss rate, and relatively low recurrence rate which are of advantages, but the fact there are more complications compared to radiosurgery is a consistently raised problem<sup>1,4,5,24,26,30)</sup>. During surgery, careful manipulation is essential because if excessive force is used during cerebellum retraction, cerebellar edema, contusion, and hematoma can occur after the surgery. Furthermore, especially for elderly patients, special caution is needed because there is high tendency for cerebrospinal fluid leakage and hematoma to occur. In our cases, relatively mild complications arising after surgery were headache, paresthesia of face or tongue and cerebrospinal fluid leakage and some of the serious ones were inflammation and acute subdural hemorrhage. In case of the latter complications, patients were temporarily admitted to Intensive Care Unit (ICU) with no aftereffects when discharged.

The advantage of using radiosurgery for treating idiopathic TN is that it is known to have lesser complication rate. Many studies report that after radiosurgery, 6-10% of patients show facial paresthesia or hypoesthesia as the most common complication, and reports 6-13% occurrence rate of another trigeminal dysfunction, but overall, it shows low complication rate compared to other treatment methods<sup>9,12,15,17-20,22)</sup>. Similar results were seen in this study as well, with one patient complaining of facial paresthesia after the radiosurgery.

## CONCLUSION

For the treatment of TN, it has been known that MVD, when compared to GKRS, shows superior early symptom reduction rate and pain decreasing rate during follow up. However, in this study, after 2 years of follow up of older patients of over 65, no significant differences were found between the two groups. Considering treatment complications for elderly patients, it is believed that GKRS is a better treatment method in these patients and that longer follow up study is warranted.

References

1. Barker FG, Jannetta PJ, Bissonette DJ, Shields PT, Larkins MV : Long term outcome after microvascular decompression for typical trigeminal neuralgia. *N Engl J Med* 334 : 1077-1083, 1996
2. Bederson JB, Wilson CB : Evaluation of microvascular decompression and partial sensory rhizotomy in 252 cases of trigeminal neuralgia. *J Neurosurg* 71 : 359-367, 1989
3. Broggi G, Ferroli P, Franzini A, Servello D, Dones I : Microvascular decompression for trigeminal neuralgia : comments on a series of 250 cases, including 10 patients with multiple sclerosis. *Br Med J* 68 : 59, 2000
4. Brown JA, McDaniel MD, Weaver MT : Percutaneous Trigeminal Nerve Compression for Treatment of Trigeminal Neuralgia : Results in 50 Patients. *Neurosurgery* 32 : 570, 1993
5. Burchiel KJ, Clarke H, Haglund M, Loeser JD : Long-term efficacy of microvascular decompression in trigeminal neuralgia. *J Neurosurg* 69 : 35-38, 1988
6. Burchiel KJ, Slavin KV : On the Natural History of Trigeminal Neuralgia. *Neurosurgery* 46 : 152, 2000
7. Chavez GD, De Salles AA, Solberg TD, Pedroso A, Espinoza D, Villablanca P : Three-dimensional fast imaging employing steady-state acquisition magnetic resonance imaging for stereotactic radiosurgery of trigeminal neuralgia. *Neurosurgery* 56 : E628, 2005
8. Cheuk AV, Chin LS, Petit JH, Herman JM, Fang HB, Regine WF : Gamma knife surgery for trigeminal neuralgia : Outcome, imaging, and brainstem correlates. *Int J Radiat Oncol Biol Phys* 60 : 537-541, 2004
9. Correa CF, Teixeira MJ : Balloon compression of the Gasserian ganglion for the treatment of trigeminal neuralgia. *Stereotact Funct Neurosurg* 71 : 83-89, 1998
10. Elias WJ, Burchiel KJ : Microvascular Decompression. *Clin J Pain* 18 : 35-41, 2002
11. Frazier CH, Lewy FH, Rowe SN : The origin and mechanism of paroxysmal neuralgic pain and the surgical treatment of central pain. *Brain* 60 : 44-51, 1937
12. Hakanson S : Gamma knife treatment in classical trigeminal neuralgia. Long term follow up. *Scientific Program of 8th International Meeting of the Leksell Gamma Knife Society.(Abstract)* 63, 1997
13. Kalkanis SN, Eskandar EN, Carter BS, II FGB : Microvascular Decompression Surgery in the United States, 1996 to 2000 : Mortality Rates, Morbidity Rates, and the Effects of Hospital and Surgeon Volumes. *Neurosurgery* 52 : 1251-1261; discussion 1261-1262, 2003
14. Kanner AA, Neyman G, Suh JH, Weinhaus MS, Lee SY, Barnett GH : Gamma Knife Radiosurgery for Trigeminal Neuralgia : Comparing the Use of a 4-mm versus Concentric 4-and 8-mm Collimators. *Stereotact Funct Neurosurg* 82 : 49-57, 2004
15. Kondziolka D, Flickinger JC, Lunsford LD, Habeck M : Trigeminal neuralgia radiosurgery : the University of Pittsburgh experience. *Stereotact Funct Neurosurg* 66 : 343-348, 1996
16. Kondziolka D, Lunsford LD, Flickinger JC, Young RF, Vermeulen S, Duma CM, et al : Stereotactic radiosurgery for trigeminal neuralgia : a multiinstitutional study using the gamma unit. *J Neurosurg* 84 : 940-945, 1996
17. Kondziolka D, Lunsford LD, Habeck M, Flickinger JC : Gamma knife radiosurgery for trigeminal neuralgia. *Neurosurg Clin N Am* 8 : 79-85, 1997
18. Leksell L : Stereotaxic radiosurgery in trigeminal neuralgia. *Acta Chir Scand* 137 : 311-314, 1971
19. Leksell L : Trigeminal neuralgia. Some neurophysiologic aspects and a new method of therapy. *Lakartidningen* 68 : 5145-5148, 1971
20. Lim YJ, Choi SK : Gamma Knife Radiosurgery for Vestibular Schwannomas. *J Korean Neurosurg Soc* 42 : 159-167, 2007
21. Lim YJ, Leem W, Rhee BA, Keem SH, Park JT, Kim TS, et al : Gamma Knife Radiosurgery vs. Microsurgery in Essential Trigeminal Neuralgia. *Stereotact Funct Neurosurg* 74 : 140, 2000
22. Lindquist C, Kihlstrom L, Hellstrand E, Knife G : Functional Neurosurgery-A Future for the Gamma Knife? *Stereotact Funct Neurosurg* 57 : 72-81, 1991
23. Lunsford L, Niranjan A : Surgical management options for trigeminal neuralgia. *J Korean Neurosurg Soc* 41 : 359-366, 2007
24. Lunsford LD, Bennett MH : Percutaneous retrogasserian glycerol rhizotomy for tic douloureux : Part 1. Technique and results in 112 patients. *Neurosurgery* 14 : 424-430, 1984
25. Moller AR, Jannetta PJ : On the origin of synkinesis in hemifacial spasm : results of intracranial recordings. *J Neurosurg* 61 : 569-576, 1984
26. Piatt JH Jr, Wilkins RH : Treatment of tic douloureux and hemifacial spasm by posterior fossa exploration : therapeutic implications of various neurovascular relationships. *Neurosurgery* 14 : 462-471, 1984
27. Pollock BE, Phuong LK, Foote RL, Stafford SL, Gorman DA : High-dose trigeminal neuralgia radiosurgery associated with increased risk of trigeminal nerve dysfunction. *Neurosurgery* 49 : 58-62, 2001
28. Regis J, Manera L, Dufour H, Porcheron D, Sedan R, Peragut JC : Effect of the Gamma Knife on trigeminal neuralgia. *Stereotact Funct Neurosurg* 64 : 182-192, 1995
29. Szapiro Jr J, Sindou M, Szapiro J : Prognostic factors in microvascular decompression for trigeminal neuralgia. *Neurosurgery* 17 : 920-929, 1985
30. Taarnhoj P : Decompression of the posterior trigeminal root in trigeminal neuralgia. A 30-year follow-up review. *J Neurosurg* 57 : 14-17, 1982
31. Young RF, Vermeulen SS, Grimm P, Blasko J, Posewitz A : Gamma Knife radiosurgery for treatment of trigeminal neuralgia : idiopathic and tumor related. *Neurology* 48 : 608-614, 1997
32. Zakrzewska JM, Patsalos PN : Long-term cohort study comparing medical (oxcarbazepine) and surgical management of intractable trigeminal neuralgia. *Pain* 95 : 259-266, 2002
33. Zerris VA, Noren GC, Shucart WA, Rogg J, Friehs GM : Targeting the cranial nerve : microradiosurgery for trigeminal neuralgia with CISS and 3D-flash MR imaging sequences. *J Neurosurg* 102 : 107-110, 2005