

Clinical Article

The Outcomes of Concomitant Chemoradiotherapy Followed by Adjuvant Chemotherapy with Temozolomide for Newly Diagnosed High Grade Gliomas : The Preliminary Results of Single Center Prospective Study

Jung-Won Choi, M.D.,¹ Min Mi Lee, R.N.,¹ In Ah Kim, M.D.,² Jee Hyun Kim, M.D.,³ Gheeyoung Choe, M.D.,⁴ Chae-Yong Kim, Ph.D.¹

Departments of Neurosurgery,¹ Radiation Oncology,² Internal Medicine,³ Pathology,⁴ Seoul National University Bundang Hospital, Seoul National University College of Medicine, Seongnam, Korea

Objective : Malignant gliomas are the most common primary cerebral neoplasms in adults. Despite multimodality treatments, the prognosis for patients with malignant glioma remains poor. However, recently, the effectiveness of concomitant chemoradiotherapy (CCRT) with temozolomide (TMZ) has been reported. We report for the first time preliminary results of the treatment with CCRT of newly diagnosed malignant gliomas in Korean people.

Methods : Thirty-two patients over the age of 17 years with newly diagnosed and histologically confirmed high-grade gliomas (HGG), from June 2004 to August 2007 were the subjects of this study. There were 17 men and 15 women, with a median age of 53.5 years (range, 17-74). Pathologically, glioblastoma, anaplastic astrocytoma, anaplastic oligodendroglioma, and gliomatosis cerebri had been diagnosed in eighteen, eight, four, and two patients, respectively. These 32 patients were treated with CCRT with TMZ.

Results : The median follow-up period was 12.5 months (range 3-48). At the time of this analysis, 13 patients died and three patients had been lost to follow-up. There was no mortality caused by drug toxicity. The median progression-free survival (PFS) of these patients was 9.0 months, and the six-month PFS rate was 72.4%. The median overall survival (OS) was 26 months, and the one-year OS rate was 83.6%. The 18 patients with glioblastoma were analyzed separately from the other patients with HGG, and the median OS was 18 months, and the one-year OS rates were 81.8%. The median PFS was seven months, and the six-month PFS rate was 75.0%.

Conclusion : Our results are consistent with many other reports, confirming that CCRT with TMZ achieves good clinical outcomes in the treatment of HGG. Therefore, we suggest that CCRT with TMZ as adjuvant chemotherapy be considered as a standard therapy for patients with HGG.

KEY WORDS : Concomitant chemoradiotherapy · High-grade glioma · Glioblastoma · Temozolomide.

INTRODUCTION

Malignant gliomas are the most common primary cerebral neoplasm in adults. Unfortunately, their clinical courses are very rapid, and they commonly have miserable prognosis. There are several presumed reasons for the poor prognosis associated with high-grade glioma (HGG)^{1,4}. First, the tumor cells in HGG extensively infiltrate the surrounding brain

parenchyma, thereby limiting the overall utility of surgical resection. Second, the blood-brain barrier is an obstacle to the adequate delivery of chemotherapy agents to brain tumors. Third, HGG is refractory to most cancer cytotoxic agents, and the occasional responses are often short lived, with the rapid development of resistance, a direct consequence of genetic transformation and the tumor heterogeneity characteristic of this neoplasm. The expression of methylguanine methyltransferase (MGMT) is thought to be the major mechanism of this resistance. Therefore, surgical resection alone has limitations in the treatment of HGG. The standard therapy for malignant glioma consists of surgical removal to the extent that is safely feasible, followed by radiotherapy (RTx) with or without adjuvant

• Received : June 23, 2008 • Accepted : September 19, 2008
• Address for reprints : Chae-Yong Kim, M.D., Ph.D.
Department of Neurosurgery, Seoul National University Bundang Hospital, Seoul National University College of Medicine,
300 Gumi-dong, Bundang-gu, Seongnam 463-707, Korea
Tel : +82-31-787-7165, Fax : +82-31-787-4059
E-mail : chaeyong@snu.ac.kr

chemotherapy (CTx)^{16,17}. Regardless of this multimodality treatment, the prognosis for patients with malignant glioma remains unsatisfactory. The median survival for patients with glioblastoma is typically in the range of 9-12 months, with two-year survival rates of only 8%-12% and long-term survival rates of less than 5%^{6,8}. Considering the awful prognosis for malignant glioma, continuous research and the development of new treatment modalities and chemotherapeutic agents are urgently needed.

Stupp et al.^{13,15} reported that the concomitant administration of temozolomide (TMZ) with fractionated RTx, followed by up to six cycles of adjuvant TMZ, for newly diagnosed glioblastoma resulted in a clinically meaningful and statistically significant survival benefit, with minimal additional toxicity. Most recently, the effectiveness of this concomitant chemoradiotherapy (CCRT) has been reported in many studies^{2,11,12,14}.

We prospectively applied this CCRT with TMZ protocol to patients with HGG to determine whether it is also effective for Korean patients with malignant glioma.

Here, we report for the first time the results of CCRT with TMZ in the treatment of newly diagnosed HGG in Korea. We compare these results with previously published results. This is a preliminary report of a prospective study.

MATERIALS AND METHODS

Patients

From June 2004 to August 2007, patients over the age of 17 years with newly diagnosed and histologically confirmed HGG (World Health Organization [WHO] grade III or IV) were the subjects of this study. We included in the study not only glioblastoma but also WHO grade III glioma, which is well known to have an unfavorable prognosis.

The patients were required to have a Karnofsky performance status (KPS) ≥ 70 and adequate hematological, renal, and hepatic functions, defined as an absolute neutrophil count $\geq 1500/\mu\text{L}$, platelet count $\geq 100,000/\mu\text{L}$, hemoglobin ≥ 10 g/dL, serum creatinine and total serum bilirubin less than 1.5 times the upper limit of normal, aspartate aminotransferase and alanine aminotransferase less than 2.5 times the upper limit of normal, and alkaline phosphatase less than twice the upper limit of normal. Patients were not eligible if they were in poor medical condition, which could interfere with the oral administration of TMZ. All patients were required to give their written informed consent.

Treatment

The patients eligible for study inclusion were treated with

concomitant cranial RTx and CTx with TMZ, using the protocol proposed by Stupp et al. in 2002¹³. According to this protocol, the RTx component of the CCRT consisted of fractionated focal irradiation at a dose of 2 Gy per fraction given once a day, five days a week for a period of six weeks, a total dose of 60 Gy. The TMZ component of the CCRT was given at a dose of 75 mg/m² per day for seven days per week from the first day of RTx until the last day of RTx but for no longer than 49 days. TMZ was administered daily 1 hour before RTx, or in the morning on days without RTx. After a four-week break, the patients then received up to six cycles of adjuvant TMZ, according to the standard five-day schedule, every 28 days. The dose was 150 mg/m² for the first cycle and was increased to 200 mg/m² at the beginning of the second cycle if there were no hematological toxic effects. Prophylaxis for *Pneumocystis carinii* pneumonia was recommended during CCRT, or if lymphocyte counts decreased below 500/mm³.

Patient assessments

Baseline evaluations including patient history, physical examination, performance scale, hematology, and clinical chemistry assessments, and magnetic resonance (MR) images of the brain with gadolinium enhancement were performed before surgery. MR scans were performed before the first adjuvant treatment cycle and then every two or three months during the first year and every three months during the second year. The patients were categorized into four groups: complete response (complete disappearance of the targeted lesion), partial response (over 25% volume reduction of the targeted lesion), stable disease (less than 25% volume change in the targeted lesion), and progressive disease (over 25% volume increase in the targeted lesion), taking the initial baseline measurements as a reference.

Toxic effects were graded according to the National Cancer Institute Common Terminology Criteria for Adverse Events (version 3.0), with a score of 1 indicating mild adverse effects; a score of 2, moderate adverse effects; a score of 3, severe adverse effects; and a score of 4, life-threatening adverse effects.

Statistical analysis

Progression-free survival (PFS) was calculated from the date of diagnosis, when the pathology was confirmed, to the date of brain MR imaging that showed progression of the disease. Overall survival (OS) was calculated from the date of diagnosis until death or the date of the last follow-up. Both sets of data were analyzed with the Kaplan-Meier method using the SPSS statistical software package (release 12.0, 2004; SPSS Inc., Chicago, IL).

RESULTS

Patient characteristics

Thirty-two patients who were eligible for the study were enrolled. Their median age was 53.5 years (range, 17-74).

Table 1. Demographic characteristics of 32 patients at baseline

Characteristic	Radiotherapy plus temozolomide No. of patient (%)
Age (years)	
Median	53.5
Range	17-74
<50 yr	13 (41)
≥50 yr	19 (59)
Sex	
Male	17 (53)
Female	15 (47)
KPS at diagnosis	
70	2 (6)
80	8 (25)
90	16 (50)
100	6 (19)
KPS after CCRT	
60	1 (3)
70	4 (13)
80	3 (9)
90	20 (63)
100	2 (6)
Data missing	2 (6)
Extent of surgery	
GTR	8 (25)
NTR	2 (6)
STR	6 (19)
PR	2 (6)
STBx	14 (44)
Time from diagnosis to radiotherapy (weeks)	
Median	3.1
Range	1.2-6.0
Corticosteroid therapy	
During CCRT	
Yes	13 (41)
No	18 (56)
Data missing	1 (3)
During chemotherapy	
Yes	7 (22)
No	16 (50)
Data missing	9 (28)
Findings on pathological review	
Glioblastoma	18 (56)
Anaplastic astrocytoma	8 (25)
Anaplastic oligodendroglioma	4 (13)
Gliomatosis cerebri	2 (6)

KPS : Karnofsky performance status, CCRT : concomitant chemoradiotherapy, GTR : gross total removal, NTR : near-total removal, STR : subtotal removal, PR : partial removal, STBx : stereotactic biopsy.

The characteristics of the patients are summarized in Table 1. A histological review confirmed the diagnosis of glioblastoma in 18 patients (>50%), eight patients had anaplastic astrocytoma (WHO grade III), and four patients were diagnosed with anaplastic oligodendroglioma (WHO grade III).

The median time from diagnosis to the start of therapy was 3.1 weeks (range, 1.2-6.0). Table 2 summarizes the details of treatment. Seven patients showed complete remission, and 11 patients displayed partial remission. However, disease progression was observed in five patients.

Survival and progression

At the time of this analysis, 13 patients died, and three

Table 2. Disposition of Patients and Intensity of Treatment

Variable	Radiotherapy plus temozolomide No. of patient (%)
Radiotherapy	
Dose (Gy)	
Median	61.2
Range	45.0-64.8
Duration (weeks)	
Median	7.0
Range	0.9-8.0
Duration of CCRT+ chemotherapy (weeks)	
Median	26.5
Range	3.1-54.1
Duration of CCRT (weeks)	
Median	7
Range	3.1-8.0
Duration of temozolomide medication (days)	
Median	48
Range	6-54
Duration of chemotherapy (weeks)	
Median	20.6
Range	0.6-47.1
Cycles of temozolomide	
Median	6
Range	1-15
Dose of temozolomide (mg)	
120	1 (3)
150	17 (53)
200	3 (9)
150/200	7 (22)
Data missing	4 (13)
Response	
Complete remission	7 (22)
Partial remission	11 (34)
Stable disease	5 (16)
Progressive disease	5 (16)
Data missing	4 (13)

patients had been lost to follow-up after dropping out of the study. The CCRT was stopped for four patients in the middle of the course, because of their poor general condition. Adjuvant chemotherapy with TMZ was continued for an average of 5.6 cycles (range, 1-15) in 26 patients. Five patients

showed progressive disease during adjuvant chemotherapy. There was no mortality caused by drug toxicity. The mean duration of follow-up was 12.5 months (range, 3-48).

Based on the Kaplan-Meier method, the median PFS of these patients was 9.0 months (95% confidence interval, 5.8-12.2), and the six-month PFS rate was 72.4%. The median OS was 26 months (95% confidence interval, 8.3-43.7), and the one-year and two-year OS rates were 83.6% and 34.4%, respectively. The OS and PFS are summarized at Table 3. The response rate, including complete remission and partial remission, was 56%. Kaplan-Meier survival curves for HGG are illustrated in Fig. 1.

The 18 patients with glioblastoma were analyzed separately from the other patients with HGG, and the median OS was 18 months (95% confidence interval, 13.0-23.0), and the one-year and two-year OS rates were 81.8% and 40.9%, respectively. The median PFS was seven months (95%

Table 3. Overall survival and progression-free survival

Variable	Radiotherapy plus Temozolomide
OS (months) (n=28)	
Median	26.0
Range*	8.3-43.7
12-month OS	83.6%
24-month OS	34.4%
PFS (months) (n=29)	
Median	9.0
Range*	5.8-12.2
Six-month PFS	72.4%

*range : 95% confidence interval. OS : overall survival, PFS : progression free survival

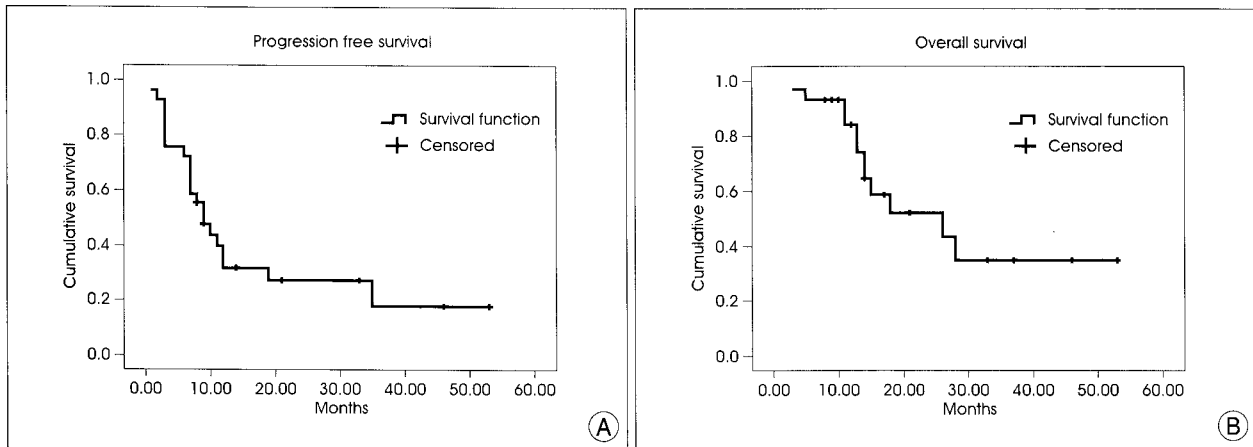


Fig. 1. Kaplan-Meier estimates of progression-free survival (PFS) (A) and overall survival (OS) (B) in patients suffering from primary high-grade glioma (WHO grade III and IV) treated with concomitant chemoradiotherapy with temozolomide. The median PFS of these patients is 9.0 months (95% Confidential Index, 5.8-12.2), and the six-month PFS rate is 72.4%. The median OS was 26 months (95% CI, 8.3-43.7), and the one-year and two-year OS rates are 83.6% and 34.4%, respectively.

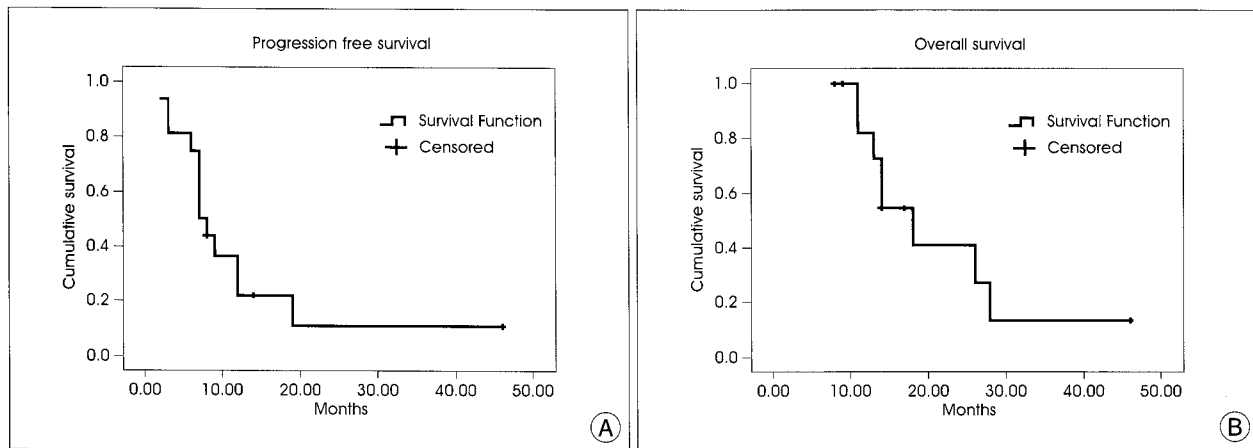


Fig. 2. Kaplan-Meier estimates of progression-free survival (PFS) (A) and OS (B) in 18 patients with glioblastoma (WHO grade IV) treated with concomitant chemoradiotherapy with temozolomide. The median PFS is seven months (95% CI, 5.4-8.6), and the six-month PFS rate is 75.0%. The median OS is 18 months (95% CI, 13.0-23.0), and the one-year and two-year OS rates are 81.8% and 40.9%, respectively.

confidence interval, 5.4-8.6), and the six-month PFS rate was 75.0%. Kaplan-Meier survival curves for glioblastoma only are illustrated in Fig. 2.

The prognosis by surgical respectability was also analyzed in these 28 patients. Gross total removal (GTR), near total removal (NTR) and subtotal removal (STR) were achieved in 15 patients, and partial removal (PR) or stereotactic biopsy were conducted in 13 patients. The mean OS of GTR, NTR and STR groups was 34.2 months, and the mean OS of STR and biopsy groups was 20.9 months. One-year and two-year OS rates of the former groups were 81.8% and 51.9%, respectively. One-year and two-year OS rates of the other groups were 84.6% and 52.9%. There was no significant difference in the aspect of OS rates between two groups. The median PFS of the GTR, NTR and STR groups was 10 months (95% confidence interval, 4.7-15.3), and the six-month PFS rate was 62.5%. On the other hands, the median PFS of the PR and biopsy groups was 6 months (95% confidence interval, 2.0-10.0), and the six-month PFS rate was 53.8%.

Toxicity

During CCRT, thrombocytopenia was detected in seven patients (22%). Grades 1 and 2 thrombocytopenia were documented in one patient and six patients, respectively. Two patients developed leukocytopenia, and one patient developed anemia. Overall, 10 patients (21%) had some type of hematological toxic effect. Nonhematological toxicities were mild. Nausea and vomiting were reported in 10 patients (21%), of whom eight had a grade 1 toxic effect and two had a grade 2 effect, but they were controlled well with antiemetics given before the chemotherapeutic medication. Mild muscle weakness was observed in one patient.

DISCUSSION

TMZ is a novel, second-generation, oral alkylating agent that has demonstrated antitumor activity in the treatment of malignant gliomas. TMZ has been approved for the treatment of recurrent malignant glioma but has also shown activity in patients with newly diagnosed malignant glioma^{1,5,13,18}.

In 2002, a promising regimen of CCRT with adjuvant TMZ CTx for patients with glioblastoma was reported¹³. With reference to this pilot study, we proceeded to apply CCRT, using the same protocol, to patients with HGG from 2004. Unlike the previous report, we extended the application of CCRT to treat WHO grade III gliomas, including anaplastic astrocytoma and anaplastic oligodendroglioma, as well as glioblastoma.

While our prospective study was in progress, some other reports of CCRT with TMZ for HGG were published. In 2005, the efficacy of postoperative TMZ radiochemotherapy in malignant glioma was reported in Germany⁷. According to that report, median PFS times were 7.3 and 8.7 months for primary glioblastoma and anaplastic astrocytoma, respectively, in patients treated with CCRT with TMZ. That study also reported that the median survival time for patients with glioblastoma was 14.6 months and the two-year survival rate for anaplastic astrocytoma was 33%. Our preliminary results for CCRT in patients with HGG are as good as those published outcomes.

As previously mentioned, a randomized prospective study of concomitant TMZ combined with RTx was reported in 2005 to be more effective than RTx alone in patients with newly diagnosed glioblastoma¹⁵. This randomized study compared RTx plus concomitant TMZ with RTx alone in patients with newly diagnosed, histologically confirmed glioblastoma. It reported that the median survival for patients with glioblastoma was 14.6 months with RTx plus TMZ and 12.1 months with RTx alone. The two-year survival rate was 26.5% with RTx plus TMZ and 10.4% with RTx alone. That study confirmed the effectiveness of CCRT with TMZ for glioblastoma patients. At present CCRT followed by a single-agent adjuvant treatment with the alkylating agent TMZ is widely accepted as the current standard care for patients with glioblastoma^{9,10,14}. Our results for the 18 patients with glioblastoma in our series are similar to the results of recent reports. Therefore, CCRT with TMZ can also be used as the standard protocol for the treatment of WHO grade IV glioma in Korea.

Unlike glioblastoma, there is no definite consensus about the standard regimen for WHO grade III gliomas, such as anaplastic astrocytoma and anaplastic oligodendroglioma. For example, a phase III trial of CTx plus RTx using procarbazine, lomustine, and vincristine (PCV) to treat anaplastic oligodendroglioma was published in 2006³. This study concluded that PCV plus RTx did not prolong the survival of patients with anaplastic oligodendroglioma and the longer PFS was associated with significant toxicity. Therefore, it is essential to verify the role of TMZ in the treatment of WHO grade III glioma. Since the above-mentioned landmark study of Stupp et al. in 2005, there have been many phase II and III clinical studies of the treatment of HGG with TMZ in adults^{4,9}. These trials have reported good outcomes, and our present results for patients with WHO grade III and IV gliomas are also favorable, with tolerable toxicity. In our study, the median PFS and OS of patients with HGG treated with CCRT were nine months and 26 months, respectively. Our results are consistent with

those of many other reports, confirming that CCRT with TMZ adjuvant CTx offers good clinical outcomes in the treatment of HGG. Therefore, we propose CCRT with TMZ as an alternative approach for patients with WHO grade III gliomas, as well as for those with glioblastoma.

The analysis of MGMT and the loss of heterozygosity at chromosomes 1p/19q were not separately investigated in this study, but research into these is ongoing. The correlation with these factors will be described in our final report. An interrelationship between racial differences and treatment results may also exist, and studies of this will be necessary in the future.

CONCLUSION

This is the first report of results of CCRT with TMZ in the treatment of HGG in Korea. This Korean trial of CCRT and adjuvant chemotherapy with TMZ in HGG patients demonstrated survival outcomes consistent with those of other previous trials, with tolerable toxicities. Therefore, we suggest that CCRT with TMZ should be considered as a standard therapy in Korea for patients with HGG. To confirm this, a multicenter, meta-analysis and a randomized trial with a large number of patients are required in the near future.

References

1. Brada M, Hoang-Xuan K, Rampling R, Dietrich PY, Dirix LY, Macdonald D, et al : Multicenter phase II trial of temozolomide in patients with glioblastoma multiforme at first relapse. *Ann Oncol* 12 : 259-266, 2001
2. Brandes AA, Franceschi E, Tosoni A, Blatt V, Pession A, Tallini G, et al : MGMT promoter methylation status can predict the incidence and outcome of pseudoprogression after concomitant radiochemotherapy in newly diagnosed glioblastoma patients. *J Clin Oncol* 26 : 2192-2197, 2008
3. Cairncross G, Berkey B, Shaw E, Jenkins R, Scheithauer B, Brachman D, et al : Phase III trial of chemotherapy plus radiotherapy compared with radiotherapy alone for pure and mixed anaplastic oligodendroglioma : Intergroup Radiation Therapy Oncology Group Trial 9402. *J Clin Oncol* 24 : 2707-2714, 2006
4. Corsa P, Parisi S, Raguso A, Troiano M, Perrone A, Cossa S, et al : Temozolomide and radiotherapy as first-line treatment of high-grade gliomas. *Tumori* 92 : 299-305, 2006
5. Friedman HS, McLendon RE, Kerby T, Dugan M, Bigner SH, Henry AJ, et al : DNA mismatch repair and O6-alkylguanine-DNA alkyltransferase analysis and response to Temodal in newly diagnosed malignant glioma. *J Clin Oncol* 16 : 3851-3857, 1998
6. Galanis E, Buckner J : Chemotherapy for high-grade gliomas. *Br J Cancer* 82 : 1371-1380, 2000
7. Kocher M, Kunze S, Eich HT, Semrau R, Muller RP : Efficacy and toxicity of postoperative temozolomide radiochemotherapy in malignant glioma. *Strahlenther Onkol* 181 : 157-163, 2005
8. Mahaley MS Jr, Mettlin C, Natarajan N, Laws ER Jr, Peace BB : National survey of patterns of care for brain-tumor patients. *J Neurosurg* 71 : 826-836, 1989
9. Perry J, Laperriere N, Zuraw L, Chambers A, Spithoff K, Cairncross JG : Adjuvant chemotherapy for adults with malignant glioma : a systematic review. *Can J Neurol Sci* 34 : 402-410, 2007
10. Sathornsumetee S, Rich JN, Reardon DA : Diagnosis and treatment of high-grade astrocytoma. *Neurol Clin* 25 : 1111-1139, 2007
11. Siker ML, Chakravarti A, Mehta MP : Should concomitant and adjuvant treatment with temozolomide be used as standard therapy in patients with anaplastic glioma? *Crit Rev Oncol Hematol* 60 : 99-111, 2006
12. Simon JM, Toubiana T, Lang P, Taillibert S, Mazon JJ : [Radiotherapy for glioblastomas : from radiobiology to concomitant chemotherapy]. *Cancer Radiother* 9 : 322-331, 2005
13. Stupp R, Dietrich PY, Ostermann Kraljevic S, Pica A, Maillard I, Maeder P, et al : Promising survival for patients with newly diagnosed glioblastoma multiforme treated with concomitant radiation plus temozolomide followed by adjuvant temozolomide. *J Clin Oncol* 20 : 1375-1382, 2002
14. Stupp R, Hegi ME, Gilbert MR, Chakravarti A : Chemoradiotherapy in malignant glioma : standard of care and future directions. *J Clin Oncol* 25 : 4127-4136, 2007
15. Stupp R, Mason WP, van den Bent MJ, Weller M, Fisher B, Taphoorn MJ, et al : Radiotherapy plus concomitant and adjuvant temozolomide for glioblastoma. *N Engl J Med* 352 : 987-996, 2005
16. Walker MD, Alexander E Jr, Hunt WE, MacCarty CS, Mahaley MS Jr, Mealey J Jr, et al : Evaluation of BCNU and/or radiotherapy in the treatment of anaplastic gliomas. A cooperative clinical trial. *J Neurosurg* 49 : 333-343, 1978
17. Walker MD, Green SB, Byar DP, Alexander E Jr, Batzdorf U, Brooks WH, et al : Randomized comparisons of radiotherapy and nitrosoureas for the treatment of malignant glioma after surgery. *N Engl J Med* 303 : 1323-1329, 1980
18. Yung WK, Albright RE, Olson J, Fredericks R, Fink K, Prados MD, et al : A phase II study of temozolomide vs. procarbazine in patients with glioblastoma multiforme at first relapse. *Br J Cancer* 83 : 588-593, 2000