

## Clinical and Clinicopathological Findings of Naturally Occurring Hyperadrenocorticism in Dogs: A Retrospective Study of 17 Cases

Sang-Gil Kang<sup>†</sup>, Jong-Hyun Yoo<sup>†\*</sup>, Chul Park<sup>\*\*\*</sup> and Hee-Myung Park<sup>\*\*1</sup>

*DongSeoul Animal Hospital, Seoul 143-803, Korea*

*\*BK21 Program of Integrative Network Systems for Veterinarians in Basic Science, Industrial Animals and Preventive Medicines, Konkuk University, Seoul 143-701, Korea*

*\*\*Department of Veterinary Internal Medicine, College of Veterinary Medicine, Konkuk University, Seoul 143-701, Korea*

*\*\*\*Department of Medicine and Epidemiology, School of Veterinary Medicine, University of California, Davis, CA 95616, USA.*

(Accepted: November 17, 2008)

**Abstract :** A retrospective study of 17 dogs with hyperadrenocorticism (HAC) was performed to evaluate the clinical and clinicopathological outcomes in dogs with pituitary-dependent HAC or adrenal gland-dependent HAC. Sixteen dogs were monitored at day 10, 30 and 90 then every 3 month after first presentation. In each examination, physical examination and ACTH stimulation test and client questionnaire were performed. In 17 cases, eight dogs were successfully treated with mitotane therapy (median dose 16.7 mg/kg; range 5.3 to 50 mg/kg, SID); another one dog showed favorable response, but the clients declined to further treatment before the full control of the disease had been achieved; four dogs showed poor response to treatment. One dog was euthanized due to septicemia. These results showed canine HAC can be medically managed successfully without side effects at the doses used in this study.

**Key words :** dog, hyperadrenocorticism, mitotane.

### Introduction

Hyperadrenocorticism (HAC) or Cushing's disease is one of the most commonly-occurring endocrinological disorders in dogs. A variety of clinical signs are caused by elevated serum cortisol levels, which arise from the underlying abnormality in the pituitary or adrenal glands (20). HAC in dogs is differentiated to pituitary-dependent hyperadrenocorticism (PDH) and adrenal tumors (ATs), which accounts for approximately 85 % and 15 % of cases respectively (2). A pituitary tumor secretes excess corticotrophin, which, in turn, stimulates adrenal gland secretion of cortisol. The anterior lobe of pituitary gland is involved in 80 % to 85 % of PDH cases. ATs secrete excess cortisol in an automatic manner. These tumors are reported to be approximately 50 % benign and 50 % malignant (2).

In general, clinical signs are relatively similar in both PDH and ATs (7,20). Occasionally, a large pituitary tumor can cause neurologic signs of a space-occupying nature (13). However, the plans for treatment are different depending on the location of the lesions. For instance, adrenalectomy can be performed as an option for therapy in ATs, and for PDH, hypophysectomy may be chosen (20). Medical therapy can also vary with types; for example, selegiline can be only

option for PDH (20), and response to therapy with mitotane is different for PDH and ATs (11,12). Thus, it is important to differentiate between PDH and ATs for optimal treatments of HAC in dogs. Since no test for the diagnosis or differentiation of HAC is perfect, retrospective study for comparing among the clinical signs, anatomical etiology, results of tests, and responses to medicine provides vital information for accurate diagnosis and treatment. To our knowledge, there have been no retrospective studies of canine HAC associated with clinical finding, diagnosis and treatment response in Korea.

The purpose of this study is to evaluate the clinical and clinicopathological outcomes in seventeen dogs with naturally occurring PDH and ATs.

### Materials and Methods

#### Cases

This study is a retrospective analysis of data from dogs presented to the Department of Veterinary Internal Medicine, Veterinary Medical Teaching Hospital (VMTH) of Konkuk University between May, 2002 and April, 2005. Each dog has been suspected of having HAC on the basis of history and the results of physical examination, complete blood count, serum biochemical analysis, and urinalysis. The final diagnosis of HAC have been made with at least one abnormal result of following screening tests in the dogs

<sup>†</sup>The first two authors contributed equally to this work.

<sup>1</sup>Corresponding author.

E-mail : parkhee@konkuk.ac.kr

**Adrenocorticotrophic hormone (ACTH) stimulation test**

Heparinized blood samples were collected before, and 1 hr after the intramuscular administration of 250 µg of tetracosactrin (Synacthen®, 0.25 mg, IM, Novartis Pharma, Swiss). Post-ACTH plasma cortisol concentration greater than 20 µg/dl were consistent with diagnosis of HAC.

**High dose dexamethasone suppression test (HDDST)**

The HDDS test is performed to distinguish between ADH and PDH. Each of the following two criteria was considered as a proof of adrenal suppression in a HDDST (indicative of PDH): a four-hour postdexamethasone plasma cortisol concentration less than 50% of the basal plasma concentration or a four-hour postdexamethasone plasma concentration less than 1.4 µg/dl. To be included in this study (i.e., suspect ADH), each dog must have had test results indicative of no suppression.

**Ultrasonography**

The dogs were placed in dorsal recumbency. None of the dogs were sedated or anesthetized. A real-time mechanical sector scanner with a 7.5-megahertz (MHz) transducer was used. Ultrasonographic examination of the adrenal glands was taken as according to the procedure described by Saunders (20).

An adrenal gland tumor was defined as adrenomegaly with loss of the normal shape and structure. Tumor size was determined by measuring the greatest craniocaudal and dorsoventral dimension in a longitudinal plane.

Contralateral adrenal glands were also measured in the longitudinal plane. Length was defined as the greatest craniocaudal dimension, and thickness was defined as the greatest dorsoventral dimension perpendicular to the long axis.

**Magnetic resonance imaging (MRI)**

Brain MRI scanning of one case was performed with a 0.2-Tesla scanner (E-scan®, ESAOTE, Genova, Italy) to confirm the PDH. T1- and T2-weighted images were obtained in transverse, sagittal, and dorsal planes.

**Results**

During the study period, HAC was diagnosed in 17 dogs based on history, clinical examination, routine blood analy-

**Table 1.** Breed distribution in the 17 cases with naturally occurring canine hyperadrenocorticism (HAC)

Breed	Breed proportions of HAC in 17 cases	
	Number	Percentage
Miniature pinscher	1	5.8
Mixed breed	3	17.6
Pomeranian	3	17.6
Toy poodle	3	17.6
Yorkshire	7	41.2
Total	17	100

sis, dynamic endocrine studies, and MRI.

The number and percentage of breeds of dogs investigated are described in Table 1. The incidence rate of canine HAC was highest in Yorkshire terrier (41.2 %). Then there followed in Pomeranian (17.6 %), Toy poodle (17.6 %), and mixed breed (17.6 %), Miniature Pinscher (5.8 %) in order of frequency.

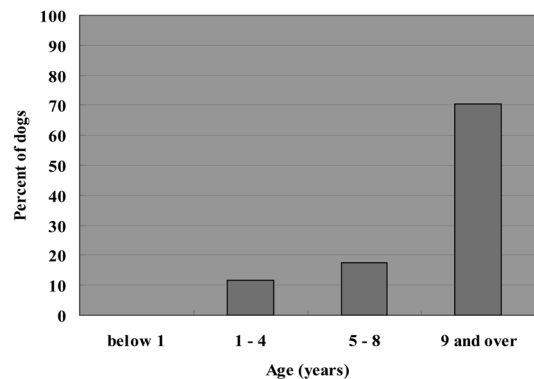
Mean age of dogs affected with HAC was more than 10 years old (10.6 ± 3.20 years; Fig 1). Eight (47.1 %) of eleven dogs were female and nine (52.9 %) dogs were male. Thus there was no significant difference in sex distribution among cases. The mean body weight of the cases was 4.8 ± 2.6 kg (mean ± SD) (ranged from 0.98 to 14 kg). Housing environment of the case dogs was all indoor.

Post-ACTH cortisol was >20 µg/dl in fifteen cases in seventeen dogs with 88 % sensitivity. HDDS was done in 13 cases of 17 dogs. Of them, 12 dogs was supposed to be PDH, and one dog showed elevated cortisol level 8 hrs after high-dose dexamethasone administration (Table 2).

Of 16 cases with mitotane therapy, 12 cases maintained normal cortisol level. However, other four cases did not show improved clinical signs. Of 12 cases showing favorable response to mitotane therapy, one dog died for unknown reason and another dog was euthanized due to septicemia. Further mitotane administration was terminated in two cases due to the appearance of hypoadrenocorticism and hepatitis respectively. Eight dogs had been successfully managed for 8.4 ± 3.7 months until April, 2005.

Not less than 50 % of the patient with HAC manifested clinical signs including PU/PD, polyphagia, and skin problems at initial physical examination (Table 3). Abdominal distension and muscle weakness were observed in five cases of 17 dogs. Complicated diseases in cases of HAC at presentation were cataract (53 %), respiratory disease (24 %), diabetes mellitus (18 %), and urinary tract infection (6 %) in order of frequency (Table 3).

Ultrasonographic examination revealed right adrenal gland mass in the case 6 which was diagnosed as ATs (Fig 2).



**Fig 1.** Percentage of dogs in each age category with naturally occurring canine hyperadrenocorticism (HAC). A total of 17 dogs with HAC from Konkuk University Teaching Hospital were included.

**Table 2.** Results of adrenocorticotropin hormone (ACTH) stimulation test and high dose dexamethasone suppression test (HDDST) and therapeutic progress with mitotane in 17 dogs with hyperadrenocorticism (HAC)

Case	Plasma concentration of cortisol ( $\mu\text{g/dl}$ )					Classification	Mitotane <sup>†</sup>	Complications
	ACTHST*		HDDST					
	0 hr	1 hr	0 hr	4 hr	8 hr			
1	3.3	42.1	ND	ND	ND	Unknown	NR <sup>‡</sup>	
2	4.7	31.3	9.5	ND	0.7	PDH	13 mo.	Death for unknown reason
3	9.62	19.9	ND	ND	ND	Unknown	NR	
4	12.3	28.1	ND	ND	ND	Unknown	NR	
5	8.6	27.5	ND	ND	ND	Unknown	NR	
6	3.6	92.8	4.8	3.2	5.3	ADH	14 mo.	
7	3.5	25.6	2.7	1.8	1.2	PDH	12 mo.	
8	6.5	23.5	1.4	ND	0.6	PDH	2 mo.	Euthanized due to septicemia
9	0.8	18.6	3.8	ND	0.9	PDH	8 mo.	
10	1.2	21.5	2.1	1.2	1.3	PDH	7 mo.	
11	4.5	59.8	7.3	1.5	1.3	PDH	8 mo.	
12	2.8	40.2	11.6	ND	5.2	PDH	1 mo.	Hypoadrenocorticism
13	6.5	30.2	4.6	0.9	0.8	PDH	6 mo.	
14	3.4	30.2	1.2	0.5	0.5	PDH	1 mo.	Hepatitis
15	0.8	20.9	1.6	0.7	0.7	PDH	<sup>†</sup> NT	
16	1.1	24.6	6.6	0.9	0.7	PDH	2 mo.	
17	6.6	30.2	9.5	ND	0.7	PDH	10 mo.	

Mean  $\pm$  SD<sup>§</sup> 4.40  $\pm$  3.42 32.3  $\pm$  19.7 4.34  $\pm$  3.18 1.34  $\pm$  0.86 1.68  $\pm$  1.79

\*ACTHST, ACTH stimulation test; <sup>‡</sup>NR, No response to mitotane therapy; <sup>†</sup>NT, this case was not treated by owner's decline; <sup>§</sup>SD, Standard deviation. <sup>†</sup> A period of mitotane administration.

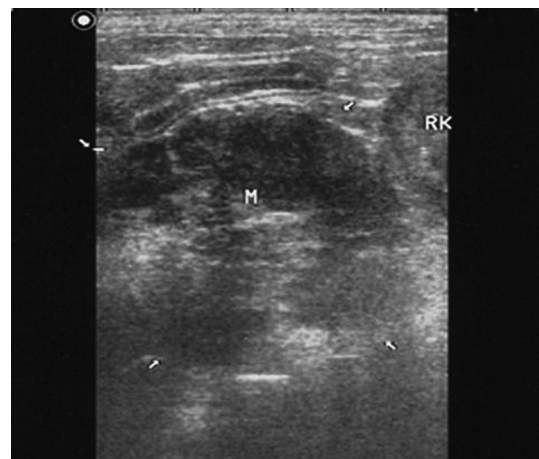
**Table 3.** Manifestation of clinical signs and complicated diseases in 17 dogs with HAC at presentation

Clinical signs	Affected cases (%)
Polyuria/polydypsia	11 (65 %)
Polyphagia/obesity	10 (59 %)
Skin problem	10 (59 %)
Abdominal distension	5 (29 %)
Muscle weakness	5 (29 %)
Complicated disease	
Diabetes mellitus	3 (18 %)
Cataract	9 (53 %)
Urinary tract infection (UTI)	1 (6 %)
Respiratory disease	4 (24 %)

In MRI study, hyperintensified signal can be seen in thalamic region suggesting pituitary tumor in sagittal and axial view (Fig 3).

## Discussion

Most of HAC cases in this study were small breed dogs at a median age of more than 10 years. Yorkshire terrier dogs



**Fig 2.** Ultrasound image in a sagittal plane. Right adrenal gland mass (M) adjacent to right kidney (RK) was detected on ultrasonography (white arrows).

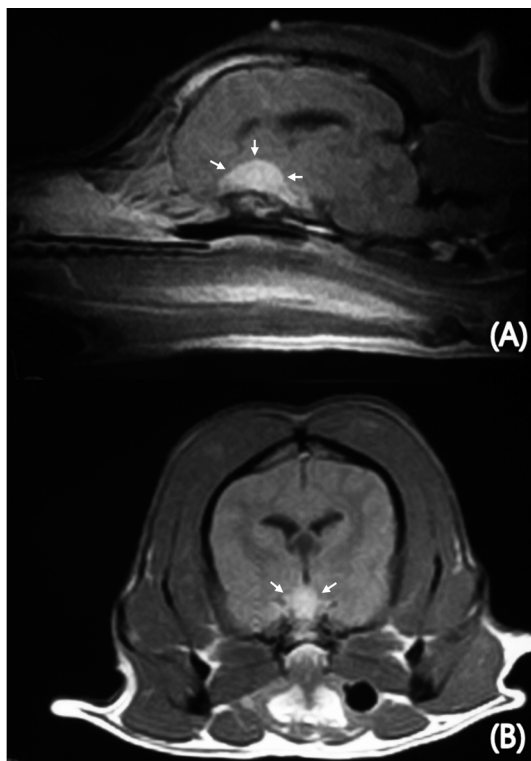
were the most frequently affected breed (41.2 %). This result is consistent with other report (1). However, there was no obvious difference in sex predisposition in this study.

Diagnostic imaging including radiography, abdominal ultrasonography, CT, and MRI can be useful to assess adrenal

structure and differentiate the presence of an adrenal mass. Although ultrasonography is not recommended for a screening test of HAC (2), it is of benefit in defining more precise location and size of adrenal masses as is the case for ATs of the present study. MRI has been used not as a differentiation test but to assess the size of a pituitary mass in known cases of PDH. In MRI study of canine PDH cases without neurologic signs, a pituitary mass was often visualized. According to several reports (3,6), typically, pituitary tumors with neurologic signs were greater than 1 cm in diameter, but a Dachshund with a 5 mm-diameter mass also had the signs. Most tumors are contrast enhancing on MRI (3,6).

The most common neurologic sign associated with canine PDH is stupor (15). Other neurological manifestations were not CNS specific and include lethargy, inappetence, and mental dullness (22). The benefits of routine MR imaging screening of all dogs with PDH for a detectable mass have been considered (3,6) because it would be difficult to distinguish between large and microscopic pituitary tumors before the onset of neurologic signs based on endocrine test results (13); however, the clinical significance of a mass without neurologic complications is unknown. In a one-year follow-up study with 13 dogs affected by PDH, there is no way to predict which masses are likely to grow or become clinically apparent (4).

Endocrine tests including ACTH stimulating test and



**Fig 3.** Magnetic resonance images (MRI) of the brain. T1-weighted sagittal view (A) and axial view (B) of MRI. Hyperintensity is visible in thalamic region suggesting pituitary tumor (white arrow).

HDDST were conducted to distinguish between PDH and ATs (Table 2). Even though these tests need added expense and time, differentiation should be done because knowing which form is present is important in deciding which therapy to use and in providing a prognosis. If mitotane is chosen for treatment, dogs with an ATs should be given higher induction and maintenance doses, and induction should continue for longer periods of time (7,12). In addition, the prognosis in dogs with PDH is better than in those with ATs (11,12).

The common clinical signs of the present dogs were polyuria and polydipsia, polyphagia/obesity, and skin problems. Although most patients showed those clinical signs, these signs were not always characteristic in every case. Especially, case 11 did not show any clinical signs. Thus, clinical signs are not specific in dogs associated with HAC and dynamic endocrine test is necessary for diagnosis.

On hematology, lymphopenia and neutrophilia were revealed in approximately 41 % of the patients (Table 4). Alkaline phosphatase activity was elevated in 76 % of the patients, and hypercholesterolemia and hypertriglyceridemia were detected in 35 % (Table 4).

Recurrent urinary tract infection is common problem in dogs with HAC (20). In the present study, concurrent urinary tract infection (UTI) was detected in only one patient. Forty-six percent of dog with HAC is reported to be complicated with concurrent UTI (10). Forrester (10) demonstrated that urinary tract infection was presented in 46 % of dogs with HAC in retrospective study of urinary infection with HAC or diabetes mellitus or both. This result of our study may be associated with usage of antibiotics prior to presentation. In addition, Forrester (9) suggested that urinary tract infection of dogs was absent in experimentally induced HAC.

The origin of the excessive cortisol production was mainly pituitary gland tumor and PDH was diagnosed by both ACTH stimulation test and HDDST in 11 of 13 dogs. Total 65 % of the HAC patients were diagnosed as PDH in this study. The mean pre-ACTH cortisol concentration was 4.4  $\mu\text{g}/\text{dl}$  and post-ACTH cortisol was 32.3  $\mu\text{g}/\text{dl}$ . Reference range of healthy dogs is 0.5-6.0  $\mu\text{g}/\text{dl}$  and 6-17  $\mu\text{g}/\text{dl}$ , respec-

**Table 4.** The frequency of clinicopathological abnormalities of 17 dogs with naturally occurring HAC

Complete blood counts		Serum biochemistry	
Erythrocytosis	29 % (5)	Elevated ALP	76 % (13)
Leukocytosis	24 % (4)	Elevated Tchol	41 % (7)
Lymphopenia	47 % (8)	Hypertriglyceridemia	35 % (6)
Neutrophilia	41 % (7)	Hyperglycemia	18 % (3)
		Hypercalcemia	18 % (3)
		Hypokalemia	12 % (2)

Parenthesis (), number of dogs in the present 17 cases with HAC; ALP, Alkaline phosphatase; Tchol, Total cholesterol

tively. In case of HAC dog, post-ACTH cortisol concentration might be more than 22 µg/dl. In HDDST, pre-dexamethasone cortisol concentration was 4.34 µg/dl and post-dexamethasone cortisol were 1.34 and 1.68 µg/dl in 4 hours and 8 hours after administration. Low dexamethasone suppression test is used for screening test for HAC in dogs, but its diagnostic accuracy is reported to be lower than that of ACTH (21) and showed no suppression in some cases with ATs (16). In general, post-dexamethasone cortisol is less than 1.4 µg/dl or < 50 % of baseline in HAC (2). Other than these tests described above, the urinary cortisol/creatinine ratio had a high diagnostic accuracy (17) and 17-OH-progesterone response to ACTH administration can possible another value for undiagnosed cases of ATs (5,16,18).

Mitotane therapy is generally more required in ATs than PDH (7). In case of bilateral adrenocortical neoplasms in dogs, the prognosis is poor because of persistent HAC during mitotane therapy (8). Relapse rate in ATs is high (63 %) in spite of high maintenance dosage (98.1 - 212.4 mg/kg/wk) (12) while relapse rate in PDH was reported to be 55 % (11).

Sixteen of the 17 patients were received medical treatment with mitotane. Except four patients, they showed good response and successfully managed by mitotane therapy. Recent study demonstrated that trilostane, a 3 beta-hydroxysteroid dehydrogenase inhibitors, was safe for treatment of HAC with similar efficacy with mitotane therapy (14,19).

In conclusion, Yorkshire terrier was most frequently affected breed and the age of onset was more than 9 years in 71 % of the dogs with HAC. Medical therapy can manage HAC successfully if client is cooperative to treat this endocrinopathy. This result showed good efficacy of mitotane without relapse compared to a previous report with approximately 50 % of relapse rate (11), and then could help veterinarians to use mitotane for the management of canine HAC.

Pituitary tumors are the main cause of canine HAC, and older, small breed dogs have the predisposition factor. Close monitoring and communication with the client are very important in management of HAC. Additionally, canine HAC can be managed effectively with medical therapy using mitotane.

### Acknowledgments

This work was supported by the Korea Science and Engineering Foundation (KOSEF) grant funded by the Korea government (MEST) (R11-2002-103) and the Korea Research Foundation Grant funded by the Korean Government (MOEHRD, Basic Research Promotion Fund) (KRF-2008-314-E00246).

### References

1. Barker EN, Campbell S, Tebb AJ, Neiger R, Herrtage ME, Reid SW, Ramsey IK. A comparison of the survival times of dogs treated with mitotane or trilostane for pituitary-dependent hyperadrenocorticism. *J Vet Intern Med* 2005; 19: 810-815.
2. Behrend EN, Kemppainen RJ. Diagnosis of canine hyperadrenocorticism. *Vet Clin North Am Small Anim Pract* 2001; 31: 985-1003.
3. Bertoy EH, Feldman EC, Nelson RW, Duesberg CA, Kass PH, Reid MH, Dublin AB. Magnetic resonance imaging of the brain in dogs with recently diagnosed but untreated pituitary-dependent hyperadrenocorticism. *J Am Vet Med Assoc* 1995; 206: 651-656.
4. Bertoy EH, Feldman EC, Nelson RW, Dublin AB, Reid MH, Feldman MS. One-year follow-up evaluation of magnetic resonance imaging of the brain in dogs with pituitary-dependent hyperadrenocorticism. *J Am Vet Med Assoc* 1996; 208: 1268-1273.
5. Chapman PS, Mooney CT, Ede J, Evans H, O'Connor J, Pfeiffer DU, Neiger R. Evaluation of the basal and post-adrenocorticotrophic hormone serum concentrations of 17-hydroxyprogesterone for the diagnosis of hyperadrenocorticism in dogs. *Vet Rec* 2003; 153: 771-775.
6. Duesberg CA, Feldman EC, Nelson RW, Bertoy EH, Dublin AB, Reid MH. Magnetic resonance imaging for diagnosis of pituitary macrotumors in dogs. *J Am Vet Med Assoc* 1995; 206: 657-662.
7. Feldman EC, Nelson RW, Feldman MS, Farver TB. Comparison of mitotane treatment for adrenal tumor versus pituitary-dependent hyperadrenocorticism in dogs. *J Am Vet Med Assoc* 1992; 200: 1642-1647.
8. Ford SL, Feldman EC, Nelson RW. Hyperadrenocorticism caused by bilateral adrenocortical neoplasia in dogs: four cases (1983-1988). *J Am Vet Med Assoc* 1993; 202: 789-792.
9. Forrester SD, Martínez NI, Panciera DL, Moon ML, Pickett CR, Ward DL. Absence of urinary tract infection in dogs with experimentally induced hyperadrenocorticism. *Res Vet Sci* 2003; 74: 179-182.
10. Forrester SD, Troy GC, Dalton MN, Huffman JW, Holtzman G. Retrospective evaluation of urinary tract infection in 42 dogs with hyperadrenocorticism or diabetes mellitus or both. *J Vet Intern Med* 1999; 13: 557-560.
11. Kintzer PP, Peterson ME. Mitotane (o,p'-DDD) treatment of 200 dogs with pituitary-dependent hyperadrenocorticism. *J Vet Intern Med* 1991; 5: 182-190.
12. Kintzer PP, Peterson ME. Mitotane treatment of 32 dogs with cortisol-secreting adrenocortical neoplasms. *J Am Vet Med Assoc* 1994; 205: 54-61.
13. Kipperman BS, Feldman EC, Dybdal NO, Nelson RW. Pituitary tumor size, neurologic signs, and relation to endocrine test results in dogs with pituitary-dependent hyperadrenocorticism: 43 cases (1980-1990). *J Am Vet Med Assoc* 1992; 201: 762-767.
14. Neiger R, Ramsey I, O'Connor J, Hurley KJ, Mooney CT. Trilostane treatment of 78 dogs with pituitary-dependent hyperadrenocorticism. *Vet Rec* 2002; 150: 799-804.
15. Nelson RW, Ihle SL, Feldman EC. Pituitary macroadenomas and macroadenocarcinomas in dogs treated with mitotane for pituitary-dependent hyperadrenocorticism: 13 cases (1981-1986). *J Am Vet Med Assoc* 1989; 194: 1612-1617.
16. Norman EJ, Thompson H, Mooney CT. Dynamic adrenal function testing in eight dogs with hyperadrenocorticism associated with adrenocortical neoplasia. *Vet Rec* 1999;

- 144: 551-554.
17. Rijnberk A, van Wees A, Mol JA. Assessment of two tests for the diagnosis of canine hyperadrenocorticism. *Vet Rec* 1988; 122: 178-180.
  18. Ristic JM, Ramsey IK, Heath EM, Evans HJ, Herrtage ME. The use of 17-hydroxyprogesterone in the diagnosis of canine hyperadrenocorticism. *J Vet Intern Med* 2002; 16: 433-439.
  19. Ruckstuhl NS, Nett CS, Reusch CE. Results of clinical examinations, laboratory tests, and ultrasonography in dogs with pituitary-dependent hyperadrenocorticism treated with trilostane. *Am J Vet Res* 2002; 63: 506-512.
  20. Saunders HM. Adrenal disease. Proceedings, 2nd International Symposium Vet Echography 1993; 31-34.
  21. Van Liew CH, Greco DS, Salman MD. Comparison of results of adrenocorticotrophic hormone stimulation and low-dose dexamethasone suppression tests with necropsy findings in dogs: 81 cases (1985-1995). *J Am Vet Med Assoc* 1997; 211: 322-325.
  22. Wood FD, Pollard RE, Uerling MR, Feldman EC. Diagnostic imaging findings and endocrine test results in dogs with pituitary-dependent hyperadrenocorticism that did or did not have neurologic abnormalities: 157 cases (1989-2005). *J Am Vet Med Assoc* 2007; 231: 1081-1085.