

Bilateral Congenital Deafness in a White Bull Terrier; Brainstem Auditory Evoked Response Findings

Byeong-Teck Kang, So-Young Lee, Dong-In Jung*, Hyung-Joong Kim**, Eung-Je Woo** and Hee-Myung Park¹

Department of Veterinary Internal Medicine, College of Veterinary Medicine, Konkuk University, Seoul 143-701, Korea

**Department of Veterinary Internal Medicine, College of Veterinary Medicine, Gyeongsang National University,
Jinju 660-701, Korea*

***College of Electronics and Information, Kyunghee University, Seoul 446-701, Korea*

(Accepted: November 17, 2008)

Abstract : A 2-month-old, intact female white Bull Terrier presented because of suspected deafness. The coat color was predominantly white and the iris color, of both eyes, was brown. The dog did not respond to the owner's voice when the sound stimuli were presented outside of the visual field; however, the dog responded to visual gestures. The other physical, neurological, otoscopic, radiographic, and blood examinations were unremarkable. To assess the apparent deafness, brainstem auditory evoked responses (BAER) were recorded and analyzed in the dog with suspected deafness as well as a normal littermate. The response in the normal littermate consisted of a series of five wave peaks (I-V) with decreased amplitude and prolonged latency as the stimulus intensity decreased. The BAER from the dog suspected of deafness appeared as a flat line and did not reveal identifiable peaks that corresponded to those found in the normal littermate. Thus, congenital, sensorineural and bilateral deafness was confirmed by the BAER.

Key words : brainstem auditory evoked response, congenital deafness, white Bull Terrier

Introduction

Canine deafness is identified with increasing frequency because of the heightened awareness about this disorder among owners, breeders and clinicians (8). The most commonly diagnosed forms of deafness are congenital sensorineural deafness; conductive deafness associated with otitis externa and/or media and late-onset sensorineural deafness (associated with chronic otitis interna, otitis media or both, ototoxicity, noise trauma, or presbycusis in older animals) (2,8).

Behavioral testing can be used by veterinarians to attempt to diagnose deafness, but this approach is often unreliable and subjective (1). Methods of diagnosing audiological or otological disorders in veterinary medicine have included electronencephalographic audiometry, respiratory audiometry, tympanometry, auditory evoked responses, and acoustic reflexes (5). Among them, hearing can be definitively assessed by brainstem auditory evoked responses (BAER), also known as brainstem auditory evoked potentials (BAEP) or auditory brainstem responses (ABR) (7). Currently, the BAER is the standard validated technique used for the assessment of congenital sensorineural deafness in dogs; deafness has been reported in over 80 breeds of dogs (2,8).

Previously, the use of the BAER for the evaluation of con-

ductive deafness has been reported in Korea (12). However, this is the first report of how the BAER was used to diagnose bilateral congenital deafness in a white Bull Terrier (BT).

Case report

A 2-month-old, intact female white BT presented because of suspected deafness. This dog was from a litter of five. Except for an apparent hearing difficulty, the dog was nearly equal in size and weight compared to those of the other littermates. The granddam on the dam's side was suspected of having hearing loss. There was no historical evidence of visual deficits, head trauma or exposure to ototoxic drugs. The coat color was predominantly white, with a brindle patch on the nose. The iris color, of both eyes, was brown. The dog did not respond to the owner's voice when the sound stimuli were presented outside of the visual field; however, the dog did respond to visual gestures. There were no startle responses elicited to sudden loud noises. Otoscopic examination showed that both tympanic membranes were intact and the external ear canals were clean and normal in appearance. The radiology examinations of the tympanic bulla were performed in the dorsolateral, lateral-oblique and rostrocaudal (with mouth open) projections. There were no abnormal changes found such as increased or decreased bone density and diminution of foraminal detail or fluid density within the bulla tympanum. The other physical and neurological examinations were normal. The results of a complete blood count

¹Corresponding author.

E-mail : parkhee@konkuk.ac.kr

and serum biochemical profile were within the reference ranges.

To assess the apparent deafness, the BAER was recorded and analyzed. To validate the test, the BAER was also assessed on a normal littermate. Because the BAER test is

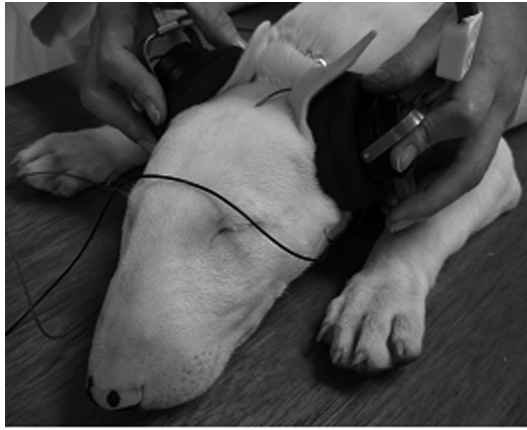

Fig 1. A white Bull Terrier puppy undergoing a BAER test; three electrodes are placed under the skin and the headphone was held against the pinna, so that the click sound would be directed down the external ear canal, the electrical response of the brain is then recorded.

not significantly affected by anesthesia, both dogs were sedated with medetomidine hydrochloride (Domitor[®], Pfizer Animal Health, USA) (30 $\mu\text{g}/\text{kg}$, IM). They were placed in sternal recumbency on a padded surface in a quiet but not sound treated room. Three 12-mm stainless steel subdermal needle electrodes (Neuroline Subdermal[®], Ambu, Malaysia) were inserted subdermally on the heads of the dogs with the reference electrode at the vertex and the ground electrode inserted over the occiput. The recording electrode was placed just rostral to the tragus of the ear being tested. This was then moved to the corresponding position on the contralateral side before testing the other ear. The right ear was tested first, followed by the left ear.

The BAER was recorded using a standard electrodiagnostic machine (Sierra II, Cadwell, USA). A headphone (TDH-39, Telex, USA) was held against the pinna, so that the click sound would be directed down the external ear canal (Fig 1). The test ear was stimulated with alternating acoustic clicks while the non-test ear was masked with white noise at an intensity 30 dB of the normal hearing level (nHL) less than the stimulus intensity. The clicks were presented at 0.1 ms duration, at a rate of 21.1 clicks/s. The stimulus intensities were set at 90, 70, 50, 30, and 10 dBnHL. The recordings were obtained at an amplifier sensitivity of 1 to 5 $\mu\text{V}/\text{division}$, sweep speed of 1 ms/division, analysis time of 10 ms, and

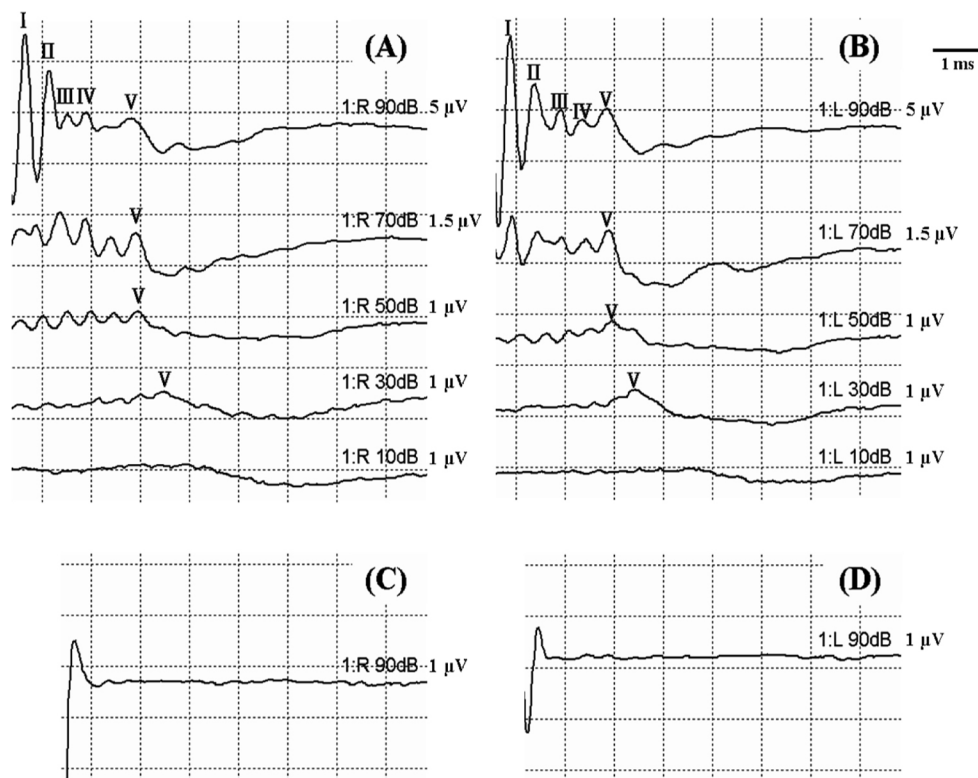


Fig 2. The BAER recordings from a normal littermate elicited by stimulating the right (A) and the left (B) ears with 90, 70, 50, 30, and 10 dBnHL. The waveforms consist of a series of five wave peaks (I-V) with decreased amplitude and prolonged latency as the stimulus intensity decreased. However, the BAER of the dog suspected of deafness, generated by 90 dBnHL stimuli, appeared as a flat line in the right (C) and the left (D) ears.

automatic artifact rejection. The filters were set with a low frequency cutoff setting of 100 Hz and a high frequency setting of 3 kHz. In each case, 1,000 repetitions were averaged and replicated.

The response of the normal littermate consisted of a series of five wave peaks (I-V) with decreased amplitude and prolonged latency as the stimulus intensity decreased (Fig 2A and B). This is consistent with normal auditory function to the level of the mid brainstem from both ears. The BAER from the dog suspected as deaf appeared as a flat line and did not reveal identifiable peaks that corresponded to those in the normal littermate (Fig 2C and D). These results confirmed sensorineural deafness, with the problem originating in the inner ear, rather than at some point further along the auditory pathway. Based on the history and clinical findings, the dog was confirmed to have bilateral congenital deafness.

Discussion

Hereditary, congenital or sensorineural deafness is usually linked to the genes for white coat such as piebald (s^j , s^p and s^w), merle (M) and white (W) genes (8). An association between pigmentation (white coat or blue eye color) and congenital deafness has been reported in dogs (4,8). The pigment-associated deafness results from the absence of melanocytes in the stria vascularis of the cochlea, which leads to early postnatal degeneration of the stria, and secondary degeneration of the cochlear hair cells and neurons (5,8). The prevalence of congenital deafness in the BT, Dalmatian, English Setter, Pointer, Borer Collie, Catahoula Leopard dog, Australian Cattle dog, Jack Russell Terrier, Dachshund, and English Cocker Spaniel has been evaluated previously (4,6,8,9,11).

In one prior study, color variations resulting from genes producing a white coat showed significant association with deafness (8). Especially the white BT was statistically more likely to be deaf than the colored BT. In this case, the deaf dog had a white coat. However, the dog did not have blue eyes; in a prior study the iris color of the BT did not exhibit a consistent significant association with the prevalence of deafness (8).

The BAER elicited by a broad spectrum of sound, such as a click, is a useful and objective assessment of auditory function and localization of brain stem lesions (10). The wave forms that are included in the BAER consist of five to seven peaks that occur within 10 ms of the stimulus; these peaks represent activity in the auditory nerve and sequential contributions from several nuclei of the brainstem auditory pathway (3). Interpretation of the BAER is based on the presence of the expected peaks as well as their latency and amplitude (1). An abnormal BAER is considered a highly reliable index of neural dysfunction if conductive dysfunction can be ruled out (5). The best age to test puppies is at six weeks, because the cochlear receptor-cell development is complete by this time (4). Dogs that are deaf by this age are considered to

have congenital sensorineural deafness (4). Dogs that are born with this condition can have bilateral or unilateral hearing loss (1). One prior study showed that 20 % of white BT were deaf; however, the prevalence of bilaterally affected dogs was only 2 % (8). In this case, the abnormal BAER of the dog suspected to be deaf was recorded bilaterally at eight weeks after birth, and other causes of conductive dysfunction were ruled out by otoscopic and radiographic examinations. Thus, congenital, sensorineural and bilateral deafness in this case was confirmed by the BAER, and a congenital etiology was suspected based on the owner's verbal history.

Effects of deafness on the development of a dog's ability to learn, communicate, and socialize may be profound (5). Thus, early detection can guide veterinarians and owners in decisions with regard to euthanasia or neutering purebred deaf pups. For dogs with unilateral deafness the behavior is normal; however, they are genetically similar to bilaterally deaf dogs. Thus, pure bred dogs with white coats or blue iris colors should be assessed for the presence of deafness. Because there is a reliable and relatively non-invasive technique available for the evaluation of hearing, the BAER can be used to diagnose unilateral or bilateral deafness and can provide important information for breeding.

Acknowledgements

This work was supported by the Korea Science and Engineering Foundation (KOSEF) grant funded by the Korea government (MEST) (R11-2002-103) and the Korea Research Foundation Grant funded by the Korean Government (MOEHRD, Basic Re-search Promotion Fund) (KRF-2008-314-E00246).

References

1. Ahlström LA, Wilson WJ, Mills PC. Unilateral deafness in a white Bull Terrier diagnosed by BAER assessment. *Aust Vet J* 2005; 83: 742-743.
2. Gonçalves R, Freeman J, Penderis J. The use of contralateral masking noise in the detection of unilateral deafness in Dalmatian puppies. *J Vet Intern Med* 2008; 22: 234-237.
3. Harland MM, Stewart AJ, Marshall AE, Belknap EB. Diagnosis of deafness in a horse by brainstem auditory evoked potential. *Can Vet J* 2006; 47: 151-154.
4. Platt S, Freeman J, di Stefani A, Wieczorek L, Henley W. Prevalence of unilateral and bilateral deafness in border collies and association with phenotype. *J Vet Intern Med* 2006; 20: 1355-1362.
5. Sims MH, Shull-Selcer E. Electrodiagnostic evaluation of deafness in two English setter littermates. *J Am Vet Med Assoc* 1985; 187: 398-404.
6. Steinberg SA, Klein E, Killens RL, Uhde TW. Inherited deafness among nervous pointer dogs. *J Hered* 1994; 85: 56-59.
7. Strain GM. Congenital deafness and its recognition. *Vet Clin N Am Small Anim Pract* 1999; 29: 895-907.
8. Strain GM. Deafness prevalence and pigmentation and

- gender associations in dog breeds at risk. *Vet J* 2004; 167: 23-32.
9. Strain GM, Kearney MT, Gignac IJ, Levesque DC, Nelson HJ, Tedford BL, Remsen LG. Brainstem auditory-evoked potential assessment of congenital deafness in Dalmatians: associations with phenotypic markers. *J Vet Intern Med* 1992; 6: 175-182.
 10. Strain GM, Tedford BL, Jackson RM. Postnatal development of the brain stem auditory-evoked potential in dogs. *Am J Vet Res* 1991; 52: 410-415.
 11. Wood JL, Lakhani KH, Henley WE. An epidemiological approach to prevention and control of three common heritable diseases in canine pedigree breeds in the United Kingdom. *Vet J* 2004; 168: 14-27.
 12. Yoon YS, Yeon SC, Kweon OK, Nam TC. Brain-stem auditory evoked responses as a diagnostic tool for deafness in dogs. *J Vet Clin* 1998; 15: 410-416.