

Ununited Anconeal Process in a Labrador Retriever Dog

Jae-Hoon Lee, Wo-Jong Yang, Eun-Hee Kang, Hwa-Seok Chang, Dai-Jung Chung,
Chi-Bong Choi, Jeong-Ik Lee* and Hwi-Yool Kim¹

College of Veterinary Medicine, Konkuk University, Seoul 143-701, Korea

*Surgical Science, Tokai University School of Medicine, Isehara, 259-1193, Japan

(Accepted: September 3, 2008)

Abstract : A 6 month-old male Labrador retriever was presented for intermittent lameness on the left forelimb after exercise. The dog was suffering progressive lameness that had started two months before. On mediolateral radiographic view of the left elbow, proximal margin of the anconeal process was irregular. A lucent, indistinct line separating the anconeal process from the ulna was observed, when the elbow joint was flexed. The lateral approach to the elbow joint was used and the ununited anconeal process was removed. The limb was bandaged after surgery for 7 days to support soft tissue and exercises were restricted. The dog showed normal limb function 3 weeks after surgery. On a telephone conversation with the owner 18 months after surgery, the dog was reported to maintain normal function of the limb.

Key words : Ununited anconeal process, elbow dysplasia, lameness, dog.

Introduction

Ununited anconeal process (UAP) is a disease in which the anconeal process does not fuse to the proximal ulnar metaphysis (14). The primary clinical sign of UAP is a gradual and progressive weight-bearing lameness. The lameness worsens after exercise (14). Secondary sign include joint effusion, joint thickening and crepitus (1,3). The German shepherd dog is notable for the high occurrence of UAP (8,17), but UAP is also found in other large-breed dogs (9,13,14) and some smaller breeds such as, basset. Males are reported to be predisposed (1), and bilateral disease has been reported in 11%~47% of cases. Either side is equally affected in dogs with unilateral UAP (1,6).

There have been various theories described about pathophysiological mechanism of UAP. One is that UAP is a form of osteochondrosis which result from a disturbance in the endochondral ossification and the failure of timely endochondral ossification of the attachment of the anconeal process to the ulna leads to fissures (1). Some authors implicated dietary influences such as excess calcium, in the etiology (10,14).

A diagnosis of ununited anconeal process is made by detection of a radiolucent line between the anconeal process and the remainder of the ulna in dogs older than 20 weeks (14). Additional radiographic finding with UAP may include muscle atrophy, joint swelling, periarticular osteophytosis and bone remodeling around the joint. The flexed mediolateral view is usually of the most value for diagnosis of UAP

because it avoids superimposition of the epicondyles with the physis of the medial humeral epicondyle (6).

To the authors' knowledge, this is the first case report on UAP in South Korea. The purpose of this paper is to describe the finding in a dog with UAP, with the emphasis on diagnosis, surgical treatment and prognosis.

Case report

A 6 month-old male Labrador retriever was presented to Konkuk University Veterinary Teaching Hospital (KUVTH) for intermittent lameness on left forelimb after exercise. The dog had been suffering progressive lameness of its left hind-limb for two months. There was no history of trauma or other problems. During physical examination of the elbow, it was found that motion range was decreased and soft tissue was swelled. A complete blood count showed mild lymphocytosis. Serum-chemistry profiles showed mild hyperphosphatemia (8.8 mg/dl, reference range 1.9~5.0), hypercalcemia (12.2 mg/dl, reference range 9.3~12.1), elevation of CPK (204 U/L, reference range 49~166) and ALP (371 U/L, reference range 69~333).

There were no remarkable findings in thoracic radiography, abdominal ultrasonography and neurological examination. On the mediolateral view of the radiography of the left elbow, proximal margin of the anconeal process was irregular. A lucent, indistinct line separating the anconeal process from the ulna was observed, when the elbow joint was flexed (Fig 1). On mediolateral radiographic view of the right elbow, the anconeal process had normal anatomy that united to ulna.

¹Corresponding author.
E-mail : hykim@konkuk.ac.kr

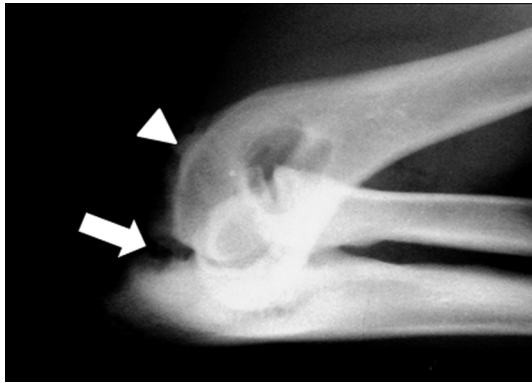


Fig 1. A lateral radiography of the flexed left elbow. A lucent, irregular line between and anconeal process and the olecranon (arrow) is revealed. The periarticular osteophyte (arrow head) along the humerus condyle is showed.

The dog was premedicated with acepromazine (Sedaject[®], Sam-Woo Median Co., Ltd., Korea, 0.1 mg/kg, IM) and medetomidine (Domitor[®], Orion PharmaCo., Finland, 0.02 mg/kg, IM), and was injected with intravenous propofol (Anepol[®], Hana Pharam Co., Ltd., Korea, 6 mg/kg, IV). Ane-sthesia was maintained using 1.5 % isoflurane (Forane[®], Rhodia Orgranique Fine Ltd., Korea) and oxygen added to room air using an endotracheal tube.

After general anesthesia, the dog was positioned in right lateral recumbency. Preoperatively, brachial plexus nerve was blocked with 2 % lidocaine (Lidocain[®], Huons Co., Ltd., Korea, 1 mg/kg). The lateral approach to the elbow joint was used. A skin incision was made from the border of epicondyle to the proximal portion of the radius. The cranial border of the triceps muscle was retracted caudally to expose the anconeus muscle. The anconeus muscle and joint capsule were incised along the epicondylar crest to expose the anconeal process. UAP was identified and removed using Allis tissue forceps (Fig 2). The joint capsule and the subcutaneous tissue were sutured using 3-0 poliglecaprone 25 (Monosyn[®], Ethicon, USA). The skin closure was routinely performed. Postoperatively, pain was controlled with buprenorphine (Renolpan[®], Hanlim, Korea, 10 ug/kg, IM). Cephal-

exin (Cephalexin[®], Dong Koo, Korea, 30 mg/kg, PO, tid) was given for prophylactic antibiotics and carprofen (Rimadyl[®], Pfizer, USA, 2.2 mg/kg PO, bid) was administered for 2 weeks. The limb was bandaged after surgery for 7 days to support soft tissue and the dog was restricted within the cage. The dog recovered normal limb function 3 weeks after surgery. On a telephone conversation with the owner 18 months after surgery, the dog was reported to maintain normal function of the left forelimb.

Discussion

Differential diagnoses for UAP include fragmented coronoid process (FCP), osteochondrosis dessicans (OCD), panostitis and combined UAP and FCP (1,14). However, physical examination findings did not differ significantly in dogs with FCP, UAP, and OCD. Recently, some reports suggested that radiographic evaluation alone should not be used to diagnose elbow incongruity because of the superimposition of anatomical structures in standard views and positional influences on the interpretation (12). Definitive diagnosis is made at the time of surgery after careful inspection of all articular structures is completed (1,14).

Medical treatment for UAP includes body weight restriction, exercise control, and analgesic therapy. Dogs less than 5 or 6 months old with UAP may be treated by cage rest and limiting exercise. Medical therapy generally is used to treat older dogs with established osteoarthritis (OA). However, medical therapy alone has been less successful than surgery, usually resulting in rapid progression of OA (1,6,16).

Surgical techniques for UAP include surgical reattachment using lag screw fixation, removal of the UAP and ostectomy of the ulna with or without surgical fixation of the anconeal process (3,5,16). Surgical reattachment using a lag screw is usually attempted for patients younger than 24 weeks. For those older than 24 weeks, surgical removal of the UAP is recommended (2). Reattachment is indicated only when the anconeal process appears normal in size, shape and density on both the radiographs and surgical evaluation (1,5). Removal of the UAP is indicated when the UAP is osteoly-

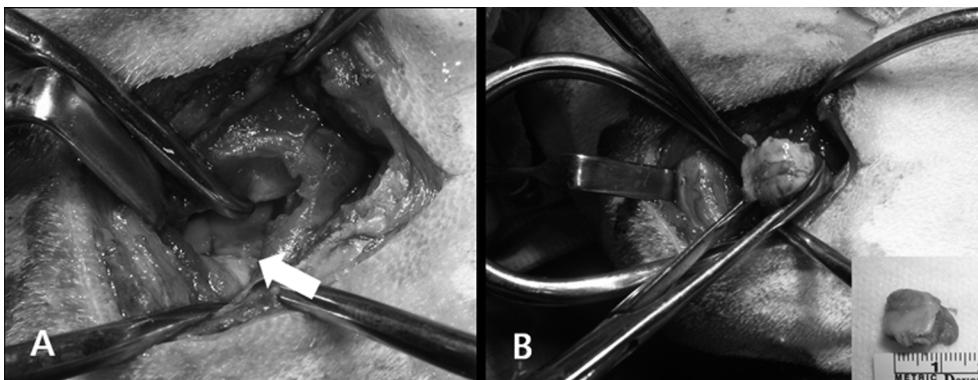


Fig 2. Appearances of elbow joint during surgery. (A) Ununited anconeal process was identified as not fused to the ulna and (B) removed using Allis tissue forceps.

tic, malformed, sclerotic or difficult to return to its normal anatomic position. Removal of the UAP may also be indicated after osteotomy of the ulna if fusion does not occur within 12~18 weeks after surgery (1,8,16). In the present case, because the dog showed some degree of osteoarthritis, malformation and osteolytic changes on radiographic examination, and the age of the dog was over 20 weeks. Considering these factors, we recommended the surgical removal of the anconeal processes.

Surgical removal of the anconeal process after extensive development of osteoarthritis does not stop the progression of osteoarthritis (14). A study of 16 dogs in which the UAP were surgically removed reported that 15 of the 19 elbows showed no signs of pain on palpation but variable amounts of bony and soft tissue crepitus. All dogs in the study had some degree of osteoarthritis before surgery. The arthritis in four elbows progressed radiographically (15).

The lag screw functions to maintain alignment and to provide compression of the ununited anconeal process to the proximal ulna during healing. Keeping the anconeal process in an anatomical position maintains elbow joint congruency, thereby decreasing the potential for future development of osteoarthritis (4,14).

A study of eight dogs in which the UAP was surgically reattached found encouraging results, though long-term studies are still needed (4). Another report described the results of proximal ulnar osteotomy in 22 elbows in 20 dogs (16). Twelve of 20 limbs exhibited no lameness, five had intermittent lameness after heavy exercise, two were intermittently lame, and one was lame persistently. Radiographically, osteophytes were nonexistent or mild in 16 joints, moderate in three joints, and severe in one (16). Osteotomy of the ulna with or without lag screw fixation has produced good clinical outcomes in the long term studies, but 30 % of the dogs developed signs of progressive osteoarthritis (11).

The prognosis for limb function was good when treated surgically by removal of the anconeal process. Long term evaluation found that the dogs with excision of the UAP had a favorable prognosis. However, despite surgical removal, reduced range of motion, crepitation, and progressive osteoarthritis occurs. No treatment option can ensure a functionally normal joint, and secondary osteoarthritis will occur and probably progress throughout the life. Repeated radiographs are recommended 6 weeks after osteotomy or lag screw fixation (1,6,15).

Reference

1. Cross AR, Chambers JN. Ununited anconeal process of the canine elbow. *Compend Contin Educ Pract Vet* 1997; 19: 349-361.
2. Demko J, McLaughlin R. Developmental orthopedic disease. *Vet Clin Small Anim* 2005; 35: 1111-1135.
3. Fox SM, Bloomberg MS, Bright RM. Development anomalies of the canine elbow. *J Am Anim Hosp Assoc* 1983; 19: 605-615.
4. Fox SM, Burbidge HM, Bray JC, Guerin SR. Ununited anconeal process: lag-screw fixation. *J Am Anim Hosp Assoc* 1996; 32: 52-56.
5. Goring RL, Bloomberg MS. Selected developmental abnormalities of the canine elbow: radiographic evaluation and surgical management. *Compend Contin Educ Pract Vet* 1983; 5: 178-188.
6. Guthrie S. Some radiographic and clinical aspects of ununited anconeal process. *Vet Rec* 1989; 124: 661-662.
7. Hazewinkel HAW. Nutrition in relation to skeletal growth deformities. *J Small Anim Pract* 1989; 30: 625-630.
8. Hornof WJ, Wind AP, Wallack ST, Schulz KS. Canine elbow dysplasia. The early radiographic detection of fragmentation of the coronoid process. *Vet Clin North Am Small Anim Pract* 2000; 30: 257-266.
9. LaFond E, Breur GJ, Austin CC. Breed susceptibility for developmental orthopedic disease in dogs. *J Am Vet Med Assoc* 2002; 38: 467-477.
10. LinksNap RC, Hazewinkel HA. Growth and skeletal development in the dog in relation to nutrition; a review. *Vet Q* 1994; 16: 50-69.
11. Meyer-Lindenberg A, Fehr M, Nolte I. Short- and long-term results after surgical treatment of an ununited anconeal process in the dog. *Vet Comp Orthop Traumatol* 2001; 14: 101-110.
12. Mason DR, Schulz KS, Samii VF, Fujita Y, Hornof WJ, Herrgesell EJ, Long CD, Morgan JP, Kass PH. Sensitivity of radiographic evaluation of radio-ulnar incongruence in the dog in vitro. *Vet Surg* 2002; 31: 125-132.
13. Morgan JP, Wind A, Davidson AP. Bone dysplasias in the Labrador retriever: A Radiographic study. *J Am Anim Hosp Assoc* 1999; 35: 332-340.
14. Schulz KS, Krotscheck U. Elbow dysplasia. In: Slatter D. *Textbook of small animal surgery*, 3rd ed. Philadelphia. 2003: 1927-1952.
15. Sinibaldi KR, Amoczky SP. Surgical removal of the ununited anconeal process in the dog. *J Am Anim Hosp Assoc* 1975; 11: 192-198.
16. Sjoström L, Kasstrom H, Kallberg M. Ununited anconeal process in the dog. Pathogenesis and treatment by osteotomy of the ulna. *Vet Comp Orthop Traumatol* 1995; 8: 170-176.
17. Wind AP, Packard ME/ Elbow incongruity and developmental elbow disease in the dog: Part II. *J Am Anim Hosp Assoc* 1986; 22: 726-730.