

Assessment of Ovarian Volume and Hormonal Changes after Ovarian Cystectomy in the Different Ovarian Tumor

Joon-Cheol Park*, Jin-Gon Bae, Jong-In Kim, Jeong-Ho Rhee

Department of Obstetrics and Gynecology, School of Medicine, Keimyung University, Daegu, Korea

난소 낭종 제거술후 난소 용적 및 호르몬의 변화

박준철* · 배진곤 · 김종인 · 이정호

계명대학교 의과대학 산부인과교실

목적: 난소 용적 측정 및 기저 FSH, E₂, CCCT 검사를 통하여 가임기 여성에서 난소 낭종 제거술후 난소 배란능의 변화를 평가하고자 하였다.

연구방법: 난소 낭종으로 내원한 환자 중 35세 이하의 여성으로서 비교적 규칙적인 생리주기를 가지며 한쪽 난소에만 낭종을 가진 22명을 대상으로 자궁내막종균과 비자궁내막종균으로 구분하여 전향적 비교 분석을 시행하였다. 질 초음파를 이용하여 수술 1개월 전과 수술 3개월 후 생리주기 3일에 난소의 용적을 측정하였다. 또한 수술 전과, 수술 후 두 번의 정상 생리가 있는 뒤 기저 FSH, E₂, CCCT를 시행하였다. 대상 환자 22명 중 3명은 술후 검사를 계획한 3개월 전에 임신이 됨으로써 연구대상에서 제외하였다.

결과: 수술 후 난소 용적은 자궁내막종균에서 $4.79 \pm 2.57 \text{ cm}^3$, 비자궁내막종균 중 직경 $\geq 10 \text{ cm}$ 인 경우에서 $5.21 \pm 1.33 \text{ cm}^3$ 로서 견측과 비교하여 유의한 감소가 있었으나, 비자궁내막종균 중 직경 $< 10 \text{ cm}$ 인 경우는 $6.18 \pm 2.85 \text{ cm}^3$ 로서 유의한 용적 감소가 없었다. 수술후 자궁내막종균의 기저 FSH는 $4.25 \pm 0.20 \text{ mIU/ml}$, CCCT 10일째 FSH는 $3.79 \pm 0.80 \text{ mIU/ml}$ 였고, 비자궁내막종균은 각각 $4.24 \pm 0.85 \text{ mIU/ml}$, $4.28 \pm 0.92 \text{ mIU/ml}$ 로서 수술 전후의 기저 FSH, CCCT 결과 비교에서 각 군 모두 유의한 차이가 없었으며, 두 군간의 비교에서도 유의한 차이가 없었다.

결론: 자궁내막종 절제술 및 10 cm 이상의 난소 낭종 절제술 후 난소 용적은 유의한 감소를 보였으나 10 cm 미만의 난소 낭종 제거술에서는 난소 용적의 유의한 감소가 없었다. 난소 배란능을 평가하기 위하여 측정된 기저 FSH, CCCT 검사 결과는 낭종 제거술 후에도 각 군 모두 유의한 차이를 보이지 않았다. 따라서 가임기 여성에서는 난소절제술 보다는 낭종 제거술이 우선 고려되어야 하며, 세심한 주의를 기울인다면 난소 배란능의 손상을 최소화할 수 있을 것으로 사료된다.

[Korean. J. Reprod. Med. 2008; 35(2): 155-162.]

중심단어: 자궁내막종, 난소 낭종, 낭종 제거술, 난소배란능

Endometrioma is a common gynecological disorder which affects 20~40% of women who complain of subfertility although it can be found also in 5~10% of fertile women.¹ There is a general consensus that operative laparoscopy should be considered as the first line

treatment in symptomatic women especially related with the infertility.² Excision rather than ablation of the cyst is recommended because the former has been associated with a higher pregnancy rate and a lower recurrence rate.^{3,4} But excision of endometrioma is associated with a significant reduction of ovarian reserve because the excision of the so-called cyst wall implies the removal of ovarian tissues having primordial follicles and possibly

주관책임자: 박준철, 우) 700-712 대구광역시 중구 동산동 194번지, 계명대학교 동산의료원 산부인과학교실
Tel: (053) 250-7357, Fax: (053) 250-7599
e-mail: jepark@dsmc.or.kr

insult on ovarian stroma and vascularization. The other ovarian tumors such as dermoid, serous cystadenoma, mucinous cystadenoma are different from endometrioma because those have well defined capsule, so ovarian tissue would be less traumatized on surgical procedure.

To our knowledge, however, there was no study about the actual change of ovarian reserve after surgery. We evaluated the postoperative ovarian volume and hormonal change after ovarian cystectomy in patients with unilateral endometrioma or other ovarian tumor.

MATERIALS AND METHOD

This study was conducted in patients with unilateral ovarian cysts that required surgical removal. Inclusion criteria were as follows 1) age less than 35 years, 2) regular menstrual cycles with cycle length of 25~35 days with ≤ 4 days difference between cycles, 3) presence of both ovaries, 4) no hormonal medication within 3 months, 5) absence of any other endocrine disorders, 6) absence of previous surgery on ovary. The patients were collected prospectively and divided into two groups by tumor type such as endometrioma and non-endometrioma (i.e well-defined tumor) group. Nine of them had endometrioma and the other patients had well defined wall tumor (eg. Dermoid). We evaluated the postoperative ovarian volume and hormonal change, and compared them between two groups. Twenty two women were included, but 3 patients that had been pregnant within 3 months after surgery were excluded in analysis.

1. Ovarian volume measurement

All patients underwent transvaginal ultrasound examination within 1 month before surgery and 3 months after surgery to assess the tumor and ovarian volume, measured three diameters and calculated by $4/3\pi$ (mean diameter/2).³ To exclude the presence of ovarian follicular

cyst, it was performed within day 3 of the menstrual cycle. We compared the ovarian volume after surgery with contralateral normal ovarian volume.

2. Hormonal measurement

All patients were taken blood sampling on day 3 of menstrual cycle for basal FSH and E₂, and took clomiphene citrate 100 mg per day on day 5 to 9, then taken blood sampling on day 10 of menstrual cycle for FSH. At least 2 spontaneous menstrual cycles after surgery, we checked basal FSH, and CCCT as same way. On day 10, we performed the ultrasound examination to confirm the dominant follicular growth on the operated ovary. If the dominant follicle was not growing on the operated ovary, then we rechecked the CCCT on next cycle. FSH and E₂ were measured by radioimmunoassay with FSH-IRMA kit and E₂-RIA-CT kit (BioSource Europe S.A. Belgium).

3. Operation

All patients were taken the ovarian cystectomy under general anesthesia. Most of the patients were operated by laparoscopy but 4 of patients were operated by laparotomy. The way of operation was decided by tumor size, tumor type, and patients' operative history. All patients with endometrioma were operated by laparoscopic cystectomy using a stripping technique. Well capsulized tumor was enucleated by sharp dissection to spare the normal ovarian tissue. Hemostasis was achieved meticulously with bipolar electrocauterization, avoiding contact with the external surface of ovary to prevent adhesion and cortical damage.

4. Statistical analysis

Statistical analysis was performed with paired student t-test, nonparametric Wilcoxon rank test and Mann-Whitney test by window SPSS-12.0.

RESULTS

1. Patients demographic data

We evaluated 22 women and their mean age was 26.6 ± 4.59 (17~33) years old. 10 women of them were married. As mentioned above, we evaluated the post-operative ovarian volume and hormonal change on 2 menstrual cycle later after surgery. But three women (2 of endometrioma group, 1 of non-endometrioma group) were pregnant within 3 months. That means 30% of married women were pregnant within 3 months after surgery. So they were excluded from the result analysis.

The mean tumor size was 9.1 ± 5.7 cm in diameter (4.3~25.5 cm), and the tumor types were 7 endometrioma, 8 dermoid, 2 serous cystadenoma, 2 mucinous cystadenoma. The diameter of tumor in the endometrioma group was significantly smaller than non-endometrioma group (5.47 ± 1.44 cm in endometrioma group, 11.78 ± 6.23 cm in non-endometrioma group, p -value=0.01) (Table 1). By the tumor size, non-endometrioma group was divided into two subgroups (≥ 10 cm or < 10 cm in mean diameter) and compared the results between each group.

2. Ovarian volume change after surgery

The volume of the operated ovaries was significantly smaller compared with the contralateral ovary. After stripping of endometrioma, the ovarian volume was reduced to 4.79 ± 2.57 cm³ compared opposite normal ovarian volume (8.11 ± 2.09 cm³) (p -value=0.03). It was also reduced to 5.75 ± 2.23 cm³ after cystectomy of the other well-defined ovarian tumor compared opposite ovary (7.40 ± 2.30 cm³) (p -value=0.01). The residual ovarian volume after surgery was smaller in endometrioma group (59.1%) than in the other well-defined ovarian tumor group (77.7%), but there was no statistically significant difference between two groups (p -value

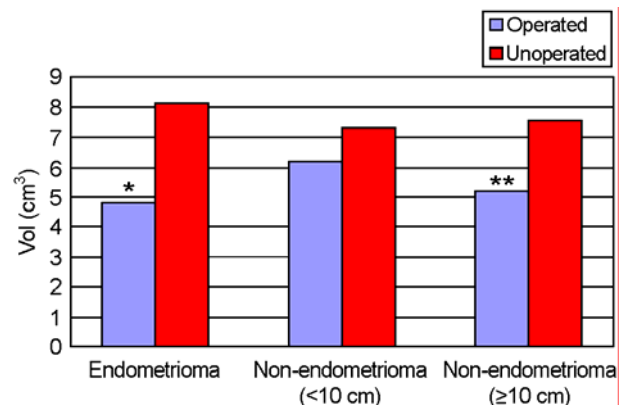


Figure 1. Ovarian volume of the operated and the contralateral intact ovaries in endometrioma and non-endometrioma group.

The residual volume of operated ovary was significantly reduced in endometrioma compared with that of unoperated ovary (p -value < 0.05), but was not in non-endometrioma group.

** Only larger than 10 cm of non-endometrioma was significantly reduced compared with unoperated ovary (** p -value < 0.05)

=0.45). In endometrioma, it did not seem to be related to the dimension of the excised ovarian cysts. But in non-endometrioma group, the operated ovarian volume was reduced significantly in tumor larger than 10 cm diameter (5.21 ± 1.33 cm³), but not in smaller tumor (6.18 ± 2.85 cm³) (Figure 1).

3. Hormonal measurement before/after surgery

1) preoperative hormonal measurements

In endometrioma, the preoperative basal FSH, basal E₂, and day10 FSH on CCCT were 4.46 ± 0.52 mIU/ml, 68.86 ± 26.48 pg/ml, and 4.03 ± 0.34 mIU/ml. In non-endometrioma group, the preoperative basal FSH, basal E₂, and day 10 FSH on CCCT were 4.21 ± 0.60 mIU/ml, 68.9 ± 23.99 pg/ml, and 4.42 ± 0.87 mIU/ml. there was no significant difference in both groups (p -value > 0.05), even though the tumor size of non-endometrioma group was significantly larger than the endometrioma group (Table 1). Considering the tumor size, we also compared with the subgroups of non-endometrioma group but there was no significant difference either.

Table 1. Demographic data of the endometrioma and non-endometrioma group

	Endometrioma	Non-endometrioma	<i>P</i> -value
Age	27.5	26.0	0.69
Max diameter (Cm)	5.47±1.44	11.78±6.23	0.01
Tumor vol. (Cm ³)	78.99±101.60	131.80±1556.90	0.05
Basal FSH (mIU/ml)	4.46±0.52	4.21±0.60	0.10
10 th day FSH	4.03±0.34	4.42±0.87	0.44
Basal E ₂ (pg/ml)	68.86±26.48	68.9±23.99	1.00

Values are mean ± SD.

Table 2. Hormonal measurement before/after surgery and compared with two groups

	Endometrioma		Non-endometrioma	
	Preop	Postop	Preop	Postop
Basal FSH	4.46±0.52	4.25±0.20	4.21±0.60	4.24±0.85
10 th FSH	4.03±0.34	3.79±0.80	4.42±0.87	4.28±0.92

* There was no significant change on basal FSH or CCCT after cystectomy regardless of ovarian tumor type

Table 3. Hormonal measurement before/after surgery in the subgroups of non-endometrioma by tumor size

	Smaller than 10 cm		Larger than 10 cm	
	Preop	Postop	Preop	Postop
Basal FSH	4.30±0.31	4.05±0.90	4.09±0.87	4.46±0.81
10 th FSH	4.35±0.79	3.91±0.41	4.51±1.03	4.74±1.20

* There was no significant change on basal FSH or CCCT after cystectomy regardless of tumor size in non-endometrioma group

2) postoperative hormonal measurements

The postoperative basal FSH and day 10 FSH on CCCT of endometrioma were 4.25±0.20 mIU/ml and 3.79±0.80 mIU/ml, so the CCCT was normal meaning that the ovarian reserve was not so much damaged after surgery. The postoperative basal FSH and day 10 FSH on CCCT were not significantly changed compared with preoperative basal FSH and day 10 FSH on CCCT either (*p*-value=0.34, *p*-value=0.89).

The postoperative basal FSH and day 10 FSH on CCCT of non-endometrioma group were 4.24±0.85 mIU/ml and 4.28±0.92 mIU/ml. The postoperative

CCCT of non-endometrioma group was also normal, and there was no significant difference compared with the preoperative result (*p*-value=0.79, *p*-value=0.56).

Compared both groups, there was no significant difference in the postoperative values of CCCT (*p*-value=0.32) (Table 2).

Because the mean diameter of non-endometrioma group was larger than endometrioma group, non-endometrioma group was divided into two subgroup by tumor size. there was no significant difference in subgroup analysis (Table 3).

DISCUSSION

When the ovarian tumor is diagnosed in reproductive age group, the ovarian reserve after surgery is concerned as well as tumor recurrence. The laparoscopic cystectomy by stripping technique, in particular endometriomas, is considered as the first line treatment.^{2,5} Even though meticulous cystectomy was applied, questions about a decrease of ovarian reserve, reduced responsiveness to ovarian hyperstimulation, decreased number of oocytes retrieved during IVF cycles has been still in the debate.⁶⁻¹¹ Some studies⁶⁻⁸ did but some studies⁹⁻¹¹ did not observe the negative effect of cystectomy on the ovarian reserve. And there are just a few reports for residual ovarian volume after surgery comparing the endometrioma with well-capsulized tumor.^{12,13} A potential deleterious mechanisms of cystectomy are the accidental removal of some normal ovarian tissue during cystectomy, damage on ovarian stroma and vascularization by both surgery-related local inflammation and electrosurgical coagulation during hemostasis.¹ The laparoscopic stripping technique for ovarian tumor is performed by pulling the cyst wall and the normal ovarian parenchyma in opposite directions. So the loss of ovarian tissue could be much more in endometrioma than other ovarian tumor with a real anatomic capsule. Exacoustos et al.¹² reported laparoscopic ovarian stripping of endometriomas was associated with a significant decrease in residual ovarian volume but that of dermoids was not. And actually in pathologic review of biopsy specimens, Muzii et al.¹³ reported that some ovarian tissue was present in only 6% of ovarian cysts (eg. dermoid, serous and mucinous) with a real anatomic capsule, whereas it was present in 54% of enucleated endometriomas. In our study, the residual ovarian volume was decreased significantly after surgery in both groups and there was no significant difference between endometrioma and well capsulized

tumor. It could be explained by the fact that size of ovarian tumor was larger than other study. Especially in the well capsulized tumor group, the mean diameter was 11.78 ± 6.23 cm in diameter. In the subgroups of well-capsulized ovarian tumor, the residual ovarian volume after cystectomy of larger than 10 cm diameter was significant reduced (5.21 ± 1.33 cm³), but it was not reduced in the smaller tumor (6.18 ± 2.85 cm³). As we expected, the loss of ovarian volume in well defined tumor is much less than in endometrioma. But the large (≥ 10 cm) ovarian tumor, even though that is well capsulized, showed a greater loss of ovarian tissue. This is consistent with Exacoustos' study that the removal of dermoid larger than 8 cm was related significantly with decreased residual ovarian volume.¹² After surgery, we could save the 59.1% of ovarian volume in endometrioma, 85.1% of well capsulized tumor (<10 cm), and 68.9% of well capsulized tumor (≥ 10 cm). It means that we have to consider the cystectomy rather than oophorectomy even in the large tumor. 4 cases was operated by laparotomy due to the tumor size or multiple chamber. These cases (2 mucinous cystadenoma, 1 serous cystadenoma, 1 dermoid) are larger than 10 cm in diameter. To our knowledge, there were many studies compared laparoscopy with laparotomy about the complication, hospital stay, pain, and so on,^{14,15} however, there was no study about the residual volume after surgery. Further studies are required to clarify the relation between residual volume and operative method.

Even though there is a significant loss of ovarian volume after surgery, especially in endometrioma, it might not seriously affect to ovarian reserve compared preoperative condition in which tumor exist. It cannot be excluded that the cyst itself may damage the surrounding ovarian tissue. Indeed, Maneschi et al.¹⁶ reported that the ovarian cortex surrounding endometriomas showed morphologic patterns similar to those of the normal ovarian cortex in only 19% of cases, whereas the ovarian

cortex surrounding mature teratomas and benign cystadenomas appears morphologically normal in 92% and 77% of cases. So we planned to perform the hormonal test for ovarian reserve before and after cystectomy in both groups. A number of parameters known as ovarian reserve markers have been examined in many assisted reproductive technology programmes to predict ovarian responses prior to ovarian stimulation with gonadotropin. Static hormonal markers are basal FSH,¹⁷ basal estradiol,¹⁸ inhibin B,¹⁸ and anti-Müllerian hormone.²⁰ Dynamic hormonal tests include clomiphene citrate challenge test (CCCT),²¹ GnRH agonist stimulation test,²² and exogenous FSH ovarian reserve test.²³ And ultrasound assessment of the ovarian volume,²⁴ total antral follicle count,^{25,26} and ovarian stromal blood flow are studied.²⁷ There's no method for the accurate assessment of ovarian reserve, but age and basal FSH were widely used and convinced. We evaluated the basal FSH, basal E₂ and CCCT to assess the ovarian reserve before/after cystectomy comparing endometrioma with well-capsulized tumor. As followed inclusion criteria, the age of both groups were not different significantly. In preoperative hormonal study, basal FSH level and CCCT were in normal range (<10 IU/L) regardless of tumor types. And basal E₂ level was also in normal range (<80 pg/ml) in both groups. Because the invagination of endometrial tissue into the ovarian stroma from cortex is thought as one of the mechanisms in the development of endometrioma, we expected the basal hormonal profile in the endometrioma group would be worse than in the other group. But there was no significant difference in the preoperative hormonal profile between two groups, or in the subgroup analysis. there was no definitive data to clarify whether the influence of the other healthy ovary made compensation, or the damage of ovary was not so serious to affect the hormonal test. In postoperative hormonal study, basal FSH and the result of CCCT were in normal range regardless of tumor type. There

was no significant change in postoperative hormonal tests compared with preoperative result in each tumor group, or compared with the two groups. It could be a consequence of that the remained ovarian volume was not so different. This means, at least, the endocrine function of ovary could be reserved after surgery. However, we could not compare our results with other study because there was no study about the actual change of ovarian hormonal reserve test after surgery.

In some studies comparing the number of follicles in operated and contralateral non-operated ovary during ovarian stimulation for in vitro fertilization-embryo transfer (IVF-ET), decrease in ovarian response and decreased number of oocytes retrieved were observed in the operated ovary,⁶⁻⁸ but some studies didn't observe a negative effect of cystectomy on ovarian response for IVF-ET.^{9-11,28} As a limitation of this study, the patients did not visit the hospital for infertility treatments, so we could not study the relation between postoperative hormonal tests and the number of oocytes retrieved. And another limitation of this study is that we calculated the ovarian volume by measuring three perpendicular diameters with 2-dimensional ultrasound. Because the ovary is not spherical, the volume measurement with three dimensional ultrasound could be more accurate.^{29,30}

In conclusion, ovarian stripping of endometrioma or cystectomy of ovarian tumor with well defined capsule larger than 10 cm in diameter was associated with a significant reduction in ovarian volume, but not in well defined tumor smaller than 10 cm in diameter. Hormonal makers, such as basal FSH and CCCT believed as sensitive tests for ovarian reserve, were not significantly changed in each group. Cystectomy rather than oophorectomy should be considered even in a large (≥ 10 cm) benign tumor in reproductive age women. Even though further studies are required to clarify the relation between the actual number of oocytes retrieved and hormonal markers, we believe that ovarian function could be

reserved without a significant decrease in ovarian reserve if we applied the meticulous operative technique.

REFERENCES

- Somigliana E, Vercellini P, Viganó P, Ragni G, Crosignani PG. Should endometriomas be treated before IVF-ICSI cycles? *Hum Reprod Update* 2006; 12: 57-64.
- Chapron C, Vercellini P, Barakat H, Vieira M, Dubuisson JB. Management of ovarian endometriomas. *Hum Reprod Update* 2002; 8: 591-7.
- Beretta P, Franchi M, Ghezzi F, Busacca M, Zupi E, Bolis P. Randomized clinical trial of two laparoscopic treatments of endometriomas: cystectomy versus drainage and coagulation. *Fertil Steril* 1998; 70: 1176-80.
- Alborzi S, Momtahan M, Parsanezhad ME, Dehbashi S, Zolghadri J, Alborzi S. A prospective, randomized study comparing laparoscopic ovarian cystectomy versus fenestration and coagulation in patients with endometriomas. *Fertil Steril* 2004; 82: 1633-7.
- Ragni G, Somigliana E, Benedetti F, Paffoni A, Vegetti W, Restelli L, et al. Damage to ovarian reserve associated with laparoscopic excision of endometriomas: a quantitative rather than a qualitative injury. *Am J Obstet Gynecol* 2005; 193: 1908-14.
- Nargund G, Cheng WC, Parsons J. The impact of ovarian cystectomy on ovarian response to stimulation during in-vitro fertilization cycles. *Hum Reprod* 1996; 11: 81-3.
- Ho HY, Lee RK, Hwu YM, Lin MH, Su JT, Tsai YC. Poor response of ovaries with endometrioma previously treated with cystectomy to controlled ovarian hyperstimulation. *J Assist Reprod Genet* 2002; 19: 507-11.
- Somigliana E, Ragni G, Benedetti F, Borroni R, Vegetti W, Crosignani P. Does laparoscopic excision of endometriotic ovarian cysts significantly affect ovarian reserve? Insights from IVF cycles. *Hum Reprod* 2003; 18: 2450-3.
- Loh FH, Tan AT, Kumar J, Ng SC. Ovarian response after laparoscopic ovarian cystectomy for endometriotic cysts in 132 monitored cycles. *Fertil Steril* 1999; 72: 316-21.
- Donnez J, Wyns C, Nisolle M. Does ovarian surgery for endometriomas impair the ovarian response to gonadotropin? *Fertil Steril* 2001; 76: 662-5.
- Wong BC, Gillman NC, Oehninger S, Gibbons WE, Stadtmayer LA. Results of in vitro fertilization in patients with endometriomas: is surgical removal beneficial? *Am J Obstet Gynecol* 2004; 191: 597-606.
- Exacoutos C, Zupi E, Amadio A, Szabolcs B, De Vivo B, Marconi D, et al. Laparoscopic removal of endometriomas: sonographic evaluation of residual functioning ovarian tissue. *Am J Obstet Gynecol* 2004; 191: 68-72.
- Muzii L, Bianchi A, Croce C, Mancini N, Benedetti Panici P. Laparoscopic excision of ovarian cysts: is the stripping technique a tissue-sparing procedure? *Fertil Steril* 2002; 77: 609-14.
- Gilja OH, Hausken T, Berstad A, Odegaard S. Measurements of organ volume by ultrasonography. *Proc Inst Mech Eng* 1999; 213: 247-59.
- Amer A, Hammadeh ME, Kolkailah M, Ghandour AA. Three-dimensional versus two-dimensional ultrasound measurement of follicular volume: are they comparable? *Arch Gynecol Obstet* 2003; 268: 155-7.
- Maneschi F, Marasa L, Incandela S, Mazzaresse M, Zupi E. Ovarian cortex surrounding benign neoplasms; a histologic study. *Am J Obstet Gynecol* 1993; 169: 388-93.
- Scott RT, Jr., Hofmann GE. Prognostic assessment of ovarian reserve. *Fertil Steril* 1995; 63: 1-14.
- Smottrich DB, Widra EA, Gindoff PR, Levy MJ, Hall JL, Stillman RJ. Prognostic value of day 3 estradiol on in vitro fertilization outcome. *Fertil Steril* 1995; 64: 1136-40.
- Seifer DB, Lambert-Messerlian G, Hogan JW, Gardiner AC, Blazar AS, Berk CA. Day 3 serum inhibin-B is predictive of assisted reproductive technologies outcome. *Fertil Steril* 1997; 67: 110-4.
- von Rooij IA, Broekmans FJ, Scheffer GJ, Looman CW, Habbema JD, de Jong FH, et al. Serum antimüllerian hormone levels best reflect the reproductive decline with age in normal women with proven fertility: a longitudinal study. *Fertil Steril* 2005; 83: 979-87.
- Navot D, Rosenwaks Z, Margalioth EJ. Prognostic assessment of female fecundity. *Lancet* 1987; 2: 645-7.
- Padilla SL, Bayati J, Garcia JE. Prognostic value of the early serum estradiol response to leuprolide acetate in in vitro fertilization. *Fertil Steril* 1990; 53: 288-94.
- Fanchin R, de Ziegler D, Olivennes F, Taieb J, Dzik A, Frydman R. Exogenous follicle stimulating hormone ovarian

- reserve test (EFORT): a simple and reliable screening test for detecting poor responders in in-vitro fertilization. *Hum Reprod* 1994; 9: 1601-11.
24. Lass A, Skull J, McVeigh E, Margara R, Winston RM. Measurement of ovarian volume by transvaginal sonography before ovulation induction with human menopausal gonadotrophin for in-vitro fertilization can predict poor response. *Hum Reprod* 1997; 12: 294-7.
 25. Tomas C, Nuojuu-Huttunen S, Martikainen H. Pretreatment transvaginal ultrasound examination predicts ovarian responsiveness to gonadotrophins in in-vitro fertilization. *Hum Reprod* 1997; 12: 220-3.
 26. Ng EHY, Yeung WSB, Fong DYT, Ho PC. Effects of age on hormonal and ultrasound markers of ovarian reserve in Chinese women with proven fertility. *Hum Reprod* 2003; 18: 2169-74.
 27. Engmann L, Sladkevicius P, Agrawal R, Bekir JS, Campbell S, Tan SL. Value of ovarian stromal blood flow velocity measurement after pituitary suppression in the prediction of ovarian responsiveness and outcome of in vitro fertilization treatment. *Fertil Steril* 1999; 71: 22-9.
 28. Canis M, Pouly JL, Tamburro S, Mage G, Wattiez A, Bruhat MA. Ovarian response during IVF-embryo transfer cycles after laparoscopic ovarian cystectomy for endometriotic cysts of >3 cm in diameter. *Hum Reprod* 2001; 12: 2583-6.
 29. Panici PB, Muzii L, Palaia I, Manci N, Bellati F, Plotti F, et al. Minilaparotomy versus laparoscopy in the treatment of benign adnexal cysts: a randomized clinical study. *Eur J Obstet Gynecol Reprod Biol* 2007; 133: 218-22.
 30. Yuen PM, Yu KM, Yip SK, Lau WC, Rogers MS, Chang A. A randomized prospective study of laparoscopy and laparotomy in the management of benign ovarian masses. *Am J Obstet Gynecol* 1997; 177: 109-14.

= Abstract =

Objectives: The aim of this study was to assess the change of ovarian reserve after removal of ovarian tumor using basal FSH, E₂, clomiphene citrate challenge test and ovarian volume.

Methods: Twenty two patients with unilateral ovarian tumor, ≤35 years old, regular menstrual cycle were collected prospectively and divided into endometrioma or non-endometrioma group. We measured the ovarian volume with transvaginal ultrasonography on the day 3 of menstrual cycle within one month before and 3 months after surgery. Basal (cycle day 3) FSH, E₂ and CCCT were checked before surgery and repeated at least 2 spontaneous cycles later after surgery. Three patients that had been pregnant within 3 months after surgery were excluded in analysis.

Results: The ovarian volume was reduced significantly after surgery in endometrioma and non-endometrioma ≥10 cm group (4.79 ±2.57 cm³ and 5.21±1.33 cm³, respectively), but not in the non-endometrioma <10 cm group (6.18±2.85 cm³). After surgery, basal FSH and cycle day 10 FSH on CCCT in endometrioma and non-endometrioma were 4.25±0.20 mIU/ml and 3.79±0.80 mIU/ml, 4.24±0.85 mIU/ml and 4.28±0.92 mIU/ml, respectively. There were neither significant difference in comparison with the preoperative results nor between two groups.

Conclusions: Enucleation of ovarian mass was associated with a significant reduction in ovarian volume in endometrioma and non-endometrioma larger than 10cm in diameter. Hormonal markers for evaluation of ovarian reserve, such as basal and cycle day 10 FSH on CCCT, were not changed significantly in each group. In reproductive age women, conservative enucleation or cystectomy rather than oophorectomy should be considered even in a large benign tumor and ovarian function could be reserved by meticulous operative technique.

Key Words: Endometrioma, Ovarian tumor, Ovarian cystectomy, Ovarian reserve
