

Jee Ho Jeon, M.D.

Hyung Sik Hwang, M.D.

Je Hoon Jeong, M.D.

Se Hyuk Park, M.D.

Jae Gon Moon, M.D.

Chang Hyun Kim, M.D.

Department of Neurosurgery
College of Medicine, Hallym
University, Seoul, Korea

Spinal Schwannoma; Analysis of 40 Cases

Objective : This study is to report our experience of 40 cases of spinal schwannoma.

Methods : From 1995 to 2006, medical records were retrospectively reviewed in 40 cases of spinal schwannoma.

Results : We treated 40 spinal schwannomas in 38 (22 male and 16 female) patients. The mean age was 50.2. Four cases were sited in the cervical spine, 11 cases in the thoracic spine, and 25 cases in the lumbar spine. Two patients showed recurrences. Thirty-eight cases were intradural-extramedullary type and 2 cases were extradural. Two cases (5%) including 1 recurred case had no postoperative motor improvement. Ninety-five percents of patients improved on postoperative motor grade.

Conclusion : Spinal schwannoma is mostly benign and extramedullary tumor. There were 2 recurred cases (5%) that had history of previous subtotal removal at first operation and had shown worse prognosis compared with the cases without recurrence. To reduce the recurrence of spinal schwannoma, total excision of tumor mass should be done.

KEY WORDS : Spinal schwannoma · Recurrence · Laminoplasty.

INTRODUCTION

Spinal schwannomas account for about 25% of intradural spinal cord tumors in adults^{2,4,5,17,19}. Most are solitary schwannomas, which can occur throughout the spinal canal⁵. Most schwannomas are firm, encapsulated neoplasm that are composed principally of neoplastic Schwann cells. Microscopically, schwannomas are characterized by high cellularity, and relative lack of an Antoni B pattern. The "multiple" form of neurofibromas is known as von Recklinghausen's disease³. According to Western studies, the incidence of spinal schwannomas varies between 0.3-0.4 cases /100,000 persons per year¹⁷. The age of its first manifestation was usually, with exception to few cases and few sites, around the 4th and 5th decades and no difference of prevalence between male and female was found^{2,4,5,7,17,19}. The total excision of the lesion, which is the generally reachable goal of surgery, allows for good results in the cases in which the preoperative clinical findings are not particularly severe. We have evaluated cases of the recurrence and the proper surgical modality of our spinal 40 schwannomas.

MATERIALS AND METHODS

Between January 1995 and June 2006, 38 patients underwent surgery for spinal schwannoma at our institution. The information was collected retrospectively from medical records regarding clinical presentation, tumor location, operative findings and post-operative complications. All cases were surgically excised, and they were confirmed to be schwannomas by pathologists with histopathological sections in paraffin stained with hematoxylin-eosin. Functional outcome was assessed using the motor grade and sensory change. All patients were also examined as outpatients. Median follow-up time was 15.9 months (range 0-91 months).

RESULTS

Patient population

There were 40 spinal schwannomas in 38 patients with 22 (60%) males and 16 (40%) females. The mean age was 50.2 years (range 6-74 years). More precisely, the mean age in cervical lesions was 58.3 years, in the thoracic lesions 45.7 years, and in the lumbosacral lesions 49.9 years. Four cases were located in cervical area (10%), 11 thoracic (27.5%), and 25 lumbar

• Received : December 6, 2007
• Accepted : March 18, 2008
• Address for reprints :
Hyung Sik Hwang, M.D.
Department of Neurosurgery
College of Medicine,
Hallym University, 94-200
Yeongdeungpo-dong,
Yeongdeungpo-gu,
Seoul 150-030, Korea
Tel : +82-2-2639-5450
Fax : +82-2-2676-0980
E-mail : hyungsik99@yahoo.co.kr

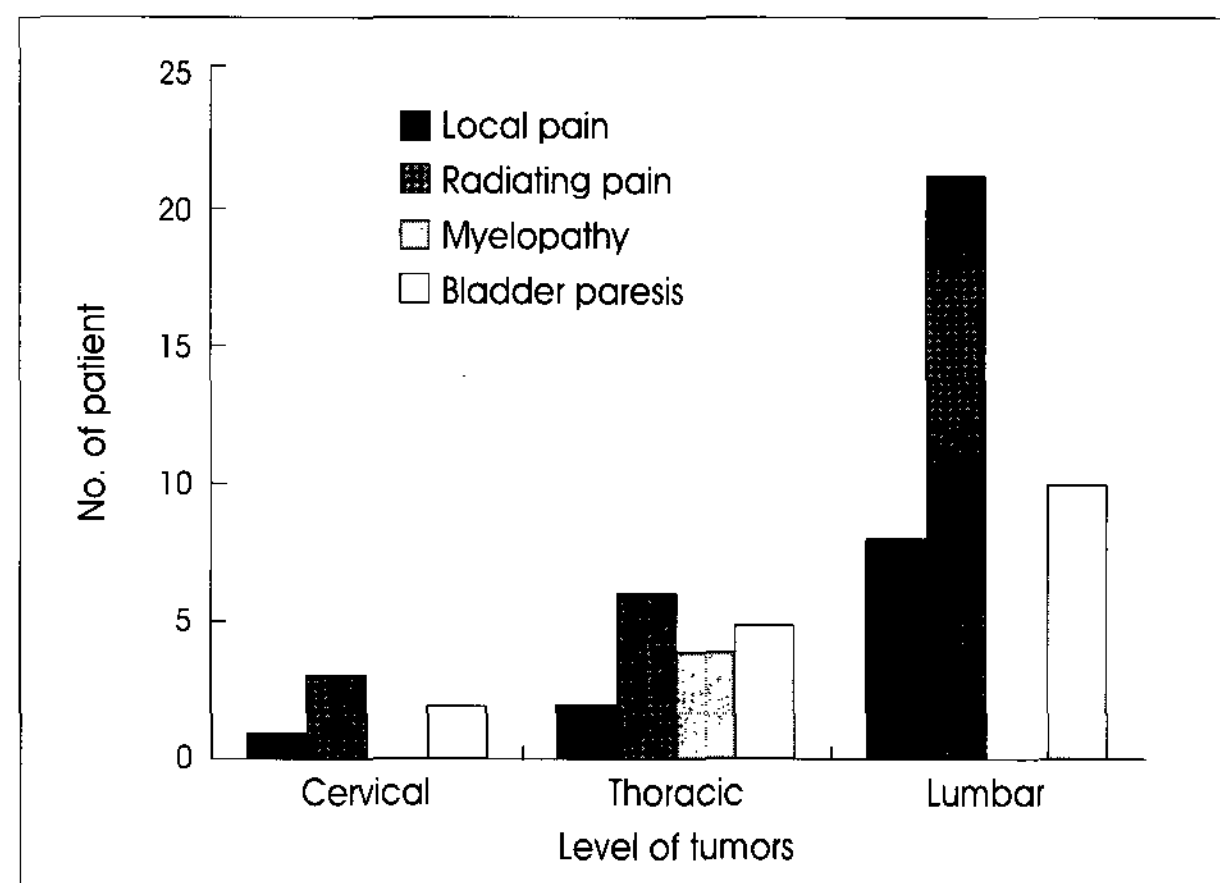


Fig. 1. Bar graph showing initial symptoms at the various spinal levels.

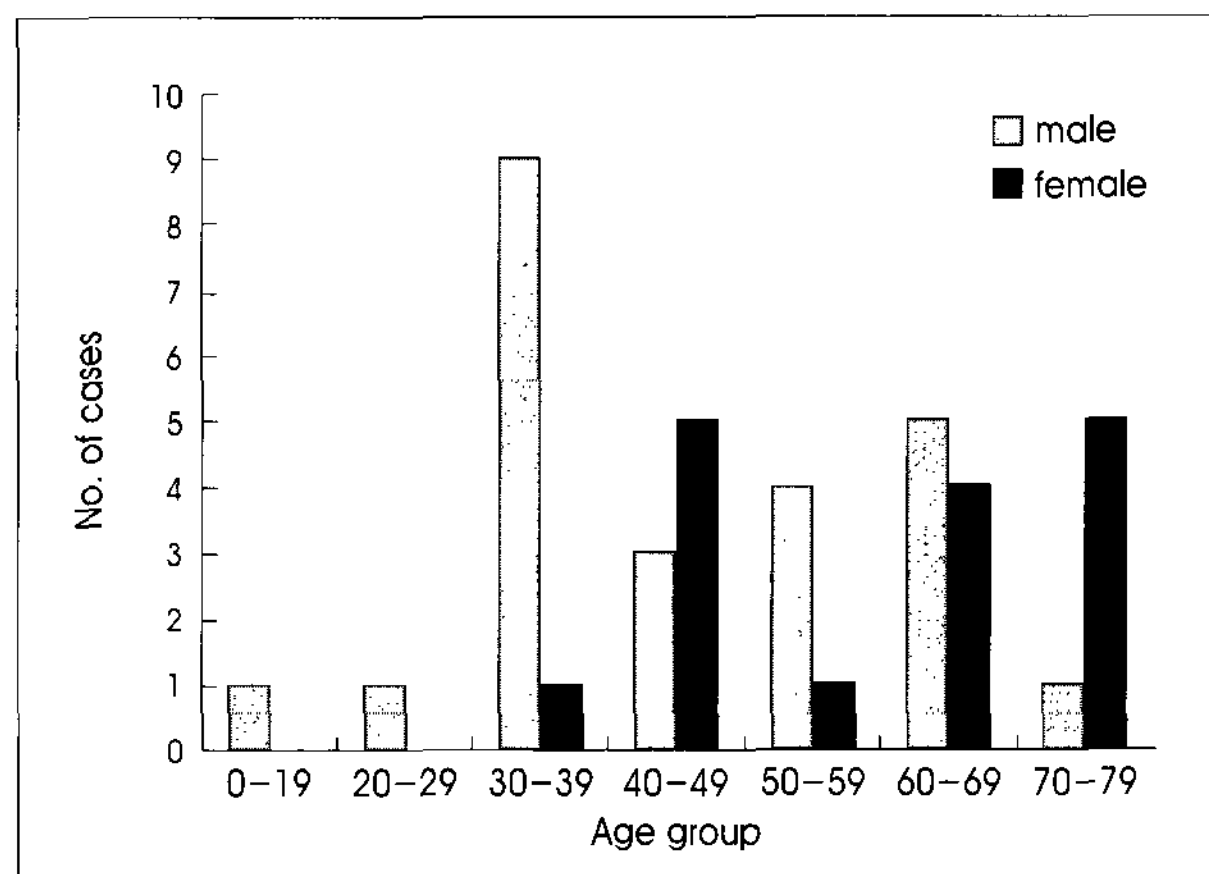


Fig. 2. Bar graph showing distribution of age at diagnosis in spinal schwannomas patients by sex.

Table 1. Location of tumor, preoperative symptom and postoperative outcomes in 40 spinal schwannoma patients

| Characteristics | No. of cases (%) |
|-----------------------------------|------------------|
| Mean Age | 50.2 |
| Sex (M:F) | 24:16 |
| Location | |
| Cervical | 4 (10) |
| Thoracic | 11 (27.5) |
| Lumbar | 25 (62.5) |
| Symptom | |
| Back pain | 11 (27.5) |
| Radiculopathy | 30 (75) |
| Myelopathy | 4 (10) |
| Motor weakness | 16 (40) |
| Voiding difficulty | 17 (42.5) |
| Type | |
| Intradural extramedullary | 38 (95) |
| Extradural | 2 (5) |
| Recurrence | 2 (5) |
| Multiplicity | 1 (2.5) |
| Mean duration of symptom in month | 12.5 |

lesions (62.5%). All tumors were benign and there was no Recklinghausen's Neurofibromatosis (Table 1).

Clinical presentation

The average duration of the symptoms ranged from 1 to 84 months (mean 13.1 months). The most common initial symptom was radicular pain followed by motor weakness, voiding difficulty and myelopathy. There were radicular pain in 75 percents and local back pain in 27.5 percents (Fig. 1).

Table 2. Analysis of recurrent cases

| Case | Sex | Age | Level | Location | Preoperative motor grade | Postoperative motor grade | Preoperative symptom | Voiding difficulty | Prognosis | Postoperative complication |
|------|-----|-----|-------|---------------------------|--------------------------|---------------------------|---------------------------|--------------------|-----------|----------------------------|
| 1 | M | 69 | L4 | Intradural extramedullary | IV | V | Radiculopathy & back pain | Yes | Recovered | No |
| 2 | M | 71 | L4 | Intradural extramedullary | V | V | Radiculopathy | Yes | Stable | No |

The median follow-up time of all cases was 15.9 month. In 36 cases, the schwannomas were intradural extramedullary in 34 cases (95%) and in 2 cases it was extradural (5%). Postoperative histological findings were schwannoma in all cases. At the time of discharge, most of the patients appeared to be significantly improved in comparison with their preoperative neurological status. Two cases (5%) were recurred locally. Both of them were lumbar lesions and had the previous history of subtotal removal. The preoperative symptoms were also segmental radiculopathy with voiding difficulty without motor weakness. One case recovered but another showed persistent symptom after second operation (Table 2).

Operation

All of the tumors were removed surgically via partial or total laminectomy through posterior approach, and every effort was made to prevent postoperative instability. Two cases were done by laminoplasty with wires and titanium plates with screws (Fig. 3). Total removal was achieved in 34 cases (85%) without recurrence but subtotal removal to avoid nerve damage and bleeding were done in 6 cases (15%). Among six cases, two recurrences were seen with development of symptom 12 years later.

DISCUSSION

Spinal schwannomas account for about 25% of primary intradural spinal cord tumors in adults. There is no significant

prevalence difference between males and females^{2,4,5,17,19}. In our series, on the contrary, we noted a somewhat higher prevalence in males, 24 cases (60.0%), with respect to females (40%). The incidence of schwannoma varies with

the age of affected patients who are between the 4th and the 5th decade^{10,17}. In our series, mean age was 50.2 years and peak incidence was also between the 4th and 5th decade (Table 1), (Fig. 2). The tumor presents an ubiquitous evolution in the spine^{16,17}, even if a major incidence in the cervical and lumbar tracts is reported^{5,15-17}. In our study, the higher incidence was seen in the lumbo-sacral spine (62.5%) with a spike between L3 and L4 spines (32.5%). In the literature, 70 to 80% of spinal schwannomas are reported to be intradural in location, and those extending through the dural aperture as a dumbbell mass with both intradural and extradural components account for another 15%^{8,14}. Intra-

Table 3. Results after excision of schwannoma

| Postoperative clinical Sx | Number of Cases (%) |
|---------------------------|---------------------|
| Recovered | 26 (65) |
| Improved | 12 (30) |
| Stable | 2 (5) |
| Worsened | 0 |
| Dead | 0 |

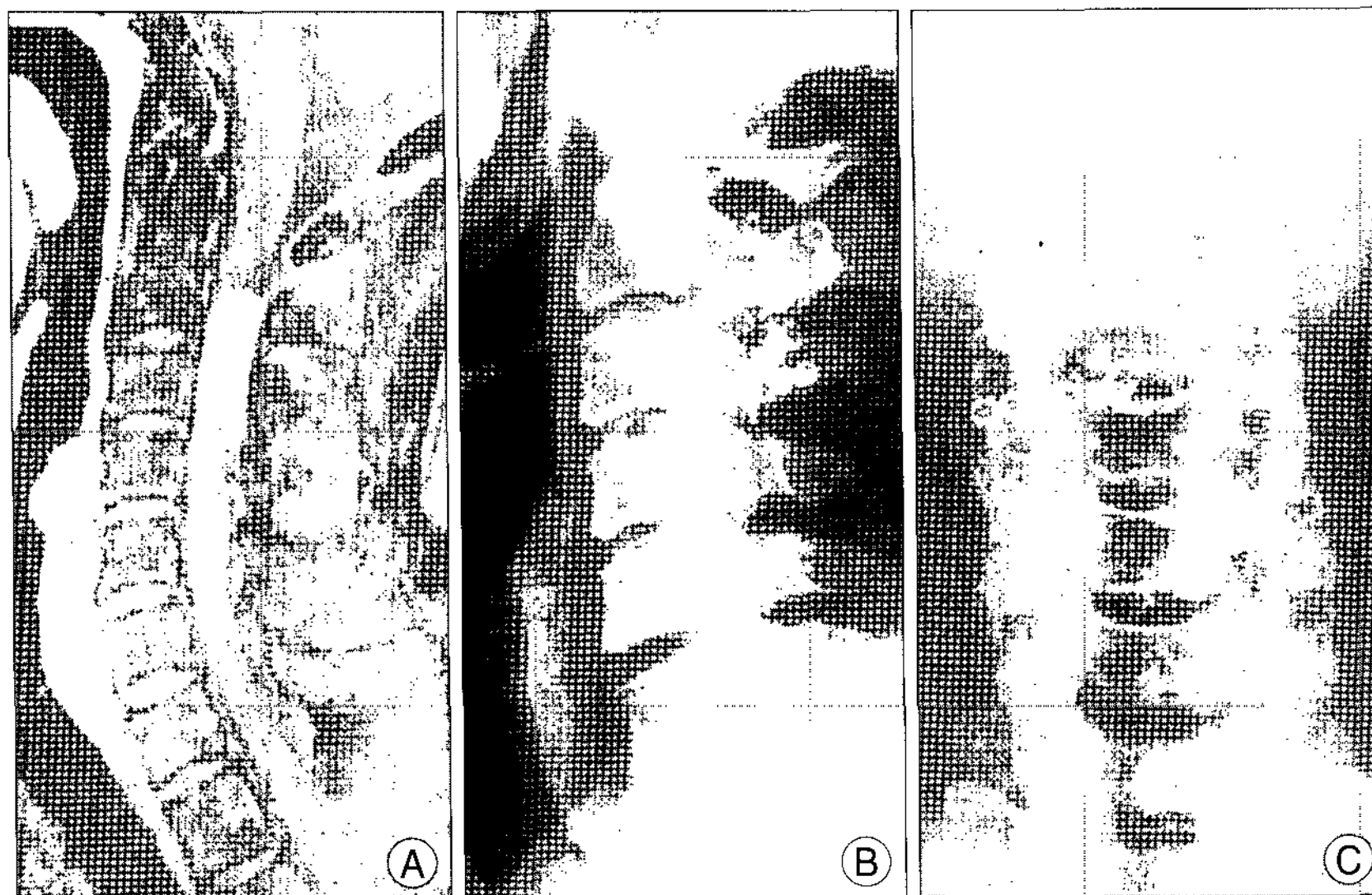


Fig. 3. A 50 year-old man with intradural extramedullary tumor on C2-3 level before and after removal of tumor and laminoplasty. A : Preoperative magnetic resonance imaging shows intradural extramedullary mass-like lesion on C2-3 level. B, C : Postoperative X-rays show laminoplasty state.

medullary schwannomas are extremely rare². We were not able to find intramedullary schwannoma in our series.

The initial symptoms are varied in accordance with the level of the tumor. The pain is localized in one (tumor) place, sometimes spread in both sides, mostly temporarily, but constantly in the same place and hurt as a knife. At the beginning the root pain is attributed to the disturbance of nerve conductivity because of the direct or indirect irritation of nerve root or root compression by the tumor^{2,5}. Later on when compression increases to spinal cord, spinal tracts gets damaged and myelopathy develops^{6,20}. However, motor weakness rarely occurs as an

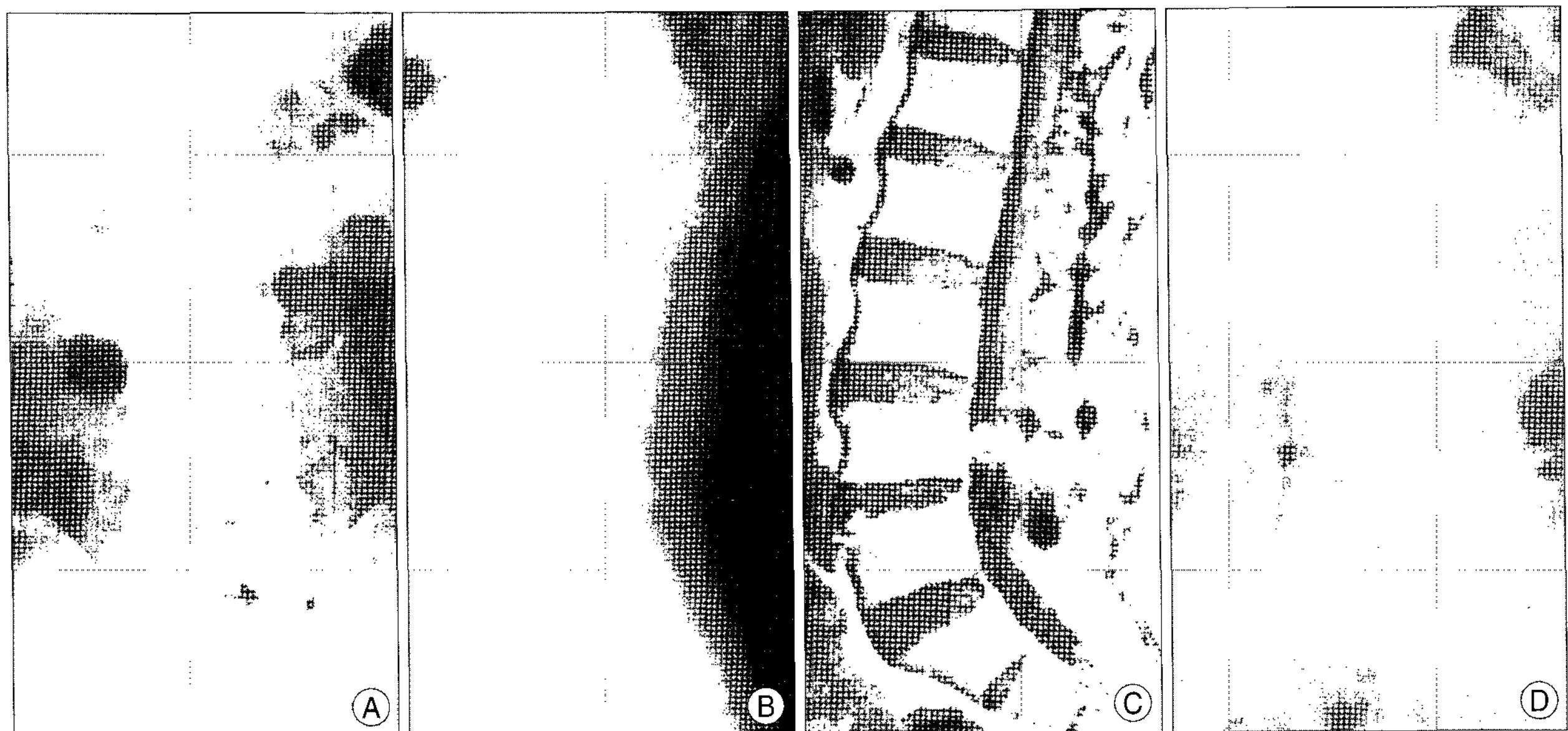


Fig. 4. A 70 year-old man with intradural extramedullary tumor on L4 level before and after removal of tumor and laminoplasty. A, B : Postoperative X-rays show L4 laminoplasty state with wiring on L1-4 level due to previous operation caused by schwannoma before 8 years. C : Preoperative magnetic resonance image showing intradural extramedullary mass-like lesion on L4 level. D : Second postoperative X-ray shows L4 laminoplasty revision state.

initial symptom in the lumbosacral region. Motor weakness of the lower extremity may not be obvious until the later stage, as in patients with lumbar canal stenosis. Although total resection of spinal nerve sheath tumors has been considered to be feasible^{6,20}, some cases have resected incompletely^{3,12}. There may be two obstacles to total resection : one is adhesion to the spinal cord because of hemorrhage, inflammation, or subpial localization; the other is critical structures attached to extradural components outside the spinal canal in the cervical region, such as the vertebral artery. In our study, total resection was not achieved in two cases because of these obstacles (Table 2). However, a good grasp of the anatomy of surrounding structures and meticulous surgical techniques could overcome these obstacles. In case of residual tumor, a long-term observation is needed⁸.

The degree of angulations during the development of kyphosis after laminectomy is highly correlated with removal of facet joints¹¹. Although no facets are removed, a gradual rounded kyphosis might develop. With removal of facets bilaterally at one or more levels, acute angular kyphosis tends to occur. Unilateral facetectomy may predispose to angular kyphosis and scoliosis and angular kyphosis may lead to spinal cord compression despite the lack of recurrent tumor¹¹. Osteoplastic laminoplasty for spinal cord tumors in a few children was reported by Abbott et al.¹; however, there were not enough data to convince the effectiveness of this procedure. Another study by Kim et al. showed that the laminoplasty prevent postoperative spinal deformities after removal of spinal cord tumors in 16 cases of laminoplasty compared with 89 cases of laminectomy¹⁸. Kawahara et al. performed recapping T-Saw laminoplasty for spinal cord tumors in 24 patients. They reported that complications such as postoperative spinal canal stenosis, facet arthrosis, or kyphosis were not observed⁹. We experienced two cases of laminoplasty on C2-C3 and L2-L3. It could be helpful to dissect the epidural space at the time of second operation due to recurred lesion on L4 (Table 2), (Fig. 3, 4). As a rule of thumb, unilateral facetectomy in adults does not require fusion for tumors in the cervical or thoracic spine but might be necessary for those located in the lumbar spine.

The outcome of schwannoma correlates to preoperative neurological condition of patient^{13,20}. The symptoms and signs of our patients improved in 95 percent (Table 3). Total removal of neurofibromas and schwannomas that are not associated with neurofibromatosis is generally curative. However, tumors with extensive paraspinal involvement that are subtotally resected have a definite propensity to recur. Deficits resulting from sacrifice of the involved nerve roots are usually minor and well tolerated^{6,17}. Otherwise, we experienced two recurrences among 6 cases by subtotal removal to avoid the nerve roots injury.

CONCLUSION

Surgery for spinal schwannomas usually result in good postoperative functional outcomes. Although there could be recurrence in cases of previous subtotal removal, these also show good or stable prognosis. The laminoplasty will be helpful to the second operation in recurrent tumor.

References

- Abbott R, Feldstein N, Wisoff JH, Epstein FJ : Osteoplastic laminotomy in children. *Pediatr Neurosurg* 18 : 153-156, 1992
- Celli P, Trillo G, Ferrante L : Spinal extradural schwannoma. *J Neurosurg Spine* 2 : 447-456, 2005
- Conti P, Pansini G, Mouchaty H, Capuano C, Conti R : Spinal neurinomas : retrospective analysis and long-term outcome of 179 consecutively operated cases and review of the literature. *Surg Neurol* 61 : 34-43; discussion 44, 2004
- De Verdelhan O, Haegelen C, Carsin-Nicol B, Riffaud L, Amlashi SF, Brassier G, et al : MR imaging features of spinal schwannomas and meningiomas. *J Neuroradiol* 32 : 42-49, 2005
- Dorsi MJ, Belzberg AJ : Paraspinal nerve sheath tumors. *Neurosurg Clin N Am* 15 : 217-222, 2004
- Hori T, Takakura K, Sano K : Spinal neurinomas--clinical analysis of 45 surgical cases. *Neurol Med Chir (Tokyo)* 24 : 471-477, 1984
- Jung JH, Park HC, Choi HY, Kim MH, Park HK, Kim SH, et al : A clinical analysis of the primary spinal tumors. *J Korean Neurosurg Soc* 25 : 1189-1195, 1996
- Jinnai T, Koyama T : Clinical characteristics of spinal nerve sheath tumors : analysis of 149 cases. *Neurosurgery* 56 : 510-515; discussion 510-515, 2005
- Kawahara N, Tomita K, Shinya Y, Matsumoto T, Baba H, Fujita T, et al : Recapping T-saw laminoplasty for spinal cord tumors. *Spine* 24 : 1363-1370, 1999
- Klekamp J, Samii M : Surgery of spinal nerve sheath tumors with special reference to neurofibromatosis. *Neurosurgery* 42 : 279-289; discussion 289-290, 1998
- Lonstein JE : Post-laminectomy kyphosis. *Clin Orthop Relat Res* : 93-100, 1977
- Lot G, George B : Cervical neuromas with extradural components : surgical management in a series of 57 patients. *Neurosurgery* 41 : 813-820; discussion 820-822, 1997
- Mathew P, Todd NV : Intradural conus and cauda equina tumours : a retrospective review of presentation, diagnosis and early outcome. *J Neurol Neurosurg Psychiatry* 56 : 69-74, 1993
- McCormick PC, Post KD, Stein BM : Intradural extramedullary tumors in adults. *Neurosurg Clin N Am* 1 : 591-608, 1990
- Miura T, Nakamura K, Tanaka H, Kawaguchi H, Takeshita K, Kurokawa T : Resection of cervical spinal neurinoma including affected nerve root : recovery of neurological deficit in 15 cases. *Acta Orthop Scand* 69 : 280-282, 1998
- Selosse P, Granieri U : [Spinal intradural meningiomas and neurinomas. Review of the literature and current situation]. *Neurochirurgie* 14 : 135-154, 1968
- Seppala MT, Haltia MJ, Sankila RJ, Jaaskelainen JE, Heiskanen O : Long-term outcome after removal of spinal schwannoma : a clinicopathological study of 187 cases. *J Neurosurg* 83 : 621-626, 1995
- Kim SH, Chin DK, Yoon YS, Jin BH, Cho YE, Kim YS : Spinal instability following for spinal cord tumors : laminoplasty vs. laminectomy. *J Korean Neurosurg Soc* 30 : S61-67, 2001
- Sharma S, Sarkar C, Mathur M, Dinda AK, Roy S : Benign nerve sheath tumors : a light microscopic, electron microscopic and immunohistochemical study of 102 cases. *Pathology* 22 : 191-195, 1990
- Subaciate J : [Early diagnosis of spinal cord schwannoma : the significance of the pain syndrome]. *Medicina (Kaunas)* 38 : 1086-1088, 2002