

## Case Report

In Ho Park, M.D.<sup>1</sup>  
 Hyeun Sung Kim, M.D.<sup>1</sup>  
 Sung Kuen Park, M.D.<sup>1</sup>  
 Seok Won Kim, M.D.<sup>2</sup>

*Department of Neurosurgery<sup>1</sup>  
 Mokpo Hankook Hospital  
 Mokpo, Korea*

*Department of Neurosurgery<sup>2</sup>  
 School of Medicine  
 Chosun University  
 Gwangju, Korea*

# Traumatic Pseudoaneurysm of the Superficial Temporal artery Diagnosed by 3-dimensional CT Angiography

Pseudoaneurysm arising from the superficial temporal artery (STA) is a rare and potentially critical cause of palpable mass. Most pseudoaneurysms form as a result of blunt trauma and present as painless, pulsatile mass that may be associated with pathologic finding and enlarged size. We report a rare case of pseudoaneurysm arising from STA caused by blunt injury and diagnosed by 3-dimensional computed tomography (CT) angiography.

**KEY WORDS :** Pseudoaneurysm · Superficial temporal artery · Three-dimensional CT angiography.

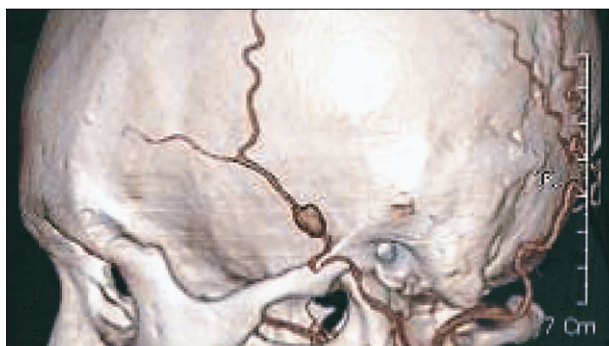## INTRODUCTION

Pseudoaneurysm presents rarely as a cause of facial mass. However, the condition should be considered by neurosurgeons as a facial mass in patients with recent traumatic head injury. Neurosurgeons should differentiate pseudoaneurysms from cyst, dermal lesions, and various aneurysms by taking a good history, careful palpation, auscultation and using ancillary testing if necessary. Such care will help to ensure that patients are properly diagnosed and treated. Digital subtraction angiography is the most commonly used imaging technique and is the criterion standard with which to evaluate the vessels of the head and neck. However, it carries about 5% overall complication rate, including a small risk of stroke<sup>4</sup>). The development of CT angiography offers a minimally invasive alternative to digital subtraction angiography in the diagnosis and characterization of STA pseudoaneurysms. We report a patient with a traumatic pseudoaneurysm arising from the preauricular branch of STA diagnosed by 3-dimensional CT angiography.

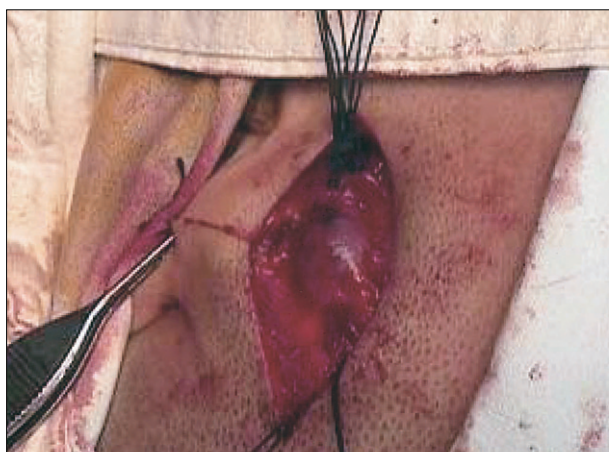
## CASE REPORT

A 27-year-old woman visited our institute with a painless palpable mass in the anterosuperior to the left tragus area. She lost her balance while working and bumped her head on the corner of a wall 10 days earlier. The initial swelling she had after the injury subsided within one day, but a new, well-defined mass became palpable 3 days later. The patient noted a pulse within the mass. On physical examination, about 1.2 × 1.5-cm pulsatile swollen bump was palpated and the mass was easily compressible with digital pressure, and bruit was appreciable on auscultation. Proximal compression of the temporal artery eliminated the pulsation of the mass. Cranial nerve examination demonstrated no deficits. Computerized tomography of the head revealed neither acute abnormality nor extracranial mass. Three-dimensional CT angiography was performed by using a GE lightspeed scanner (General Electric Medical Systems, Milwaukee, WI). Three-dimensional CT angiography revealed a 1.2 × 1.4 × 1.6 cm oval pseudoaneurysm arising off the main trunk of the left STA (Fig. 1). The STA distal to the origin of the pseudoaneurysm coursed along the ventral surface of the pseudoaneurysm and continued on as the frontal and parietal branch. The pseudoaneurysm was immediately superior to the posterior margin of the zygomatic arch and approximately 1 cm superior to the external auditory canal (Fig. 1). Sedation and local anesthetics provided adequate anesthesia for surgical exploration, which revealed pseudoaneurysm. On dissection and ligation of main trunk of STA, pseudoaneurysm was resected (Fig. 2). The patient recovered uneventfully after surgery.

- Received : January 17, 2008
- Accepted : April 7, 2008
- Address for reprints :  
 Seok Won Kim, M.D.  
 Department of Neurosurgery  
 School of Medicine, Chosun  
 University, 588 Seoseok-dong  
 Dong-gu, Gwangju 501-717, Korea  
 Tel : +82-62-220-3120, 3126  
 Fax : +82-62-227-4575  
 E-mail : chosunns@hanmail.net



**Fig. 1.** Three-dimensional computed tomography angiogram of the left external carotid artery showing an aneurysm of the preauricular branch of the superficial temporal artery.



**Fig. 2.** Intraoperative digital photograph showing dissection and ligation of main trunk of STA for pseudoaneurysm.

## DISCUSSION

The superficial temporal artery is the most frequent site of craniofacial traumatic aneurysm because of its anatomic location. The STA arises from the external carotid artery at the border of the parotid gland, and the temporalis muscle is the only protective tissue present between the STA and the outer table of the skull<sup>10</sup>. Blunt injuries are the most common cause of traumatic STA pseudoaneurysms. These include various sports related injuries, skull fractures, and accidents. Blunt injuries have accounted for more than 75% of cases<sup>1,2,9,10</sup>. Most traumatic STA aneurysms have presented as a single painless pulsating mass with headache or ear discomfort. Pain may result from pressure on the surrounding structures or nerves. Patients also complain of visual disturbance, dizziness, hemorrhage, or cosmetic and neurologic deficits, depending on the location. Most aneurysms manifest within 2 to 6 weeks of injury, though some are seen much earlier, within 2 to 4 days. In this case, the patient recognized the pulsating mass at 7 days after trauma. The mass was easily detected because of its location. Depending on the location

and depth of the artery, pseudoaneurysms can occur from either blunt or penetrating injury. They may present asymptotically or as nontender, expanding, pulsatile masses found along the course of an artery, as in the cases described headache, ear discomfort, visual disturbance, dizziness, hemorrhage, unacceptable cosmetic, and neurologic deficit. A thrill or bruit may or may not be appreciable. Compression of the proximal artery should eliminate the pulse and diminish the size of the mass. Cranial nerve palsies, paresthesias, and vascular compromise have been reported and may be evident if the pseudoaneurysm leaks or ruptures<sup>5,6</sup>. Imaging studies in the assessment of probable STA pseudoaneurysm include sonography, CT, MR imaging, and digital subtraction angiography. In one review of 35 cases, more than 90% underwent radiologic examination. Of those, more than 50% underwent digital subtraction angiography to verify the aneurysm and characterize the afferent and efferent vessels<sup>8</sup>. Arteriography is the diagnostic study of choice, and selective angiography with subtraction technique may better demarcate small aneurysms. Although digital subtraction angiography is the criterion-standard examination, it is an invasive procedure with a small but definite risk of stroke<sup>4</sup>. Additionally, digital subtraction angiography will characterize only the patient component of the pseudoaneurysm, which can lead to an underestimation of lumen size depending on the degree of thrombus within the aneurysm. Sonography is a noninvasive technique, but it provides little information about the adjacent soft tissues and osseous structures and would be less specific in the setting of a partially or completely thrombosed pseudoaneurysm. MR angiography is also noninvasive, but expensive imaging strategy that can highlight the soft tissue abnormality and its relationship to the adjacent soft tissues. Three-dimensional CT angiography can assess the patency and position of the main trunk and distal branches of the STA, including the facial, frontal, and parietal branches. The true size of the pseudoaneurysm is accurately depicted with CT angiography, including the degree of thrombosis versus the amount of luminal opacification. The adjacent calvaria is easily assessed for fractures and any potential communication with the intracranial compartment. It can show extracranial masses and intracranial pathology simultaneously. In the current case, 3-dimensional CT angiography alone confirmed the diagnosis, provided important anatomic information to the neurosurgeon before surgery, and eliminated the risks associated with digital subtraction angiography. Conservative measures are not recommended as the mass may continue to cause discomfort, headaches, disfigurement, and potentially lethal hemorrhage. Although some sources claim that superficial temporal artery pseudoaneurysmal resection is most commonly done for cosmetic reasons,

the potential for hemorrhage or enlargement necessitates removal of the lesion and, thus, the procedure is considered reconstructive<sup>3</sup>.

## CONCLUSION

Although, its incidence is very rare, the neurosurgeons should consider the possibility of a traumatic pseudoaneurysm in case of pulsatile palpable mass chronologically related to trauma around preauricular region. The 3-dimensional CT angiography can accurately depict the morphology of the traumatic pseudoaneurysm of STA without associated risks of digital subtraction angiography.

## References

1. Choo MJ, Yoo IS, Song HK : A traumatic pseudoaneurysm of the superficial temporal artery. *Yonsei Med J* 39 : 180-183, 1998
2. Cross WR, Nishikawa H : Traumatic pseudoaneurysm of the superficial temporal artery. *J Accid Emerg Med* 16 : 73, 1999
3. Conner WC 3rd, Rohrich RJ, Pollock RA : Traumatic aneurysms of the face and temple : a patient report and literature review, 1644 to 1998. *Ann Plast Surg* 41 : 321-326, 1998
4. Heiserman JE, Dean BL, Hodak JA, Flom RA, Bird CR, Drayer BP, et al : Neurologic complications of cerebral angiography. *AJNR Am J Neuroradiol* 15 : 1401-1407; discussion 1408-1411, 1994
5. Lalak NJ, Farmer E : Traumatic pseudoaneurysm of the superficial temporal artery associated with facial nerve palsy. *J Cardiovasc Surg (Torino)* 37 : 119-123, 1996
6. Lee KS, Gower DJ, McWhorter JM : Aneurysm of the superficial temporal artery. *Neurosurgery* 23 : 499-500, 1988
7. Matsubara J, Shionoya S, Ban I, Nakata Y, Miyazaki H : False aneurysm of the superficial temporal artery. *Am J Surg* 124 : 419-421, 1972
8. Peick AL, Nichols WK, Curtis JJ, Silver D : Aneurysms and pseudoaneurysms of the superficial temporal artery caused by trauma. *J Vasc Surg* 8 : 606-610, 1988
9. Pennington C, Lewis JV : Traumatic pseudoaneurysm of the superficial temporal artery. *Tenn Med* 90 : 284, 1997
10. Schechter MM, Gutstein RA : Aneurysms and arteriovenous fistulas of the superficial temporal vessels. *Radiology* 97 : 549-557, 1970