

Histomorphometric analysis of an immediate non-functional loaded implant in dogs

Jeong-Wan Ha¹, Su-Gwan Kim¹, Hak-Hyun Kim¹, Seong-Yong Moon¹, Sung-Chul Lim²

¹Department of Oral & Maxillofacial Surgery, College of Dentistry, Chosun University, Gwangju, Korea

²Department of Pathology, College of Medicine, Chosun University, Gwangju, Korea

Abstract

The purpose of this study was to investigate the effects of immediate non-functional loading by analyzing histomorphology around the implant tissues in dogs. Five eight- to nine-month-old full-grown dogs weighing around 12 kg were used in the study. Group I (control group) comprised those in which delayed loading was applied to the right side of the mandible, and Group II (experimental group) consisted of dogs in which immediate loading was performed on the left side of the mandible. Resorbable blast media (RBM)-treated double-threaded US III implants measuring 3.5 mm in diameter and 11 mm long were used in the study. Each animal received four implants in each group, for a total of 40 implants. Cemented type abutments were used after implantation. An 8-week period was allowed for bone healing and an abutment was placed after exposing the periosteum for loading. An implant sample was obtained from bone blocks taken when the dogs were killed at 16 weeks after loading. A Mann-Whitney U-test was performed to evaluate statistical significance. Student's t-test was used for the histological evaluation. The bone formation ratio in Groups 1 and 2 was 88.23 and 86.41%, respectively. No significant difference in new bone formation was observed in the two groups. As no significant difference was seen in new bone formation between the delayed and immediate loading groups, early loading might be possible after implant placement.

Key words

Histomorphometric analysis; Immediate non-functional loaded implant

INTRODUCTION

Dental implantation has been benefited greatly from research into the biological characteristics of titanium. According to the existing protocol, to obtain predictable osseointegration, loading should be avoided while the subperiosteum heals during two-stage surgery. However, the discomfort and anxiety that occur during the healing period are issues that must be resolved for both the physician and patient. Therefore, attempts have been made to apply immediate loading after surgery with the extensive support of clinicians¹.

We are faced with two conflicting approaches to dental implantation: the traditional method requiring a long

healing period and the ultrafast method of applying early loading. Although only a few years ago, immediate or early loading was considered possible only in areas with good bone quality, such as the anterior portion of the mandible, early loading is possible with a single implant even in areas with poor bone quality, such as the posterior portion of the maxilla. We therefore need to reevaluate the Branemark protocol¹.

A healing period without loading is still considered a prerequisite for implant integration², which leads to extended treatment periods, often with delayed functional improvement for the patient^{3,4}. The elimination or reduction of the postsurgical interval between implant placement and implant loading is a challenge for dental implantology. Early loading has been found to induce micromotion at the bone-implant interface, which may lead to fibrous encapsulation instead of direct bone apposition^{3,4}.

Implants that were loaded immediately and implants that were not loaded immediately have been compared

* Corresponding author

Su-Gwan Kim

Dept. of OMFS, College of Dentistry, Chosun University
421, SeoSukDong, DongGu, GwangJu City, 501-825, Korea
Tel: 82-62-220-3815 Fax: 82-62-228-7316
E-mail: sgckim@chosun.ac.kr

histologically in animal studies⁵). The histological findings from one animal study demonstrated that immediately loaded blade implants with hydroxyapatite (HA)-coated surfaces, when splinted together with teeth, form a direct bony interface similar to delayed loaded HA-coated blade implants in nonhuman primates⁶). Other study in dogs has found less BIC in the immediately loaded implant in comparison to delayed-loaded implants⁷).

The purpose of this study was to investigate the effects of immediate non-functional loading by analyzing histomorphology around the implant tissues in dogs.

MATERIALS AND METHODS

Study animals

Five eight- to nine-month-old full-grown dogs weighing around 12 kg were used in the study. They were all healthy and reared under the same conditions. Animals of both genders were selected. Group I (control group) comprised those in which delayed loading was applied to the right side of the mandible, and Group II (experimental group) consisted of dogs in which immediate loading was performed on the left side of the mandible.

Anesthesia

After the dog was placed under general anesthesia with an intramuscular injection of 0.4 mg/kg xylazine (Rompun, Bayer-Vetchem, Seoul, Republic of Korea) and 0.15 ml/kg ketamine (Ketara, Yuhan, Seoul, Korea) in the thigh, 2% lidocaine was used to prevent bleeding and pain at the implant site.

Extraction

Forceps were used to extract the 2nd to 4th premolars and 1st molar in the mandible in the control and experimental groups. The residual root and granulation tissue were removed completely at the time of extraction. A 12-week healing period was allowed in the control and experimental groups. The extraction in the experimental group was done 8 weeks after the extraction in the control group to match the loading period. Suturing was not performed in all groups. Gentamicin (0.09 ml/kg) was injected intramuscularly for 5 days in all animals after extraction and implant placement to prevent infection.

Implants

Resorbable blast media (RBM)-treated double-threaded US III implants (OSSTEM Implant, Seoul, South Korea) measuring 3.5 mm in diameter and 11 mm long were used in the study. Each animal received four implants in each group, for a total of 40 implants. Cemented type abutments were used after implantation.

Implant placement and loading

Anesthesia was administered using the same method in all animals. The tissues were dissected to lift a periosteal flap using a periosteal elevator. Four implants were placed in each group. A cover screw was used to delay loading in the control group. After dental implantation, black silk was used for suturing. After radiography, gentamicin was administered to prevent infection. An 8-week period was allowed for bone healing and an abutment was placed after exposing the periosteum for loading. The same method was used in the experimental group, with an abutment placed for early loading follow-

Table 1. Experimental schedule

Group	Schedule					
Group 1 (Control)	Extraction	12-week healing period	Implant placement	Osseointegration 8 weeks	Load application	Killed at 16 weeks
Group 2 (Experimental)	8 weeks Extraction		12-week healing period	No osseointegration	Implantation and loading	Killed at 16 weeks

ing suturing. A temporary prosthesis was prepared using temporary resin. Occlusion was adjusted in all groups to avoid direct contact with the implants (Table 1).

Histological and histomorphometric evaluation

An implant sample was obtained from bone blocks taken when the dogs were killed at 16 weeks after loading. The bone block including the implant portion was fixed in neutral formalin for 6 days immediately and then dehydrated in alcohol. It was embedded in glycol-methacrylate resin (Spurr's low-viscosity embedding media; Polyscience, Harrington, PA, USA). The polymerized sample was cut using a high-precision diamond disk (low-speed diamond wheel saw 650; SBT, San Clemente, CA, USA) in the axial direction of the implant in 200- μ m slices. Finally, 30- μ m-thick slices were prepared using a lapping and polishing machine (OMNI-LAP 2000; SBT). One slice of each implant was stained with Villanueva osteochrome bone stain (SBT) and observed under an optical microscope (BX50; Olympus, Tokyo, Japan).

Statistical analysis

A Mann-Whitney U-test was performed to evaluate statistical significance. Student's t-test was used for the histological evaluation. Values less than 0.05 were considered statistically significant.

RESULTS

Group 1

Abundant new bone formation was observed with woven bone closely surrounding the implant screw. The implant was exposed in the top right (arrow; Fig. 1).

Group 2

Abundant new bone formation was observed with woven bone closely surrounding the implant screw. The new bone formation was insufficient in the left middle and lower right portions (arrow; Fig. 2). The implant was exposed overall (black arrow; Fig. 3).

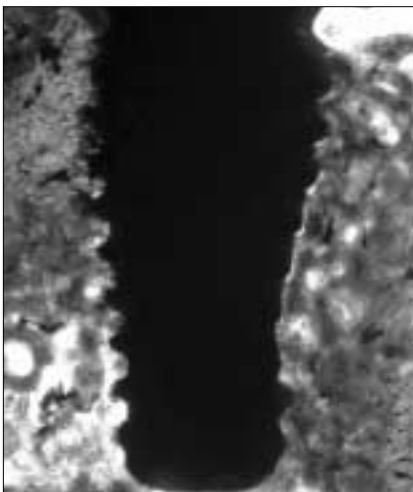


Fig. 1. Photomicrograph of Group 1. Woven bone is seen filling the peri-implant space. A small part of the implant is exposed in the right upper corner (arrow) (Villanueva osteochrome stain, original magnification $\times 40$).




Fig. 2. Photomicrograph of Group 2. Woven bone filled the peri-implant space. Foci of insufficient new bone formation are seen in the left-middle and right-lower portions of the implant (arrows) (Villanueva osteochrome stain, original magnification $\times 40$).

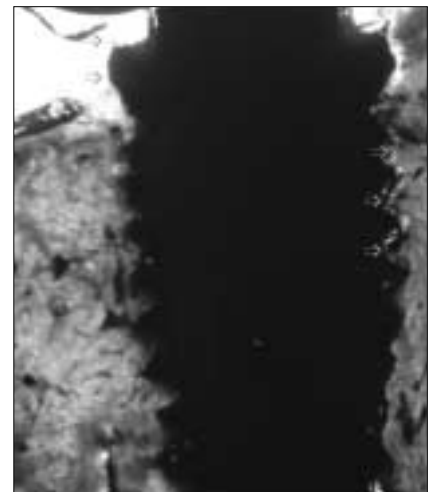


Fig. 3. Photomicrograph of Group 2. Woven bone filled the peri-implant space. A focus of insufficient new bone formation is seen in part of the right portion of the implant (white arrows). The uppermost part of the implant (black arrows) is exposed (Villanueva osteochrome stain, original magnification $\times 40$).

Table 2. Histomorphometric results

	Rate of new bone formation (%)
Group 1 (Control group)	88.23 ± 7.15
Group 2 (Experimental group)	86.41 ± 9.63

P > 0.05

Histomorphometric result (Table 2)

The bone formation ratio in Groups 1 and 2 was 88.23 and 86.41%, respectively. No significant difference in new bone formation was observed in the two groups.

DISCUSSION

The success with dental implants in the mandible suggests the possibility of other surgical and prosthodontic treatments⁸. Patients prefer implants that allow early or immediate loading because they want both an early recovery of mastication and hastened cosmetic recovery.

Immediate loading has recently become one of the main research topics in restorative dentistry. The main objective of immediate loading is to achieve high mechanical stability, while avoiding micromovement during the course of osseointegration⁹. The success of immediate loading depends on bone quality and quantity, as well as on the healing potential of bone. With low bone density, the implant should be fixed by waiting for active formation of the implant-sheath bone with no loading for 3 to 6 months post-implantation¹⁰.

The development of mineralized bone at the interface of immediately loaded implants depends on two key factors. First, micromovement of the implant must be avoided to create a static environment for bone healing. Second, the appropriate biological principles must be used to avoid the formation of connective tissue and to achieve close bone-to-implant contact¹¹.

Regarding immediate loading protocols, Akagawa et al.¹² compared early loaded screw implants with non-loaded implants in preclinical models. Although not quantified, both studies reported greater marginal bone loss for the early loaded group after 3 months of loading. It was suggested that the high crestal bone loss was a specific feature of the early loading protocols.

Romanos et al.⁵ reported that immediately loaded implants retrieved from humans showed a high percent-

age of BIC after loading periods of 2 and 10 months in a histological and histomorphometric analysis. This observation was independent of the implant system used, and the implants examined had a screw-geometry and rough surfaces designed to promote new bone formation at the initial stages of healing during loading.

According to the literature, an osseointegrated, clinically stable implant is associated with a BIC of at least 25%¹³. This is dependent on the implant form, the surgical procedure, the loading forces involved, and the loading period. Therefore, we investigated the rate of peri-implant bone formation rather than the rate of BIC. The rate of peri-implant bone formation was the area of newly formed bone divided by the area outside the implant thread, expressed as a percentage.

Romanos and Nentwig¹⁴ used Ankylos implants in monkeys and reported that the rate of BIC did not differ significantly between no-load and immediate-load groups at 50.20 and 64.25%, respectively. Zubery et al.¹⁵ obtained rates of 58.4 and 50.0% in no-load and immediate-load groups, respectively, in dogs fitted with interim implants.

Froum et al.¹⁶ reported a BIC percentage of 40 to 72% in humans. Ledermann et al.¹⁷ also reported high percentages of BIC (70-80%) after examining four immediately loaded mandibular implants retrieved from a person after 12 years of function.

CONCLUSIONS

In this study, we obtained rates of new bone formation of 88.23 and 86.41% in the control and immediate loading groups, respectively. The difference between the two groups was not significant. As no significant difference was seen in new bone formation between the delayed and immediate loading groups, early loading might be possible after implant placement. This treatment concept may prove successful for daily clinical practice in properly selected cases.

REFERENCES

1. Kim SG: Immediate post-extraction implant and immediate loading implant. Seoul, Daehan Publishing Co, 2005, p 139.
2. Corso M, Sirota C, Fiorellini J, Rasool F, Szmukler-Moncler S, Weber HP: Clinical and radiographic evaluation of early loaded free-standing dental implants with various coatings in beagle dogs. *J Prosthet Dent* 1999;82:428-435.
3. Albrektsson T, Zarb G, Worthington P, Eriksson AR: The long-term efficacy of currently used dental implants: a review and proposed criteria of success. *Int J Oral Maxillofac Implants* 1986;1:11-25.
4. Albrektsson T, Sennerby L: State of the art in oral implants. *J Clin Periodontol* 1991;18:474-481.
5. Romanos GE, Testori T, Degidi M, Piattelli A: Histologic and histomorphometric findings from retrieved, immediately occlusally loaded implants in humans. *J Periodontol* 2005;76:1823-1832.
6. Lum LB, Beirne OR, Curtis DA: Histologic evaluation of hydroxylapatite-coated versus uncoated titanium blade implants in delayed and immediately loaded applications. *Int J Oral Maxillofac Implants* 1991;6:456-462.
7. Sagara M, Akagawa Y, Nikai H, Tsuru H: The effects of early occlusal loading on one-stage titanium alloy implants in beagle dogs: a pilot study. *J Prosthet Dent* 1993;69:281-288.
8. Tarnow DP, Emtiaz S, Classi A: Immediate loading of threaded implants at stage 1 surgery in edentulous arches: Ten consecutive case reports with 1-to 5-year data. *Int J Oral Maxillofac Implants* 1997;12:319-324.
9. Brunski JB: Avoid pitfalls of overloading and micromotion of intraosseous implants. *Dent Implantol Update* 1993;4:77-81.
10. Kawahara H, Kawahara D, Hayakawa M, Tamai Y, Kuremoto T, Matsuda S: Osseointegration under immediate loading: biomechanical stress-strain and bone formation-resorption. *Implant Dent* 2003;12:61-68.
11. Frost HM: The biology of fracture healing. An overview for clinicians. Part I. *Clin Orthop Relat Res* 1989;248:283-293.
12. Akagawa Y, Ichikawa Y, Nikai H, Tsuru H: Interface histology of unloaded and early loaded partially stabilized zirconia endosseous implant in initial bone healing. *J Prosthet Dent* 1993;69:599-604.
13. Roberts WE, Garetto LP, DeCastro RA: Remodeling of devitalized bone threatens periosteal margin integrity of endosseous titanium implants with threaded or smooth surface: Indications for provisional loading and axially directed occlusion. *J Indiana Dent Assoc* 1989;68:19-24.
14. Romanos GE, Nentwig GH: Single molar replacement with a progressive thread design implant system: a retrospective clinical report. *Int J Oral Maxillofac Implants* 2000;15:831-836.
15. Zubery Y, Bichacho N, Moses O, Tal H: Immediate loading of modular transitional implants: a histologic and histomorphometric study in dogs. *Int J Periodont Restorative Dent* 1999;19:343-353.
16. Froum S, Emtiaz S, Bloom MJ, Scolnick J, Tarnow DP: The use of transitional implants for immediate fixed temporary prostheses in cases of implant restorations. *Pract Periodontics Aesthet Dent* 1998;10:737-746.
17. Ledermann PD, Schenk Rk, Buser D: Long-lasting osseointegration of immediately loaded, bar-connected TPS screws after 12 years of function: a histologic case report of a 95-year-old patient. *Int J Periodontics Restorative Dent* 1998;18:552-563.