

# Chondrosarcoma in the mandibular condyle : Case report

Kyoung-In Yun, Min-Kyu Park\*, Chang-Hyn Kim\*, Je-Uk Park\*

*Department of Oral and Maxillofacial Surgery, College of Medicine, Chung-Ang University*

*\*Department of Oral and Maxillofacial Surgery, School of Medicine, Catholic University of Korea*

## Abstract

Chondrosarcoma is an uncommon neoplasm originated from cartilage cells. This occurs less than 10% in the head and neck region. Chondrosarcoma of the condyle affects mainly women. The most common symptom is swelling in the preauricular region, limited mouth opening and pain on chewing. This report describes a case of chondrosarcoma, which occurred in the mandibular condyle.

### Key words

Chondrosarcoma, Mandibular condyle

## INTRODUCTION

Chondrosarcoma is an uncommon neoplasm originated from cartilaginous cells. This is most commonly found in the long bone and pelvis, with less than 10% occurring in the head and neck and less than 5% of all tumors of the head and neck region<sup>1)</sup>. In the head and neck area, there is greater involvement of the maxillo-nasal region than of the mandible, because of the probable origin from the cartilage of the nose<sup>2)</sup>. Chondrosarcoma in the mandibular condyle is rare, with only 13 cases in the literature published in English (Medline 1966-2005).

This report describes a case of chondrosarcoma, which occurred in the mandibular condyle of a 29-year-old female.

## CASE REPORT

A 29-year-old female was referred to the Department of Oral and Maxillofacial Surgery because of a mouth opening limitation and left preauricular pain during mouth opening. The patient first noticed difficulty in mouth opening 10 years ago. There was no history of clicking or facial trauma. Her medical history was not specific.

Clinical examination revealed no deformity of the left preauricular area, which covered with normal skin. The range of maximal interincisal mouth opening was 20mm and the path of mouth opening showed deviation to left side. There was palpable pain of left preauricular area. There were no cervical lymphadenopathy.

Orthopantomographic examination showed a well-defined radiopaque lesion in the left mandibular condyle (Fig. 1). CT and MRI revealed a 1.5cm × 1.3cm × 1.1cm sized mass involving the left mandibular condylar head, which exhibited severe resorption, and showed no invasion of the cranial base (Fig. 2). Considering a benign condylar tumour such as osteochondroma or osteochondrosis, it was decided to do

\* Corresponding author

Je-Uk Park

Dept. of OMFS, Kang-nam St. Mary's Hospital

#505 Banpo-dong, Secho-gu, Seoul, 137-701, Korea

Tel: 82-2-590-1753

E-mail: jupark@catholic.ac.kr

condylectomy.

Surgery was performed under general anesthesia. Left condylectomy was performed via preauricular incision. The mass was found on the medioanterior part of the condyle and well demarcated from the surrounding tissue. However, the size was quite big (1.5 cm × 2 cm) and the color was whitish ivory and the texture was like wax with moderate hardness (Fig. 3). The mass was sent to the Department of Pathology for biopsy and confirmed as a well differentiated grade I chondrosarcoma (Fig. 4). There was characteristic permeation of tumor cells into bony trabeculae and binucleated cells. Tumor cells showed positive S-100 protein and vimentin (Fig. 5). The healing process was uneventful, and until yet the patient had no particular clinical sign and symptom. Immediate physical therapy was begun after surgery with no intermaxillary fixation. Postoperative 7 days, the maximal mouth opening was 27mm with slight deviation to the left side. The patient refused postoperative radiation therapy but was ordered to have a periodical postoperative checkup every 6 months.

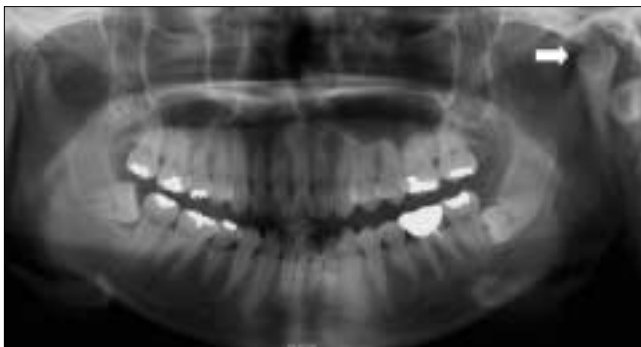## DISCUSSION

Limitation of mouth opening should be evaluated carefully. Acute, limited mouth opening is a common complaint of temporomandibular joint disorders such as anterior disc displacement, inflammatory processes, or infection<sup>3)</sup>. But, chronic limitation should be re-evaluated because it may be caused by space-occupying lesions such as synovial chondromatosis, benign and malignant tumors<sup>3)</sup>. Our patient had a 10-year history of limited

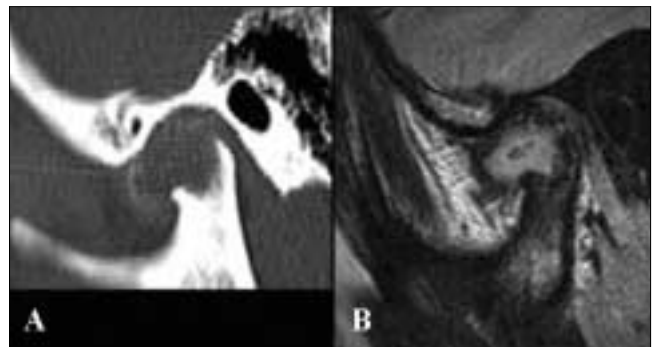
mouth opening and palpable preauricular pain with no history of clicking or facial trauma. Radiographic examination showed a well-defined radiopaque lesion in the mandibular condylar head and tentative diagnosis of osteochondroma or osteochondrosis was made. However, the final diagnosis was a chondrosarcoma. It can be speculated that a longstanding chondroma had transformed into chondrosarcoma<sup>4)</sup>.

Chondrosarcoma is an uncommon neoplasm originated from cartilaginous cells. This is most commonly found in the long bone and pelvis, with less than 10% occurring in the head and neck and less than 5% of all tumors of the head and neck region<sup>1)</sup>. Chondrosarcoma of the condyle affects mainly women (8:2) and affected age ranges from 17 to 75 years<sup>2)</sup>. The most common symptom is swelling in the preauricular region, limited mouth opening and pain on chewing<sup>2)</sup>. In 1960, Kragh et al<sup>5)</sup> reported the first series of chondrosarcoma of the jaw and facial bones and emphasized the need for radical surgical removal and long term follow-up evaluation.

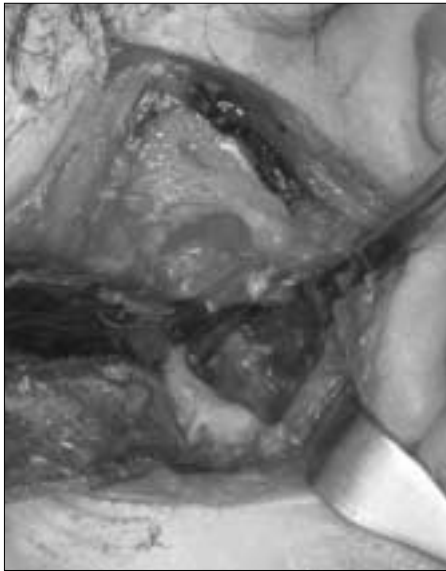Chondrosarcoma is classified as central (arising within the bone) and juxtacortical (arising on the surface of the bone) or primary (develop from normal bone) and secondary (develop in preexisting lesions)<sup>6)</sup>. However, histopathologic diagnosis is based on the grading system. Evans et al<sup>7)</sup> classified chondrosarcoma into three degrees based on the frequency of mitosis, cellularity and nuclear dimensions. Grade I chondrosarcomas show hypercellularity, enlarged chondrocytes, hyperchromatic nuclei, binucleation and nuclear pleomorphism. Some cases show myxoid matrix and focal areas of calcification. Myxoid degeneration is a feature that suggests



**Fig. 1.** Preoperative orthopantomogram showed a well-defined radiopaque mass (arrow) in the left mandibular condyle.



**Fig. 2.** CT (A) and MRI (B) revealed a mass in the left mandibular condylar head, which exhibited severe resorption.



**Fig. 3.** Intraoperative findings. The yellowish mass was shown in the mandibular condyle.



**Fig. 4.** Histopathologic examination. There is characteristic permeation of binucleated tumor cells into bony trabeculae.



**Fig. 5.** Immunohistochemical examination. Tumor cells show positive vimentin (A) and S-100 protein (B).

malignancy in cartilage tumors<sup>5</sup>). Characteristic binucleation was also observed in this case. Binucleation and nuclear pleomorphism is common in large sized (> 5cm) grade I chondrosarcoma. The degree of the myxoid change was higher in the larger tumors<sup>5</sup>). Grade II lesions of the jaw and facial bones are more cellular and showed greater nuclear pleomorphism and binucleation than grade I tumors<sup>5</sup>). Grade III chondrosarcomas showed more pronounced nuclear enlargement and multinucleation<sup>7</sup>). Histologic differentiation also influences the metastatic rate, which varies from 10% for grade II cases to 71% for those in grade III. Metastasis from grade I

chondrosarcoma has not been reported<sup>2</sup>).

On the CT and MRI, chondrosarcoma appears as a radiolucent mass that may contain calcifications and cause condylar deformity and sometimes erosion of the surrounding bony structures<sup>2</sup>). In most cases, an increase in the articular space, length of the condylar neck and radiopacity of the condyle can be seen<sup>2</sup>). Well-differentiated grade I chondrosarcoma shows well-defined margins and an expansile growth<sup>8</sup>). Radiological abnormalities of this lesion were the resorption of the mandibular condyle and expansile mass, which suggest the low-grade malignancy. In this case, preoperative biopsy

could not be performed because of deep location of the lesion. CT and MRI play an important role in diagnosis and surgical planning of deeply situated lesion like this.

Surgical excision is the treatment of choice for chondrosarcoma. Radiation therapy is ineffective if used alone, but together with surgery it improves the control of recurrence and increases the survival rate of the patients<sup>2)</sup>. The tumor may recur locally or metastasize to bone or lungs. Recurrence is independent of histologic grade<sup>2)</sup>. The prognosis for chondrosarcoma in the jaw and face is related to the size, location, histologic grade and completeness of resection<sup>3)</sup>.

In conclusion, this case of chondrosarcoma, which are not frequently reported, was successfully treated through surgical removal and condylectomy.

## REFERENCE

1. Gadwal SR, Fanburg-Smith JC, Gannon FH, Thompson LD: Primary chondrosarcoma of the head and neck in pediatric patients. *Cancer* 2000;88:2181-2188.
2. Sesenna E, Tullio A, Ferrari S: Chondrosarcoma of the temporomandibular joint : a case report and review of the literature. *J Oral Maxillofac Surg* 1997;55:1348-1352.
3. Nitzan DW, Marmary Y, Hasson O, Elidan J: Chondrosarcoma arising in the temporomandibular joint : A case report and literature review. *J Oral Maxillofac Surg* 1993;5: 312-315.
4. Resnick D: Tumor and tumor-like lesions of bone, in Resnick D, Nimagoma(eds): *Diagnosis of Bone and Joint Disorders*. Philadelphia, PA, Saunders, 1981, pp2654-2656.
5. Saito K, Unni KK, Wollan P, Lund BA: Chondrosarcoma of the jaw and facial bones. *Cancer* 1995;76:1550-1558.
6. Greenfield GB: *Radiology of bone disease*, 4th ed. Philadelphia: JB Lippincott, 1988.
7. Evans HL, Ayala AG, Romsdahl MM: Prognostic factors in chondrosarcoma of bone : A clinicopathologic analysis with emphasis on histologic grading. *Cancer* 1977;40:818-831.
8. Bernasconi G, Preda L, Padula E, Baciliero U, Sammarchi L, Bellomi M: Parosteal chondrosarcoma, a very rare condition of the mandibular condyle. *J Clin Imaging* 2004;28:64-68.