

## Clinical Article

# Microvascular Decompression for Hemifacial Spasm Associated with Vertebrobasilar Artery

Joo Pyung Kim, M.D., Bong Jin Park, M.D., Ph.D., Seok Keun Choi, M.D., Bong Arm Rhee, M.D., Young Jin Lim, M.D.

Department of Neurosurgery, Kyung Hee University Hospital, Seoul, Korea

**Objective :** Hemifacial spasm (HFS) is considered as a reversible pathophysiological condition mainly induced by continuous vascular compression of the facial nerve root exit zone (REZ) at the cerebellopontine angle. As an offending vessel, vertebrobasilar artery tends to compress much more heavily than others. The authors analyzed HFS caused by vertebrobasilar artery and described the relationships between microsurgical findings and clinical courses.

**Methods :** Out of 1,798 cases treated with microvascular decompression (MVD) from Jan. 1980 to Dec. 2004, the causative vessels were either vertebral artery or basilar artery in 87 patients. Seventy-nine patients were enrolled in this study. Preoperatively, computed tomography (CT) or brain magnetic resonance (MR) imaging with 3-dimensional short range MR technique was performed and CT was checked immediately or 2-3 days after anesthetic recovery. The authors retrospectively analyzed the clinical features, the compression patterns of the vessels at the time of surgery and treatment outcomes.

**Results :** There were 47 were male and 32 female patients. HFS developed on the left side in 52 cases and on the right side in 27. The mean age of onset was 52.3 years (range 19-60) and the mean duration of symptoms was 10.7 years. Many patients (39 cases; 49.1%) had past history of hypertension. HFS caused only by the vertebral artery was 8 cases although most of the other cases were caused by vertebral artery (VA) in combination with its branching arteries. Most frequently, the VA and the posterior inferior cerebellar artery (PICA) were the simultaneous causative blood vessels comprising 32 cases (40.5%), and in 27 cases (34.2%) the VA and the anterior inferior cerebellar artery (AICA) were the offenders. Facial symptoms disappeared in 61 cases (77.2%) immediately after the operation and 68 cases (86.1%) showed good outcome after 6 months. Surgical outcome just after the operation was poor in whom the perforators arose from the offending vessels concurrently ( $p < 0.05$ ).

**Conclusion :** In case where the vertebral artery is a cause of HFS, commonly branching arteries associated with main arterial compression on facial REZ requires more definite treatment for proper decompression because of its relatively poor results compared to the condition caused by other vascular compressive origins.

**KEY WORDS :** Hemifacial spasm · Vertebrobasilar artery.

## INTRODUCTION

For the pathophysiological mechanism of hemifacial spasm, Gardner et al.<sup>8)</sup> have reported that due to the chronic pulsatile compression of the facial nerve root exit zone (REZ), the denervation of nerve sheath occurs and thus the nerve action potential becomes lower. As a result, despite of small signals, hyperactivation can be induced and involuntary facial spasm may develop. Hemifacial spasm may also be induced by tumor<sup>1,17)</sup>, cerebral vascular aneurysm<sup>16,28)</sup>, arteriovenous malformation (AVM)<sup>5,24)</sup>, or bony deformity<sup>6)</sup>. Nevertheless, in most cases, the symptom is developed by

the vascular compression on the facial nerve REZ. Hence, microvascular decompression (MVD) has been accepted as a safe and definitive treatment method<sup>3,12,18)</sup>. The hypothesis of vascular compression as a cause of HFS is established by the disappearance of involuntary facial movement just after MVD<sup>22)</sup>. The common offending vessels are anterior inferior cerebellar artery (AICA) and posterior inferior cerebellar artery (PICA). But, in some cases main arteries such as vertebral artery and basilar artery can be the initiatives generating transmission of the pulse pressure to the nerve.

According to the previous reports, the success rate of MVD of the REZ utilizing Teflon is as high as 84-98.3%<sup>3,10,12)</sup>. The data from our hospital were obtained from a single surgeon's operations and recent results showed that the HFS caused by the small vessels had good prognosis in over 98% of the cases. Nonetheless, recurrence or lack of relief from the symptoms were occasionally encountered in cases

• Received : March 31, 2008 • Accepted : August 18, 2008  
• Address for reprints : Bong Jin Park, M.D., Ph.D.  
Department of Neurosurgery, Kyung Hee University Hospital, 1 Hoegi-dong, Dongdaemun-gu, Seoul 130-702, Korea  
Tel : +82-2-958-8408, Fax : +82-2-958-8380,  
E-mail : hyunsong@khmc.or.kr

of the larger vessels, vertebral or basilar arteries<sup>14)</sup> because the comprehension of the anatomical relationships of the vessels and defining the precise structure compressed could be troublesome<sup>20)</sup>. In this study, anatomical relationships of the related structures in operative field, treatment outcomes and clinical courses were analyzed retrospectively in patients who underwent MVD for HFS caused by large blood vessels such as the lengthened vertebral artery or the basilar artery.

## MATERIALS AND METHODS

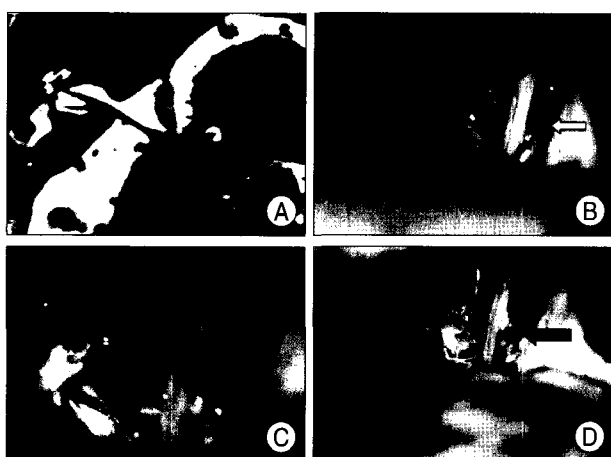
A total of 1,798 patients underwent MVD for HFS at our hospital during the period between January 1980 and December 2004. Of these, the causative blood vessels were either vertebral artery or basilar artery based on the surgical findings in 87 patients. Seventy-nine patients out of the 87 whose clinical follow-up evaluations were available were enrolled in this study. The authors retrospectively analyzed the clinical features, the compression pattern of the causative blood vessels at the time of surgery and treatment outcomes.

Prior to surgery, the anatomical relationship of the blood vessel and the venous plexus in the facial nerve REZ, the cerebellar hemisphere and the flocculus were assessed by brain computed tomography (CT), magnetic resonance imaging (MRI) or short-range three dimensional MRI technique. On simple skull X-ray, the sigmoid sinus groove was assessed within the basal skull area, and the mastoid air cells were identified to facilitate surgical approach. As for the improvement of clinical symptoms, the presence or absence of the amelioration of facial spasm immediately after the surgery was recorded according to the remaining

extent of spasm. Subsequent follow up observation was assessed by inspection of the patients and inquiries at the time of the outpatient visit. For the data analysis, SPSS 13.0 was used. Statistical analysis was performed using Chi-square test. Statistical significance was set at  $p$ -value<0.05.

## Surgical procedure

After general anesthesia, the patient was positioned laterally (park-bench position) with the head elevated 10 degrees, and the neck flexed slightly to facilitate the manipulation of microscope and equipments during surgery. To prevent compression of the jugular vein by the opposite jaw, gel pad was placed underneath the shoulder, thus smoothing the venous return from the brain. To secure the maximal surgical view, the ipsilateral shoulder was tracted caudally. A linear skin incision of 5-6 cm was made posterior 2 cm to the level of the mastoid tip. After dissection of the muscles in the occipital area, a key hole based on the transverse-sigmoid junction was made. From the hole, while verifying the sigmoid sinus, 25 × 15 mm sized craniectomy was performed, and if the mastoid air cells were exposed, they were packed with bone wax. Dura was incised linearly, 3-4 mm posterior to the sigmoid sinus and tag-up suture was carried out. The lateral cerebellom- edullary cistern was sunk using an arachnoid hook, and subsequently, the lateral pontomedullary membrane was resected sharply while assessing the 9th, 10th, and 11th cranial nerve complexes, and dissection was continued until the contact of the 9th cranial nerve with the pontomed- ullary junction could be visualized accurately. Approxima- tely 1-3 mm superior to this area, the facial nerve REZ was located, and the compression by the blood vessel was



**Fig. 1.** A 62-year-old man diagnosed with right hemifacial spasm. Constructive interference in steady state image of the root exit zone (REZ) shows related vascular and neural structure (A). It shows compressed 7th nerve REZ caused by vertebral artery (white arrow) only (B & C). But, another compressing vessel posterior inferior cerebellar artery (black arrow) under vertebral artery (D) is seen.

**Table 1.** Offending vessels

Offending vessels	No.(%)
VA	8 (10.1)
VA+AICA	27 (34.2)
VA+PICA	32 (40.5)
VA+AICA+PICA	8 (10.1)
VA+AICA+LA	2 (2.5)
BA+AICA	2 (2.5)
Total	79 (100)

VA : vertebral artery, AICA : anterior inferior cerebellar artery, PICA : posterior inferior cerebellar artery, LA : labyrinthine artery, BA : basilar artery

**Table 2.** Surgical outcome of hemifacial spasm due to vertebrobasilar artery (N=79)

Outcomes	Post op Immediately (%)	Post op 6 months (%)
Good	61 (77.2)	68 (86.1)
Fair	16 (20.3)	5 (6.3)
Poor	2 (2.5)	3 (3.8)
Failure	0 (0.0)	3 (3.8)

**Table 3.** The causes of poor outcome

Case	Offending vessels	Perforators	Outcome		Considered cause
			Immediate	6 months	
M/50, Rt.	VA+AICA	No	Good	Failure	Slippage of Teflon, re-op
F/33, Lt.	VA+AICA	No	Fair	Poor	Difficult to define REZ
M/60, Lt.	VA+AICA+PICA	Perforators from AICA	Good	Failure	Insufficient decompression
M/42, Lt.	VA+PICA	Perforators from VA	Fair	Poor	Insufficient decompression
F/67, Lt.	VA	Perforators from VA	Fair	Failure	Difficult to define REZ
F/56, Lt.	VA+PICA	No	Good	Poor	Difficult to define REZ

VA : vertebral artery, AICA : anterior inferior cerebella artery, PICA : posterior inferior cerebellar artery

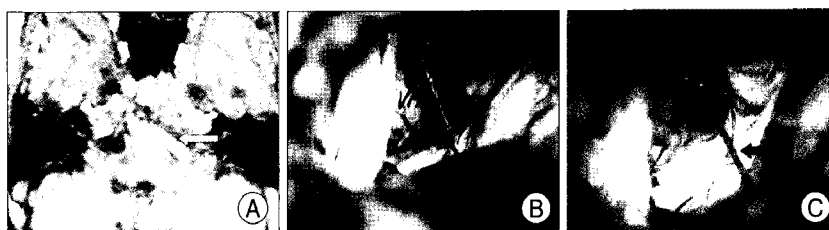examined carefully. When small perforating arteries are branching towards the brain stem or cerebellar peduncle directly, careful manipulation was essential because traction injuries might cause severe consequences. When vessels were accessible they were repositioned using Teflon. After the decompression of facial REZ, water-tight suturing of the dura was performed. In all cases, cranioplasty was done after surgery using hydroxyapatite bone cement.

## RESULTS

HFS caused by vertebrobasilar artery developed predominantly in the male (47 male : 32 female) and on the left side (52 cases : 65.8%). The mean age was 52 years (range : 19-60), and the mean duration of symptom before operation was 10.7 years (range : 2.7-15). Accompanied medical diseases were hypertension (n=39, 49.1%), diabetes mellitus (n=7, 8.5%) and cardiac disease (n=4, 5.1%).

The vertebral artery, basilar artery and the perforating arteries were the causative blood vessels in 71 cases (89.8%) consisting most of the cases, and those caused only by vertebral artery were 8 cases (10.1%). Most frequently, the VA and the PICA were the simultaneous causative blood vessels comprising 32 cases (40.5%) (Fig. 1), and in 27 cases (34.2%) the VA and the AICA were the offenders (Table 1).

Immediately after surgery, the complete relief of HFS was observed (good) in 61 cases (77.2%). When assessed at follow up inspections 6 months after surgery, good outcome was shown in 68 cases (86.1%). In addition, significant reduction of HFS was detected in 16 cases (20.3%) of patients immediately after surgery but in 5 cases (6.3%), at 6 months after surgery. As for the failure of improvement of HFS at the time immediately after surgery, symptoms improved to certain extent in all patients as time passed but when inspected 6 months after surgery at the outpatient clinic, spasm recurred in 3 patients (Table 2). The causes of



**Fig. 2.** Recurred case in a 66-year-old male. Short range 3D magnetic resonance angiography image shows that vertebral artery compresses the 7th nerve root exit zone (white arrow)(A). Operation view showing simultaneous compression VA with posterior inferior cerebellar artery, anterior inferior cerebellar artery (B). It could not be decompressed enough due to the presence of small perforator (black arrow)(C).

**Table 4.** Immediate surgical outcome of hemifacial spasm due to the existence of perforator

Perforator	Symptom relief		Total
	Good	Fair, Poor	
No	51	11	62
Yes	10	7	17
Total	61	18	79

*p*-value<0.05

unsatisfactory outcome were summarized in Table 3. In two cases, there were perforators which were not decompressed abundantly. One patient who showed good outcome immediately became worse during follow-up period. Surgical findings during reoperation of the patient revealed slippage of Teflon.

We compared surgical outcomes of patients who had perforators from offending vessels with those who had not. When small perforators were present under the offending vessels, the surgical outcome was poor (Table 4) (Figure 2) (*p*<0.05).

As for the complications after surgery, facial palsy occurred immediately after surgery in 2 cases (2.5%) which lasted temporarily and delayed facial palsy, hearing disturbance, and superficial wound infection occurred in 1 case each (1.3%).

## DISCUSSION

As the therapy for HFS, MVD has been known to be an effective method. For the decompression to be successful, the aim of this surgery requires focusing on preventing the transmission of the pulsatile signals regardless of their

patterns. It is thought that no matter how large or small the blood vessels are, the treatment outcome depends on how effectively the pulsatile signal is blocked during surgery.

As an offending vessel, main arteries such as vertebral artery or basilar artery can compress the facial REZ with or without their branching vessels, AICA or PICA. It has been reported that HFS from vertebrobasilar artery develops primarily in the elderly and occurs predominantly in male and on the left side<sup>11</sup>. Frazier et al.<sup>7</sup> have reported that arteriosclerotic changes are prone to develop in vertebrobasilar artery of the posterior circulation in patients with accompanied hypertension, diabetes, hyperlipidemia or obesity. And, the change of the artery is also developed as a compensation to the hypoperfusion when the brain stem itself developed ischemic changes. In our study, similarly, HFS was developed mostly in male, and was seen on the left side in 52 cases out of 79 cases. In our study, many patients had hypertension (49.1%), diabetes mellitus (8.5%), and cardiac disease. It is thought that in majority, the blood supply usually comes from the left vertebral artery and the consequent hemodynamic changes give rise to the prevalence of the occurrence on the left side<sup>12</sup>. In addition, it is considered that sufficient management and drug therapy should be preceded prior to surgical treatments because the patients to undergo surgery should be selected with caution regarding the age and their medical problems.

Kondo<sup>13</sup> explained the vertebrobasilar system by dividing it into two types. The first one was that the tortuous vertebral artery of the affected side was larger than that of the contralateral side and the length of one of branching blood vessels of the affected side, the PICA, became longer, and thus the possibility of inducing the lesion was high. The second was that based on the central axis of the S shaped basilar artery, it is deviated to the affected side, and therefore, it accompanies the lengthening of the AICA toward the internal auditory meatus. In our patients, either vertebral artery or basilar artery was found as the causative blood vessel in 8 cases (10.2%) and in most others, (89.8%) branching vessels, AICA, PICA or other arteries compressed the facial REZ simultaneously.

When compressed by main blood vessels, the REZ of the facial nerve root receives relatively higher pressure, and despite the same extent of MVD, the possibility that the pulsatile signal may still be remaining would be high. Therefore, many authors suggested various modified methods other than conventional MVD<sup>4,14,15,19,26,27</sup>. Nevertheless, the outcome of facial spasm caused by the larger arteries is not satisfactory. In our institute, Teflon was used for decompression in majority of cases. Also, vascular transposition, wrapping the artery, and surgical glue was placed

for reposition. However, immediately after surgery, we did not achieve good outcomes compared to other surgical results of MVD for HFS<sup>3,10,12</sup>.

Neuronal hyperexcitability mechanism for HFS is explained as when the facial nerve nucleus receives small stimulus for longer than several weeks, the kindling phenomenon is induced in the facial motor nucleus, and repeated reflex increases in response to the same stimulation, and thus spasm appears<sup>13</sup>. The local denervation of the facial nerve REZ is achieved by the microvascular compression, and the consequent hyperactivation is caused by the anatomical characteristic of the facial REZ that is transformed from the thin central myelin to the thick peripheral myelin<sup>2,18,21,23</sup>. Therefore, facial symptoms intend to disappear immediately after MVD because the causative factor was removed from demyelinated fibers. However for our patients, unusual pattern of the improvement of symptom was observed, in which the outcome was better at follow-up sixth months from the surgery in comparison with the time just after surgery or at discharge. Hatem et al. suggested that delayed cure strongly supports the hypothesis that HFS is not only due to the mechanical pulsations of the elongated artery against the root exit zone of the facial nerve, but also to demyelination of the nerve and/or hyperactivity of the facial motor nucleus generated by the neurovascular compression<sup>9</sup>. Therefore, it could be suggested that, nerve regeneration occurs gradually when compression was relieved.

Surgeons have difficulties in searching for the precise REZ and vascular relationships because of their size of the main artery. When performing MVD for HFS, the successful surgical outcome depends on precise understanding of the anatomical structure more than anything else. Nagatani et al.<sup>26</sup> suggested that the configuration of the vertebrobasilar system has a significant correlation with the presence of perforating branches near the site of microvascular decompression. Our result showed the significant difference in the treatment outcome according to the presence or absence of direct perforators towards the brain stem or cerebellar peduncle. Such anatomical characteristics may become an impeding factor during the decompression of the blood vessel in the facial nerve REZ. In other words, insufficient decompression could take place if the perforating branches are present directly in the vicinity of the facial nerve REZ because excessive insertion of Teflon may result in traction of the small vessels which may lead to the lack of blood supply to the brain stem.

Failure to identify the causative blood vessel in the nerve REZ have been reported when shifting of location of the causative blood vessel occurs while positioning the patient

on the surgical bed, when facial nerve REZ was not examined comprehensively, when several blood vessels may be causatives, when movement of the blood vessel due to the traction of the cerebellum takes place or when the operator has poor understanding of the relationship between the location of the causative blood vessel with the facial nerve REZ<sup>2,18,21,23</sup>).

Regarding the causes of the failed or poor outcome cases during follow-up period, most of them were anatomical difficulty for the sufficient decompression of the direct perforators or troublesome in defining the REZ due to the complexity of the vasculature. And, the one recurred case turned out to be due to slippage of Teflon from the previously inserted site when observed during the subsequent reoperation. These results explain that during surgery for HFS, it is necessary to understand the accurate anatomical characteristics of the blood vessels and the precise decompression of the vessels hidden underneath the larger arteries is essential.

## CONCLUSION

The treatment outcome of the MVD for HFS associated with vertebrobasilar artery is poor in comparison with other vascular compressive origins. It is thought to be because of the insufficient decompression in presence of the perforating arterial branches and due to relatively forceful pulsatile stimulation.

## References

- Auger RG, Piepgras DG : Hemifacial spasm associated with epidermoid tumors of the cerebellopontine angle. *Neurology* 39 : 577-580, 1989
- Barker FG 2nd, Jannetta PJ, Bissonette DJ, Larkins MV, Jho HD : The long-term outcome of microvascular decompression for trigeminal neuralgia. *N Engl J Med* 334 : 1077-1083, 1996
- Barker FG 2nd, Jannetta PJ, Bissonette DJ, Shields PT, Larkins MV, Jho HD : Microvascular decompression for hemifacial spasm. *J Neurosurg* 82 : 201-210, 1995
- Bejjani GK, Sekhar LN : Repositioning of the vertebral artery as treatment for neurovascular compression syndromes. Technical note. *J Neurosurg* 86 : 728-732, 1997
- Deshmukh VR, Maughan PH, Spetzler RF : Resolution of hemifacial spasm after surgical obliteration of a tentorial arteriovenous fistula : case report. *Neurosurgery* 58 : E202; discussion E202, 2006
- Fernandez JM, Mederer S, Alvarez-Sabin J, Segura A, Codina A : Hemifacial spasm associated with Paget's disease of bone : good response to calcitonin. *Neurology* 41 : 1322-1323, 1991
- Frazier CH, Lewy FH, Rowe SN : Origin and mechanism of paroxysmal neuralgic pain and surgical treatment of central pain. *Brain* 60 : 44-51, 1937
- Gardner WJ, Miklos MV : Response of trigeminal neuralgia to decompression of sensory root; discussion of cause of trigeminal neuralgia. *J Am Med Assoc* 170 : 1773-1776, 1959
- Hatem J, Sindou M, Vial C : Intraoperative monitoring of facial EMG responses during microvascular decompression for hemifacial spasm. Prognostic value for long-term outcome : a study in a 33-patient series. *Br J Neurosurg* 15 : 496-499, 2001
- Huh R, Han IB, Moon JY, Chang JW, Chung SS : Microvascular decompression for hemifacial spasm : analyses of operative complications in 1582 consecutive patients. *Surg Neurol* 69 : 153-157; discussion 157, 2008
- Jannetta PJ : Neurovascular compression in cranial nerve and systemic disease. *Ann Surg* 192 : 518-525, 1980
- Kondo A : Follow-up results of microvascular decompression in trigeminal neuralgia and hemifacial spasm. *Neurosurgery* 40 : 46-51; discussion 51-52, 1997
- Kondo A : Microvascular decompression surgery for trigeminal neuralgia. *Stereotact Funct Neurosurg* 77 : 187-189, 2001
- Kurokawa Y, Maeda Y, Toyooka T, Inaba K : Microvascular decompression for hemifacial spasm caused by the vertebral artery : a simple and effective transposition method using surgical glue. *Surg Neurol* 61 : 398-403, 2004
- Kyoshima K, Watanabe A, Toba Y, Nitta J, Muraoka S, Kobayashi S : Anchoring method for hemifacial spasm associated with vertebral artery : technical note. *Neurosurgery* 45 : 1487-1491, 1999
- Matsumoto K, Saijo T, Kuyama H, Asari S, Nishimoto A : Hemifacial spasm caused by a spontaneous dissecting aneurysm of the vertebral artery. Case report. *J Neurosurg* 74 : 650-652, 1991
- Matsumoto K, Sakurai M, Asari S, Nishimoto A : Hemifacial spasm due to cerebellopontine angle epidermoid tumor-case report. *Neurol Med Chir (Tokyo)* 31 : 410-413, 1991
- McLaughlin MR, Jannetta PJ, Clyde BL, Subach BR, Comey CH, Resnick DK : Microvascular decompression of cranial nerves : lessons learned after 4400 operations. *J Neurosurg* 90 : 1-8, 1999
- Miyazono M, Inoue T, Matsushima T : [A surgical case of hemifacial spasm caused by a tortuous, enlarged, and calcified vertebral artery]. *No Shinkei Geka* 31 : 437-441, 2003
- Moller AR : Is there a place for microvascular decompression? *Acta Neurochir (Wien)* 147 : 921-923, 2005
- Moller AR : Vascular compression of cranial nerves : II : pathophysiology. *Neurol Res* 21 : 439-443, 1999
- Moller AR, Jannetta PJ : Microvascular decompression in hemifacial spasm : intraoperative electrophysiological observations. *Neurosurgery* 16 : 612-618, 1985
- Moller AR, Jannetta PJ : On the origin of synkinesis in hemifacial spasm : results of intracranial recordings. *J Neurosurg* 61 : 569-576, 1984
- Nagata S, Matsushima T, Fujii K, Fukui M, Kuromatsu C : Hemifacial spasm due to tumor, aneurysm, or arteriovenous malformation. *Surg Neurol* 38 : 204-209, 1992
- Nagatani T, Inao S, Suzuki Y, Yoshida J : Perforating branches from offending arteries in hemifacial spasm : anatomical correlation with vertebrobasilar configuration. *J Neurol Neurosurg Psychiatry* 67 : 73-77, 1999
- Shigeno T, Kumai J, Endo M, Oya S, Hotta S : Snare technique of vascular transposition for microvascular decompression--technical note. *Neurol Med Chir (Tokyo)* 42 : 184-189; discussion 190, 2002
- Suzuki S, Tsuchita H, Kurokawa Y, Kitami K, Sohma T, Takeda T : New method of MVD using a vascular tape for neurovascular compression involving the vertebrobasilar artery--report of two cases. *Neurol Med Chir (Tokyo)* 30 : 1020-1023, 1990
- Tsuchiya D, Kayama T, Saito S, Sato S : [Hemifacial spasm due to a compression of the facial nerve by a fusiform aneurysm of the vertebral artery : case report]. *No To Shinkei* 52 : 517-521, 2000