

## Case Report

# Contralateral Cerebral Infarction after Stent Placement in Carotid Artery : An Unexpected Complication

Seong-Ho Park, M.D., Chang Young Lee, M.D.

Department of Neurosurgery, Brain Research Institute, Keimyung University School of Medicine, Daegu, Korea

Stenting is a useful alternative treatment modality in carotid artery stenosis patients who are too high-risk to undergo carotid endarterectomy (CEA). We report a case of contralateral cerebral infarction after stenting for extracranial carotid stenosis. A 78-year-old woman was admitted to the hospital with left-sided weakness. Based on magnetic resonance imaging (MRI) of the brain and conventional angiography, she was diagnosed with an acute watershed infarct of the right hemisphere secondary to severe carotid stenosis. Stenting was performed for treatment of the right carotid artery stenosis after a one-week cerebral angiogram was completed. Thirty minutes after stent placement, the patient exhibited a generalized seizure. Four hours later, brain MRI revealed left hemispheric cerebral infarction. Complex aorta-like arch elongation, tortuosity, calcification, and acute angulation at the origin of the supra-aortic arteries may increase the risk of procedural complications. In our case, we suggest that difficult carotid artery catheterization, with aggressive maneuvering during stenting, likely injured the tortuous, atherosclerotic aortic arch, and led to infarction of the contralateral cerebral hemisphere by thromboemboli formed on the wall of the atherosclerotic aorta.

**KEY WORDS :** Carotid stenosis · Stenting · Complication.

## INTRODUCTION

Carotid artery stenosis is a major cause of recurrent ischemic strokes and transient ischemic attacks. Carotid artery stenting (CAS) has been widely used as a treatment<sup>14)</sup> for these patients, particularly for those in whom carotid endarterectomy (CEA) would present a high risk<sup>8)</sup>. CAS-associated complications include cerebral infarction, embolic stroke, intracranial hemorrhage caused by reperfusion injury, acute bradycardia and hypotension from carotid bulb compression, and contrast-induced renal failure<sup>12)</sup>. We present an unexpected complication : contralateral cerebral infarction due to emboli after carotid stenting.

## CASE REPORT

A 78-year-old woman presented with left hemiparesis (Grade III) beginning one week prior to admission. She had a history of hypertension and had been treated with

medication for one year. She had no history of diabetes mellitus, hyperlipidemia, or cardiovascular disease. She denied a history of palpitations, arrhythmia, or syncope. There were no abnormalities on electrocardiogram. Diffusion-weighted magnetic resonance image (MRI) showed an acute watershed infarct in the right hemisphere (Fig. 1A). During conventional angiography performed by the transfemoral route, we experienced considerable difficulty in selecting the origin of the right brachiocephalic trunk and left common carotid artery with the diagnostic catheter.

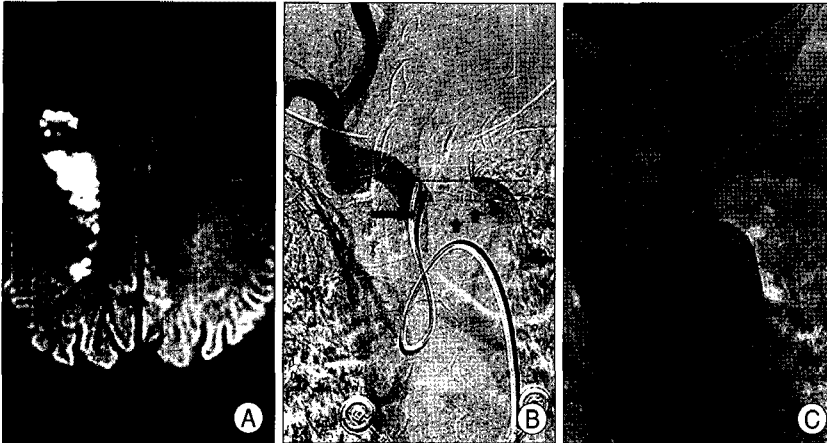
The right brachiocephalic trunk arose below the top of the aortic arch with sharp angulation, and both common carotid arteries showed tortuous courses. Multiple calcifications were noted along the wall of the aortic arch (Fig. 1B, C). The difficulty of angiography was attributed to these anatomical findings. Cerebral angiography revealed severe stenosis of the right extracranial internal carotid artery (ICA), measuring approximately 90% according to North American Symptomatic Carotid Endarterectomy Trial criteria (Fig. 2A). There was no significant stenosis in the left intracranial arteries, although mild stenosis is noted in the extracranial ICA (Fig. 2B, C). We planned CAS for right symptomatic ICA stenosis because the lesion was in a high position, and the patient's age (over 70 years old) was in a

• Received : April 29, 2008 • Accepted : August 10, 2008  
• Address for reprints : Chang Young Lee, M.D.  
Department of Neurosurgery, Keimyung University School of Medicine,  
194 Dongsan-dong, Jung-gu, Daegu 700-712, Korea  
Tel : +82-53-250-7730, Fax : +82-53-250-7356  
E-mail : nslcy@dsmc.or.kr

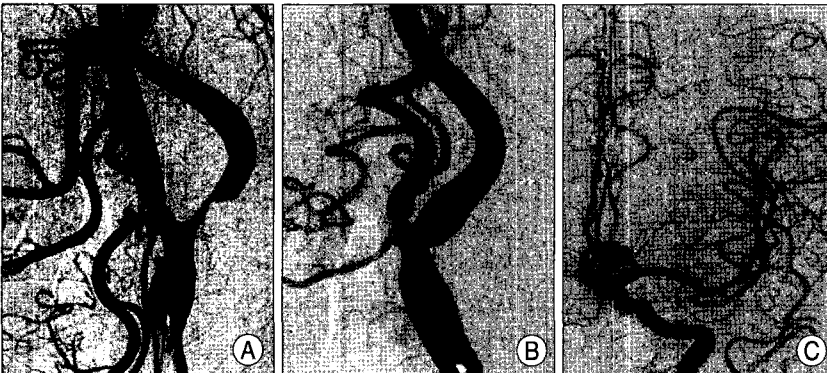
high risk category to undergo CEA.

The patient had aspirin (300 mg/d) and clopidogrel (75 mg/d) for 1 week before stenting. CAS was performed using the trans-femoral approach (TFA) under local anesthesia. Although catheterization of the right common

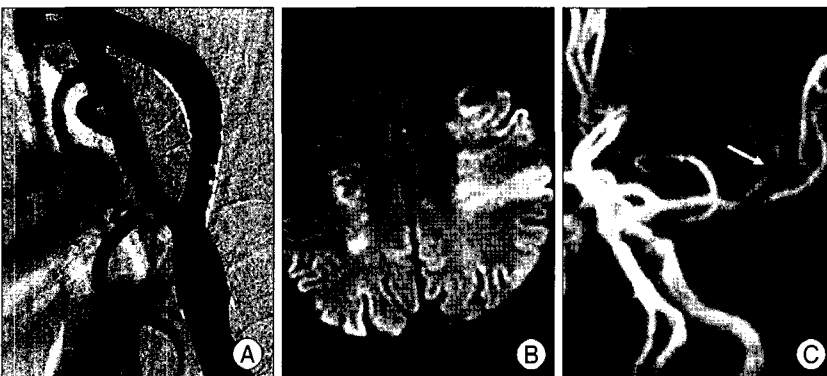
carotid artery using the TFA was predicted to be difficult due to the unfavorable anatomy, it was not considered to being impossible. Systemic anticoagulation was induced using intravenous heparin to maintain the activated clotting time in the range of 250-300s throughout the



**Fig. 1.** A : Diffusion-weighted magnetic resonance image showing acute watershed infarction in the right hemisphere. B, C : Right brachiocephalic arteriogram (B) and non-subtracted image of catheterization in the left common carotid artery (C) showing the right brachiocephalic trunk (long arrow) arising below the top of the aortic arch (dotted line) with sharp angulation, bilateral tortuous common carotid arteries (by look of simmons catheters), and multiple calcifications (short arrow) along the wall of the aortic arch.



**Fig. 2.** A : Right common carotid arteriogram showing severe stenosis of the internal carotid artery. B, C : Left extracranial (B) and intracranial (C) carotid arteriograms showing no significant stenosis in the extracranial or intracranial portions of the vessel.



**Fig. 3.** A : Right common carotid arteriogram after stenting shows no residual stenosis. B, C : Diffusion-weighted magnetic resonance image (B) and magnetic resonance angiogram (C) show new acute infarction in the frontal branch territory and occlusion of the frontal branch (arrow) of the left middle cerebral artery.

procedure. Given the aforementioned unfavorable anatomy of the aortic arch, origin of the right brachiocephalic trunk, and common carotid artery for catheterization, a 5F diagnostic catheter (Simmons/Side-winder 2; Terumo, Raidocus) with a 0.035-inch Terumo wire was used to select the origin of the right brachiocephalic trunk. The guide wire was exchanged for a stiff wire (0.038-inch extra-support Amplatz wire) and then the catheter was removed. An 8F guiding catheter (Brite tip; Cordis Endovascular Systems, Miami, FL, USA) loaded a 5F long catheter (125 cm) were coaxially advanced over the wire. Although the guiding catheter was successfully placed in the right common carotid artery, significant friction was felt during advancement of the catheter along the aortic arch and origin of the brachiocephalic trunk. Stenting was performed successfully with a 7 × 30 mm self-expandable stent, resulting in no residual stenosis (Fig. 3A). There was no bradycardia or hypotension during the procedure. After successful stent placement, the lesion was observed for approximately 30 minutes to check for occurrence of acute thrombosis. There was no evidence of thrombosis on the stent, dissection around the lesion, vasospasm, or occlusion of the intracranial arteries. The contralateral carotid artery was not manipulated with any equipment during the procedure.

The patient was transferred to the intensive care unit for monitoring of neurological status and blood pressure after removal of the guiding catheter. About 30 minutes later, the patient exhibited a generalized seizure. Emer-

gent brain computed tomography revealed no new lesions, ruling out the possibility of hemorrhage caused by reperfusion injury. The seizure was therefore thought to be due to ipsilateral small embolic infarction or contrast toxicity. The patient was treated with valium, an anticonvulsant agent, systemic heparinization, and fluid hydration. However, the patient did not recover even after several hours had passed, compelling us to obtain an MRI. Four hours after the seizure, diffusion-weighted MRI and MR angiogram (MRA) demonstrated partial occlusion of the frontal branch of left middle cerebral artery (MCA) and acute infarction in that vascular territory, presumed to be due to a thromboembolic source (Fig. 3B, C). Further invasive rescue procedures were not performed because infarction had already developed in the whole territory supplied by the occluded vessel. The patient remained in a nearly vegetative state.

## DISCUSSION

Candidates for CAS are those patients considered too high risk to undergo CEA<sup>14</sup>. CAS averts the need for general anesthesia and surgical incisions, and the risk-benefit ratio may be greatest in patients with high risk factors in CEA, including advanced age. Complications associated with CAS include cerebral infarction secondary to procedure-induced thromboembolism, dissection, vasospasm, acute bradycardia and hypotension from carotid bulb compression, and hemorrhage caused by reperfusion injury. Recent advances in CAS include improved sheaths and guides, lower profile balloons and stents, and development of dependable distal embolization protection devices<sup>10</sup>. Distal embolization protection devices help prevent thromboembolic infarction in the vascular territory of the treated carotid artery, but not in the contralateral side<sup>11</sup>.

There have been a number of reports<sup>2,4,6</sup> on development of silent, small embolic infarctions in the contralateral and posterior circulation, as well as in the ipsilateral circulation, identified on follow-up diffusion-weighted MRI after carotid stenting. These findings suggest that the most likely sources of embolic material are catheters and guide wires that dislodge atheromatous material from the aorta. However, it is difficult to determine the exact source of emboli in the reported cases, because all of the patients had stent placement in conjunction with four-vessel cerebral angiography. The occurrence of contralateral infarction in these papers drew little clinical attention because of the uncertainty of the embolic source, silent symptoms, and focus on the development of ipsilateral infarction.

According to Büsing et al.<sup>1</sup>, asymptomatic cerebral

infarction detected by diffusion-weighted MRI following cardiac catheterization occurs in 15-22% of patients. The rate of symptomatic cerebral infarction due to emboli after percutaneous cardiac intervention is reported to be 0.1-0.4%. Embolism is thought to be the result of dislodgment of atheromatous material as the catheter is aggressively maneuvered across areas of complex and severe atherosclerosis within the aorta<sup>5</sup>. Based on this projected mechanism, the presence of calcification, diffuse disease at the origin of supra-aortic vessels, and aortic arch tortuosity may lead to technical difficulties during catheterization for endovascular procedures and may increase the risk of neurological complications<sup>3</sup>.

In our patient, symptomatic thromboembolic infarction developed on the side contralateral to the CAS procedure. This side was not touched during whole procedure. The patient had great vessel anatomy that was unfavorable for catheterization. We used the coaxial catheter-in-catheter method for guiding catheter placement. This might have led to scraping of the guiding catheter edge along an atherosclerotic section of the aorta, because the 5F diagnostic catheter does not allow the same smooth transition into the 8F guiding catheter. Given the fact that the patient had no history of heart disease like arrhythmia, no peri-procedural bradycardia or hypotension, and no significant stenosis in the contralateral arteries, thromboembolism originating from the atherosclerotic aortic arch injured by the guiding catheter was thought to be the source of infarction. Although the presence of minimal stenosis was in the left extracranial ICA, it is hard to be considered as embolic source, given the severity (much mild) and shape (no irregularity and ulceration) of the stenosis.

After experiencing our case, we have deliberated methods for predicting and protecting from these complications. According to one study, transesophageal echocardiographic (TEE) imaging of the aorta may help identify patients at high risk of embolization by detecting atherosclerosis within the aorta<sup>7</sup>. We think that pre-procedural aortogram and TEE imaging will be helpful in anticipating complications. In cases expecting extensive maneuvering of lesions due to complexity of the aortic arch, such as type II (when the brachiocephalic vessels arise from the aortic arch between the outer and inner convexities of the aortic arch) or type III aortic arch (when the origin of the innominate artery is caudal to the inner curve of the aortic arch), brachiocephalic trunk, or carotid artery itself, or existence of atheromatous material within the aorta, brachial artery approach (BAA) or direct carotid access may be a useful alternative access to TFA<sup>7, 9,13</sup>. Our patient had type II aortic arch.

If contralateral stroke had been realized as one of the procedure-related complications in CAS, we could have saved our patient from a serious technical complication with devastating clinical consequences by taking prompt measures such as endovascular recanalization.

As in this case, endovascular neurosurgeons should be alert to the possibility of the development of symptomatic, contralateral embolic infarction related to CAS, even in patient in without any manipulation of the contralateral carotid artery during the procedure.

## CONCLUSION

By presenting the case of contralateral cerebral infarction related to CAS, we alert endovascular neurosurgeons to this unexpected event. We think that TEE and BAA or direct carotid access if possible, may be helpful in avoiding such potentially devastating complication.

## References

1. Büsing KA, Schulte-Sasse C, Flüchter S, Süselbeck T, Haase KK, Neff W, et al : Cerebral infarction : incidence and risk factors after diagnostic and interventional cardiac catheterization--prospective evaluation at diffusion-weighted MR imaging. *Radiology* 235 : 177-183, 2005
2. Chong J, Lu D, Aragao F, Singer MB, Schonewille WJ, Silvers A, et al : Diffusion-weighted MR of acute cerebral infarction: comparison of data processing methods. *AJNR Am J Neuroradiol* 19 : 1733-1739, 1998
3. Faggioli GL, Ferri M, Freyrie A, Gargiulo M, Fratesi F, Rossi C, et al : Aortic arch anomalies are associated with increased risk of neurological events in carotid stent procedures. *Eur J Vasc Endovasc Surg* 33 : 436-441, 2007
4. Flach HZ, Ouhlous M, Hendriks JM, Van Sambeek MR, Veenland JF, Koudstaal PJ, et al : Cerebral ischemia after carotid intervention. *J Endovasc Ther* 11 : 251-257, 2004
5. Hamon M, Burzotta F, Oppenheim C, Morello R, Viader F, Hamon M: Silent cerebral infarct after cardiac catheterization as detected by diffusion weighted Magnetic Resonance Imaging : a randomized comparison of radial and femoral arterial approaches. *Trials* 8 : 15, 2007
6. Jaeger HJ, Mathias KD, Hauth E, Drescher R, Gissler HM, Hennigs S, et al : Cerebral ischemia detected with diffusion-weighted MR imaging after stent implantation in the carotid artery. *AJNR Am J Neuroradiol* 23 : 200-207, 2002
7. Karalis DG, Quinn V, Victor MF, Ross JJ, Polansky M, Spratt KA, et al : Risk of catheter-related emboli in patients with atherosclerotic debris in the thoracic aorta. *Am Heart J* 131 : 1149-1155, 1996
8. Lee CY, Oh CW, Chung YS, Kwon OK, Han DH : Carotid endarterectomy for carotid stenosis : experience of 19 cases. *J Korean Neurosurg Soc* 30 : 284-294, 2001
9. Moran CJ, Cross DT 3rd, Derdeyn CP : Techniques of carotid angioplasty and stenting. *Neuroimaging Clin N Am* 17 : 337-353, 2007
10. Ouriel K : Carotid stent trials : past, present, and future. *Perspect Vasc Surg Endovasc Ther* 18 : 300-303, 2006
11. Saratzis N, Saratzis A, Melas N, Lioupis A, Lykopoulos D, Ginis G, et al : Carotid artery stent placement with embolic protection : single-center experience. *J Vasc Interv Radiol* 18 : 337-342, 2007
12. Sherrick JC, Amador LV : Cerebral infarction after carotid angiography. Anatomical changes in the brain. *Arch Pathol* 76 : 133-139, 1963
13. Sievert H, Ensslen R, Fach A, Merle H, Rubel C, Spies H, et al : Brachial artery approach for transluminal angioplasty of the internal carotid artery. *Cathet Cardiovasc Diagn* 39 : 421-423, 1996
14. Taylor RA, Qureshi AI : 10 most commonly asked questions about carotid artery stent placement. *Neurologist* 13 : 318-322, 2007