



Hepatoprotective Effects of Polysaccharides Isolated from *Phellinus gilvus* Against Carbon Tetrachloride-induced Liver Injury in Rats

Seung-Chun Park¹, Yong-Pil Cheon², Wha-Young Son³, Man-Hee Rhee¹,
Tae-Wan Kim¹, Jae-Chan Song¹ and Kil-Soo Kim¹

¹College of Veterinary Medicine, Kyungpook National University, Daegu 702-701,

²College of Natural Sciences, Sungshin Women's University, Seoul 136-742,

³College of Veterinary Medicine, Chungnam National University, Daejeon 305-361, Korea

(Received February 11, 2009; Revised February 24, 2009; Accepted February 26, 2009)

Phellinus gilvus (PG) is a widely used mushroom for health promotion. We studied the hepatoprotective effect of the polysaccharide aqueous extract of PG (PGP) against carbon tetrachloride (CCl₄)-induced liver injury in rats. Sprague Dawley rats were divided into 5 groups: Normal control, CCl₄ control, PGP 50, 100, and 200 mg/kg + CCl₄. The levels of serum biochemical parameters, liver lipid peroxide and antioxidant enzymes, and histological appearances were evaluated. The CCl₄-induced increments of alanine aminotransferase, aspartate aminotransferase, and alkaline phosphatase levels in serum were significantly decreased by PGP-pretreatments. The PGP dose-dependently decreased hepatic malondialdehyde formations in CCl₄-treatment groups. Hepatic antioxidant enzymes (superoxide dismutase, catalase, and glutathione peroxidase) were elevated by PGP in CCl₄-treatment groups. Histopathological evaluation of liver showed that the loss of hepatocytes, fatty changes, swelling and extensive necrosis of hepatocytes in centrilobular regions of the CCl₄-treated rats were ameliorated by PGP pretreatment. The PGP has hepatoprotective and antioxidative effects in CCl₄-induced liver injury of rat.

Key words: *Phellinus gilvus* polysaccharide, Carbon tetrachloride, Hepatoprotective effect

INTRODUCTION

Mushrooms have been valued as an important edible and medical resource. A number of bioactive materials have been identified in many mushroom species. Hot water soluble fractions of mushrooms, such as polysaccharides, were mainly used as traditional medicinal materials in East Asia, where the practical usage of mushrooms primarily originated (Wasser, 2002).

Phellinus gilvus (PG), *Phellinus linteus* (PL), and *Phellinus baumi* (PB) are mushrooms belonging to the Hymenochaetaceae basidiomycetes (Dai and Xu, 1998). PL and PB are well known as sources of antitumor or immunopotentiating polysaccharides, and they have been used as folk medicines for a variety of human diseases in several Asian countries for a long time. Some researchers reported that PL possess effects of antitu-

mor (Lee *et al.*, 2005), hepatoprotective (Kim *et al.*, 2004), antibacterial (Hur *et al.*, 2004), and antiangiogenic and antioxidant activity (Song *et al.*, 2003). PG or PB could inhibit the increase of neutrophils and the IL-1 β level of bronchial lavage fluid in lipopolysaccharide-challenged rats, and might be useful in preventing acute pulmonary inflammation in human diseases (Jang *et al.*, 2004). It was also reported that PG had significant reducing effects of adhesion and abscess in a rat peritonitis model, and dermal wound healing effects (Bae *et al.*, 2005a, b). In addition, the capability of PB as an antioxidant, free radical scavenger (Shon *et al.*, 2003) and antidiabetes (Hwang *et al.*, 2005) has recently been reported. Among *Phellinus spp.*, PG has a very short growth period (3 months) compared with PL and PB. Though fruiting bodies of PG have been widely used as health promoting food, no scientific data is available about the protective effects of the polysaccharide aqueous extract of PG (PGP) against liver injury.

The liver is the most important organ concerned with the biochemical activities and has a great capacity to detoxicate harmful substances. There is a growing

Correspondence to: Kil-Soo Kim, Department of Veterinary Toxicology, College of Veterinary Medicine, Kyungpook National University, 1370 Sangyeok-dong, Buk-gu, Daegu 702-701, Korea
E-mail: kskim728@knu.ac.kr

focus to evaluate the scientific basis for the traditional herbal medicines which are claimed to possess hepatoprotective activity.

Carbon tetrachloride (CCl₄) is a xenobiotic which produces hepatotoxicity in humans as well as in animals (Brattin *et al.*, 1985). CCl₄ is widely used in animal models to induce acute liver injury. Trichloromethyl radical, which is formed in the metabolism of CCl₄ via the liver microsomal cytochrome P450 system, reacts rapidly with molecular oxygen to produce the trichloromethylperoxy radical. These radicals react with unsaturated fatty acids of phospholipids in the cell membrane, initiating lipid peroxidation in the liver cell (Recknagel *et al.*, 1989).

In this study, we examined the hepatoprotective effect of PGP pretreatment prior to CCl₄ induced acute liver injury in the rat.

MATERIALS AND METHODS

Fifty male Sprague Dawley rats (6 weeks old) with a mean body weight of 200–230 g were used (Orient Bio, Korea). All rats were given free access to standard rodent chow (laboratory chow 5057, Purina Korea, Korea) and filtered tap water, and were housed in air-controlled room under standard conditions (temperature; 20 ± 2°C, relative humidity; 50 ± 10%, and 12 hour light/dark cycle). All animal experiments were performed in accordance with the Guidelines for Animal Care and Use Committee of Kyungpook National University. Rats were randomly assigned into 5 groups (n = 10): Group 1 (Normal control; saline alone), Group 2 (CCl₄ control; saline + CCl₄), Group 3 (PGP 50 mg/kg + CCl₄), Group 4 (PGP 100 mg/kg + CCl₄), and Group 5 (PGP 200 mg/kg + CCl₄).

Preparation of Polysaccharides isolated from *Phellinus gilvus*. The fruiting body of PG was provided by Gyeongbuk Agriculture Technology Administration (Daegu, Korea). The fruiting bodies of PG were cut into small pieces and dried at 40–50°C for 48 hrs. They were homogenized, extracted under optimal water extraction conditions of DW (1 : 25) at 100°C for 10 hrs, and the aqueous phase was concentrated at 80°C in a rotary evaporator (Büchi Rotavapor R-114, Switzerland) to reduce it to one-tenth of its volume. It was then mixed with 95% ethanol (1 : 3), the precipitate was dialyzed (1 : 100,000) in water, then filtered, centrifuged, redissolved and lyophilized successively to get polysaccharides. PGP was stored at 4°C until used.

Experimental protocols. PGP was diluted with saline and given orally by gavage for 14 days, at daily

doses of 50, 100, 200 mg/kg. The CCl₄ control group received equal amounts of saline given orally for 14 consecutive days. On the 15th day, acute liver injury was induced by single intraperitoneal injection of 1 ml CCl₄ [1 : 1 (v/v) solution of CCl₄ and olive oil] per rat (100 g) at 1 hr after the last PGP or saline dosing. The normal control group was injected with an equal volume of saline. Animals from each group were sacrificed under ether anesthesia 24 hrs after CCl₄ treatment, blood was withdrawn from the abdominal aorta, and the centrifuged serum was kept at -60°C until analyses. Also, liver tissues were obtained from the rats for determination of malondialdehyde (MDA) and antioxidant enzymes and histopathological examination. The liver was excised, and microsomal fractions were prepared by centrifugation and stored in small aliquots at -80°C until analysis could be performed.

The serum levels of aspartate aminotransferase (AST), alanine aminotransferase (ALT), and alkaline phosphatase (ALP) were determined by an automatic clinical analyzer (Hemagen Benchtop Chemistry System, Waltham, USA).

The liver was perfused with 0.9% ice-cold saline to completely remove the blood. Then it was suspended in 10% (w/v) ice-cold phosphate buffer (0.1 M, pH 7.4) cut into small pieces, and weighed and homogenized using a Teflon homogenizer. Liver homogenates were used for the assay of lipid peroxide (Ohkawa *et al.*, 1979), Superoxide dismutase (SOD) (Chan, 1996), Catalase (CAT) (Sinha, 1972), and Glutathione peroxidase (GSH) (Moron *et al.*, 1979). The degree of lipid peroxidation in the liver tissue homogenates of all rats was determined MDA formation. The protein concentration was determined by the method of Lowry *et al.* (1951) using crystalline bovine serum albumin as a standard.

Liver tissues were collected from the same lobe and fixed in 10% neutral buffered formalin solution. Liver tissue was dehydrated and embedded in paraffin. Sections were stained using haematoxylin and eosin for light microscopic observations.

The results were expressed as mean ± SEM. The difference between the means of multiple groups was evaluated with an one-way ANOVA and Tukey's multiple comparison test. If any significance was observed between the groups, Dunnett's test was used to compare the means of 2 specific groups; *P* < 0.05 was considered to be significant.

RESULTS

The changes of serum ALT, AST and ALP levels are shown in Fig. 1. Serum ALT, AST and ALP levels were

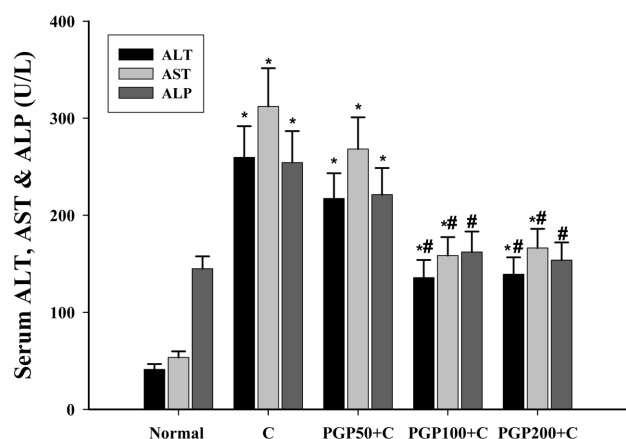


Fig. 1. Effect of PGP pretreatment on serum ALT, AST and ALP activities on CCl₄-treated rats. C, CCl₄ treatment * *P* < 0.05 versus normal control; # *P* < 0.05 versus CCl₄ treatment.

markedly elevated compared with the normal control group at 24 hrs after CCl₄ administration. In contrast, the levels were significantly decreased by PGP pretreatment (200 mg/kg) to a maximum of 53.7%, 53.3% and 60.4%, respectively. PGP administration of 100 and 200 mg/kg showed a significant (*p* < 0.05) reduction in the serum ALT, AST and ALP activities compared with CCl₄ control group. The protective effect was found to be the highest when the PGP was administered at a dose of 100~200 mg/kg prior to CCl₄ administration.

Lipid peroxide (MDA) and antioxidant enzymes (SOD, CAT, and GSH) levels in the liver homogenates of all experimental rats are shown in Table 1. Liver MDA con-

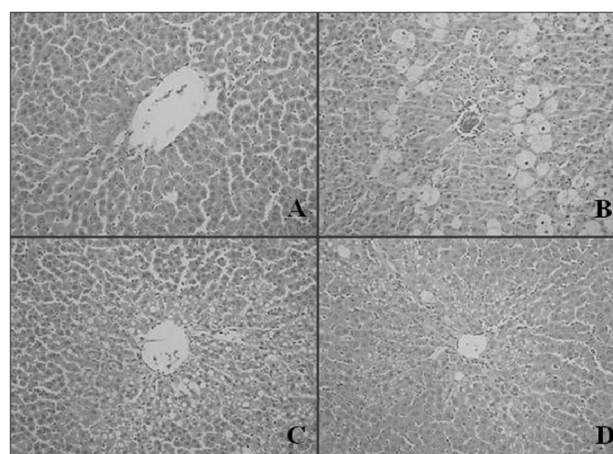


Fig. 2. Effects of PGP pretreatment on histopathology of the rat liver after 24 hrs of CCl₄-treatment. A, normal group, a little histological change was observed; B, CCl₄ control group, loss of hepatocytes, fatty changes, swelling and extensive necrosis of hepatocytes in centrilobular regions were observed; C and D, CCl₄-induced liver injury group with PGP pretreatment at different doses of 100 and 200 mg/kg, respectively, reduction in the fatty degeneration, inhibition of hepatic cells necrosis and normalization of fatty change, some inflammation and necrosis were seen (H-E, × 200).

tents were significantly increased to 1.673 μmol/mg protein in rats treated with CCl₄ compared with the normal control. Pretreatments of PGP at the doses of 50, 100 and 200 mg/kg were dose-dependently decreased the levels of MDA at 72 hrs after CCl₄ administration to 0.965, 0.931 and 0.847 μmol/mg protein, respectively.

Table 1. Effect of PGP pretreatment on levels of hepatic lipid peroxide and antioxidant enzymes in CCl₄-treated rats

Groups	Hours	MDA (μmol/mg protein)	SOD (U/mg protein)	GSH (μg/mg protein)	CAT (μmol/mg protein)
Normal	24	0.598 ± 0.039	5.93 ± 0.76	9.22 ± 0.61	67.33 ± 5.46
	48	0.561 ± 0.017	5.57 ± 0.91	9.35 ± 0.66	65.17 ± 4.74
	72	0.587 ± 0.025	5.49 ± 0.84	9.39 ± 0.96	69.14 ± 5.27
CCl ₄	24	1.673 ± 0.097*	2.65 ± 0.63*	5.36 ± 0.47*	48.71 ± 4.01*
	48	1.421 ± 0.073*	2.52 ± 0.67*	5.14 ± 0.43*	45.02 ± 4.14*
	72	1.074 ± 0.081*	3.02 ± 0.58*	5.96 ± 0.39*	52.97 ± 4.67*
CCl ₄ + PGP50	24	1.488 ± 0.092*#	2.78 ± 0.47*	5.63 ± 0.56*	51.67 ± 4.38*
	48	1.126 ± 0.074*#	2.96 ± 0.58*	5.58 ± 0.51*	54.13 ± 4.01*#
	72	0.965 ± 0.061*	3.03 ± 0.66*	5.97 ± 0.54*	59.85 ± 6.62
CCl ₄ + PGP100	24	1.421 ± 0.088*	3.82 ± 0.58*	6.36 ± 0.69*	54.36 ± 4.61*
	48	1.201 ± 0.072*#	4.11 ± 0.51#	6.81 ± 0.62*#	59.32 ± 3.58#
	72	0.931 ± 0.058*#	4.39 ± 0.46#	7.56 ± 0.73#	62.01 ± 4.03#
CCl ₄ + PGP200	24	1.032 ± 0.074*#	4.02 ± 0.39*#	6.49 ± 0.62*	59.16 ± 4.77*#
	48	0.961 ± 0.080*#	4.96 ± 0.28#	6.68 ± 0.61*#	61.25 ± 4.61#
	72	0.847 ± 0.069*#	4.87 ± 0.40#	7.72 ± 0.74#	62.18 ± 4.81#

Each value is the mean ± SEM.

MDA: malondialdehyde; SOD: superoxide dismutase; CAT: catalase; GSH: glutathione peroxidase.

**P* < 0.05 versus normal control; #*P* < 0.05 versus CCl₄ control.

Hepatic SOD, CAT, and GSH levels were significantly decreased after CCl₄ treatment in comparison with the normal control. PGP pretreatment (100 and 200 mg/kg) remarkably increased SOD, CAT, and GSH activities in liver.

The liver sections in PGP pretreated rats and normal control rats at 24 hrs after CCl₄-treatment are shown in Fig. 2. Liver tissue section of normal control is shown in Fig. 2A. In CCl₄ control group, the histology at 24 hrs after CCl₄ administration showed loss of hepatocytes, fatty changes, swelling and extensive necrosis of hepatocytes in centrilobular regions (Fig. 2B). In contrast, PGP pretreatment (100 mg/kg) showed less severe lobular damage of hepatocytes compared with CCl₄ control group (Fig. 2C). Together with hepatocytes in the centrilobular area of the CCl₄-treated group, PGP pretreatment (200 mg/kg) showed fewer necrotic and degenerative changes and little inflammatory cell infiltration by PGP dose dependent manner (Fig. 2D).

DISCUSSION

The present study was conducted to investigate whether polysaccharides isolated from PG could inhibit CCl₄ induced hepatic injury in rats in order to assess the scientific and therapeutic validation of PG.

PGP pretreatment (100 and 200 mg/kg) significantly inhibited the elevation of ALT, AST, and ALP levels by CCl₄ (Fig. 1). These results suggest that PGP has liver cell regenerative effects and is able to stabilize membrane structures in hepatic injury. However, under the present experimental single dose (1 ml/kg body weight), there were no changes in the other serum biochemical parameters at 24 hrs after CCl₄ administration.

MDA, a stable metabolite of the free radical-mediated lipid peroxidation cascade, is widely used as a marker of lipid peroxidation (Mansour, 2000). The level of MDA formation is an indirect measurement of lipid peroxidation. Lipid peroxide levels in liver tissue were found to be significantly elevated in CCl₄-treated rats. It has been shown that enhanced lipid peroxidation occurs with the development of injury in the liver of rats treated with CCl₄. PGP pretreatment decreased the elevated level of hepatic MDA by 20% at 24 hrs after CCl₄ administration. Furthermore, PGP (100 and 200 mg/kg) pretreated group showed almost normal MDA formation in liver. Our results indicated that PGP possesses potent antioxidative activity and protects liver against CCl₄-induced oxidative stress and hepatotoxicity.

PGP pretreatment remarkably increased SOD, CAT, and GSH activities in liver in comparison with the CCl₄ control. Cells have a number of mechanisms to protect

from the toxic effects of CCl₄ including free radical scavengers and chain reaction terminators such as SOD, CAT, and GSH systems. These results indicate that PGP is effectively able to inhibit production of MDA and potentiate antioxidative activity in CCl₄-injured liver.

PGP pretreatment ameliorates CCl₄-induced hepatic pathological changes such as loss of hepatocytes, fatty changes, swelling, cytoplasmic vacuolization and necrosis of hepatocytes in centrilobular regions of the liver. Especially, PGP pretreatment (200 mg/kg) reduced the fatty degeneration and hepatic cells necrosis and showed almost normalization. Therefore, although the mechanism of action may not be identified, PGP appears to exert a protective effect against CCl₄-induced hepatic injury.

The results of the present study demonstrated that pretreatment with PGP had potent hepatoprotective and hepatic regenerative effects against CCl₄-induced hepatotoxicity in rats, as evidenced by serum ALT, AST, and ALP activities, hepatic lipid peroxide and antioxidant enzymes (SOD, CAT, and GSH) levels, and histopathological appearances of liver. Moreover, these protective effects were found to be dose-dependent. Therefore, the PGP may give great health benefits to humans and animals with hepatic injuries. Further works are needed to fully characterize PGP and elucidate its possible mode of action and this work is in progress.

ACKNOWLEDGEMENTS

This work was supported by a grant (ARPC 105036-3) of the Technology Development Program for agriculture and Forestry, Ministry of Agriculture and Forestry, Republic of Korea.

REFERENCES

- Bae, J.S., Ahn, S.J., Yim, H., Jang, K.H. and Jin, H.K. (2005a). Prevention of intraperitoneal adhesions and abscesses by polysaccharides isolated from *Phellinus* spp. In a rat peritonitis model. *Surgery Annual.*, **241**, 534-540.
- Bae, J.S., Jang, K.H., Park, S.C. and Jin, H.K. (2005b). Promotion of dermal wound healing by polysaccharides isolated from *Phellinus gilvus* in rats. *Journal of Veterinary Medical Sciences*, **67**, 111-114.
- Brattin, W.J., Glende, E.A.J. and Recknagel, R.O. (1985). Pathological mechanisms in carbon tetrachloride hepatotoxicity. *Free Radical Biology and Medicine*, **1**, 27-38.
- Chan, P.H. (1996). Role of oxidants in ischemic brain damage. *Stroke*, **27**, 1124-1129.
- Dai, Y.C. and Xu, M.Q. (1998). Studies on the medicinal polypore, *Phellinus baumii*, and its kin, *P. linteus*. *Mycotaxon.*, **67**, 191-200.

- Hur, J.M., Yang, C.H., Han, S.H., Lee, S.H., You, Y.O., Park, J.C. and Kim, K.J. (2004). Antibacterial effect of *Phellinus linteus* against methicillin-resistant *Staphylococcus aureus*. *Fitoterapia*, **75**, 603-605.
- Hwang, H.J., Kim, S.W., Lim, J.M., Joo, J.H., Kim, H.O., Kim, H.M. and Yun, J.W. (2005). Hypoglycemic effect of crude exopolysaccharides produced by a medicinal mushroom *Phellinus baumii* in streptozotocin-induced diabetic rats. *Life Sciences*, **76**, 3069-3080.
- Jang, B.S., Kim, J.C., Bae, J.S., Rhee, M.H., Jang, K.H., Song, J.C., Kwon, O.D. and Park, S.C. (2004). Extracts of *Phellinus gilvus* and *Phellinus baumii* inhibit pulmonary inflammation induced by lipopolysaccharide in rats. *Biotechnology Letters*, **26**, 31-33.
- Kim, S.H., Lee, H.S., Lee, S., Cho, J., Ze, K., Sung, J. and Kim, Y.C. (2004). Mycelial culture of *Phellinus linteus* protects primary cultured rat hepatocytes against hepatotoxins. *Journal of Ethnopharmacology*, **95**, 367-372.
- Lowry, O.H., Rosebrough, N.J., Farr, A.L. and Randall, R.J. (1951). Protein measurement with folin phenol reagent. *Journal of Biological Chemistry*, **193**, 265-275.
- Lee, H.J., Lee, H.J., Lim, E.S., Ahn, K.S., Shim, B.S., Kim, H.M., Gong, S.J., Kim, D.K. and Kim, S.H. (2005). Cambodian *Phellinus linteus* inhibits experimental metastasis of melanoma cells in mice via regulation of urokinase type plasminogen activator. *Biological and pharmaceutical bulletin*, **28**, 27-31.
- Mansour, M.A. (2000). Protective effects of thymoquinone and desferrioxamine against hepatotoxicity of carbon tetrachloride in mice. *Life Sciences*, **66**, 2583-2591.
- Moron, M.S., Difiere, J.W. and Mannerwik, K.B. (1979). Levels of glutathione, glutathione reductase and glutathione-S-transferase activities in rat lung and liver. *Biochimica Biophysica Acta*, **582**, 67-78.
- Ohkawa, H., Ohishi, N. and Yagi, K. (1979). Assay of lipid peroxides in animal tissues by thiobarbituric acid reaction. *Analytical Biochemistry*, **95**, 351-358.
- Recknagel, R.O., Glende, E.A.J. and Dolak, J.A. (1989). Mechanisms of carbon tetrachloride toxicity. *Pharmacology and Therapeutics*, **43**, 139-154.
- Shon, M.Y., Kim, T.H. and Sung, N.J. (2003). Antioxidants and free radical scavenging activity of *Phellinus baumii* (*Phellinus* of Hymenochaetaceae) extracts. *Food Chemistry*, **82**, 593-597.
- Sinha, A.K. (1972). Colorimetric assay of catalase. *Analytical Biochemistry*, **47**, 389-394.
- Song, Y.S., Kim, S.H., Sa, J.H., Jin, C., Lim, C.J. and Park, E.H. (2003). Anti-angiogenic, antioxidant and xanthine oxidase inhibition activities of the mushroom *Phellinus linteus*. *Journal of Ethnopharmacology*, **88**, 113-116.
- Wasser, S.P. (2002). Medicinal mushrooms as a source of antitumor and immunomodulating polysaccharides. *Applied Microbiology and Biotechnology*, **60**, 258-274.