

## Ultrastructure of *Sarcocystis grueneri*-like Sarcocysts from Cardiac Muscle of Red Deer (*Cervus elaphus*) in Korea

Hwa-Young Son, Nam-Soo Kim, Si-Yun Ryu, Hyeon-Cheol Kim\*,  
Ju-Hee Rhee\*\*, Jeong-Gon Cho\*\*\* and Bae-Keun Park<sup>1</sup>

Research Institute of Veterinary Medicine · College of Veterinary Medicine, Chungnam National University, Daejeon 305-764, Korea

\*School of Veterinary Medicine, Kangwon National University, Chuncheon 200-701, Korea

\*\*Gyeonggi Veterinary Service Center, Suwon 441-460, Korea

\*\*\*College of Veterinary Medicine and Bio-Safety Research Institute, Chonbuk National University, Jeonju 561-756, Korea

(Accepted : December 09, 2009)

**Abstract :** *Sarcocystis grueneri*-like sarcocysts were found from the cardiac muscles of a rearing red deer (*Cervus elaphus*) carcass in Korea. In the light microscopical examination of sarcocysts, they were oval to spherical cysts and 90-170 × 110-380 μm in size. However, there was no inflammation and myofiber degeneration. In the transmission electron microscope, these cysts were located within the sarcoplasm of the host cell and filled with merozoites. The sarcocysts were enclosed by a very thin wall (0.45-0.6 μm thick) that consists of protrusions and ground substance. The primary cyst wall formed numerous strip-like protrusions which were 0.2-0.3 μm wide and up to 4.2 μm long. The protrusions were running in parallel with the surface of the cyst. A characteristic of the cyst wall was absent of fibrils inside the protrusions. Merozoites in the compartment measured about 15 × 4 μm. The merozoite consisted of four regions: micronemes and rhoptries, amylopectin granule, nucleus, and amylopectin granules. The number of rhoptry was counted in 7-13.

**Key words :** *Sarcocystis grueneri*, Ultrastructure, *Cervus elaphus*, Korea.

### Introduction

The Genus *Sarcocystis* Lankester, 1882 is related to protozoa and the largest genera of the phylum Apicomplexa that can cause mortality in many species of domestic and wild animals (30). The taxonomy of *Sarcocystis* was the list of 122 species with their synonyms and hosts given. Both definitive and intermediate hosts are known for only 56 species. The fine structure of the sarcocyst wall may change with age and not considered necessarily satisfactory for separating species (21).

Sarcocysts are detected in muscles of cervids (*i.e.* red deer, roe deer, mule deer, white-tailed deer, wapiti, moose). The cervids act as intermediate host of *Sarcocystis*. They have been intensively studied (2,4,5,6,8,9,19,29), and several species or cyst types are commonly found in the same host (1,24). Morphological studies of sarcocysts from different cervids have suggested that they harbour *Sarcocystis* spp. with highly similar cyst wall morphology. The descriptions of species have been hitherto based in part on cyst morphology, particularly at the ultrastructural level, and on life-cycle studies of this obligatory two-host parasite (7). Although a lot of papers have described the cyst with morphology and the identification of the final host, in some cases neither of these have been established.

There are several named species of *Sarcocystis* in cervids. The roe deer has been known as an intermediate host of *S. gracilis* Ratz, 1909 for a long time. Erber *et al* (12) described two new species, *S. capreolicanis* and unnamed *Sarcocystis* sp. The unnamed *Sarcocystis* sp. of Erber was tentatively classified as *Sarcocystis* cf. *hofimanni* by Sedlacek and Wesemeier (28), due to the similar morphology of the sarcocysts such as *S. hofimanni* of badgers (26), *S. wapiti* in wapiti (29) and *S. sybillensis* have been reported from North American elk (7).

The present paper describes the ultrastructural morphology of *Sarcocystis grueneri*-like sarcocysts from a naturally infected rearing red deer in Korea.

### Materials and Methods

A rearing red deer carcass from a farm in Gyeonggi province was examined for *Sarcocystis* infections. The samples from heart, liver, lung were fixed in 10% neutral buffered formaline, embedded in paraffin, sectioned at 4 μm, and stained with hematoxylin and eosin for examination by light microscopy.

For electron microscopy, pieces of heart muscle containing cysts were fixed with 2.5% glutaraldehyde solution in 0.1 M phosphate buffer (pH 7.4) for 4 hrs. After washing with buffer, the specimens were post-fixed with 1% osmium tetroxide at 4°C for 4 hrs. Afterward, the specimens were dehydrated in a

<sup>1</sup>Corresponding author.  
E-mail : bkpark@cnu.ac.kr

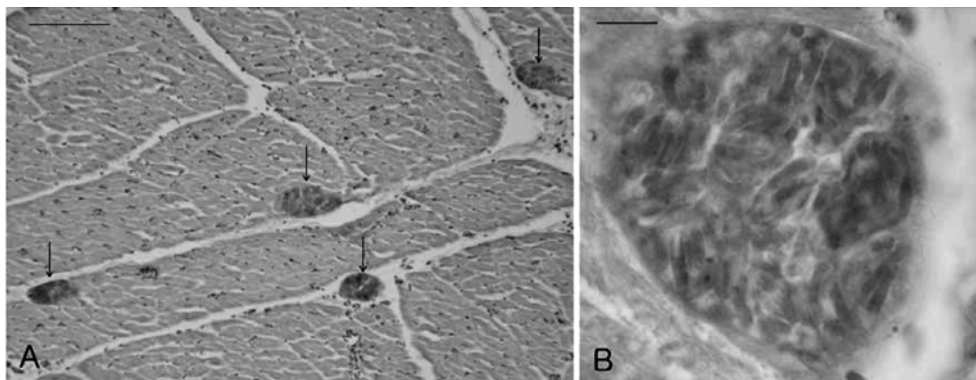
graded ethyl alcohol series and two changes of propylene oxide, and embedded in epon mixture. The ultrathin sections were stained with uranyl acetate and lead citrate and examined in a Hitachi H-600 electron microscope at 75 kV.

### Results

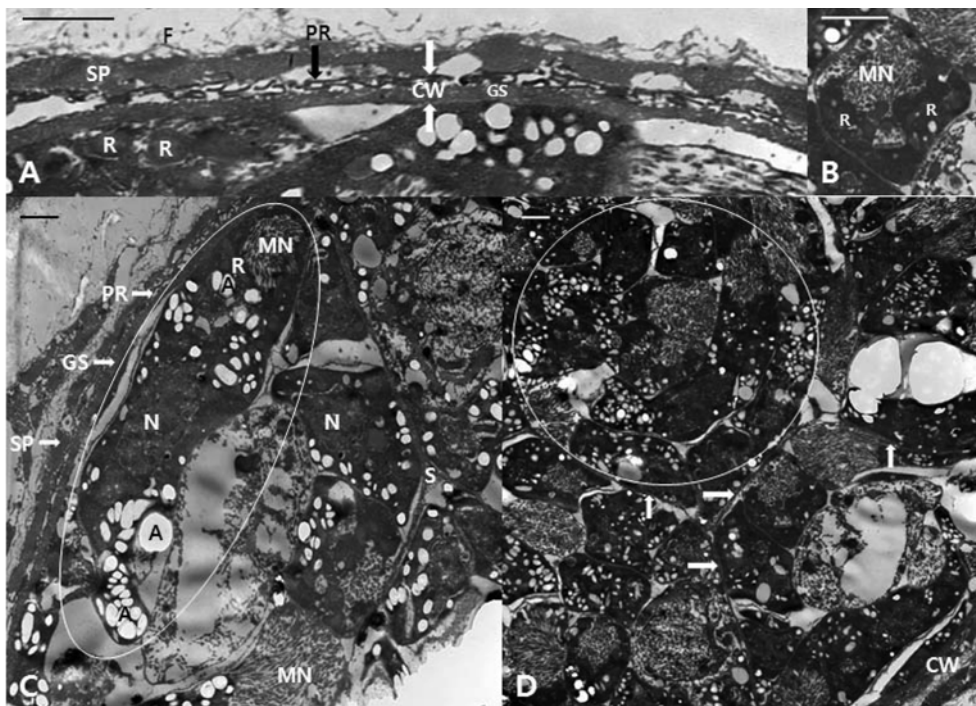
Grossly, sarcocysts were easily recognized by their whitish appearance within the dark-red coloured tissue in the heart. In histopathologic examination, the several cysts were

found in the heart muscle. They were oval to spherical shaped and measured  $90\text{-}170 \times 110\text{-}380 \mu\text{m}$  in diameter. There was no inflammation and myofiber degeneration but many sarcocysts were detected (Fig 1).

The general organization of the cyst wall is shown in Fig 2-A. These cysts were located within the sarcoplasm of the host cell and were filled with merozoites. A layer of fibrous material appeared on the outside of sarcoplasm. The sarcocysts were enclosed by a very thin wall that consists of protrusions and ground substance. The protrusions of the cyst wall



**Fig 1.** (A) Light micrographs of sarcocysts (arrows) in the cardiac muscle of *Cervus elaphus*. Sarcocysts initiated no tissue reaction. Scale bar = 100  $\mu\text{m}$ . (B) Higher magnification of the sarcocyst in A, showing many merozoites. H-E stain, Scale bar = 25  $\mu\text{m}$  (B).



**Fig 2.** Transmission electron micrographs of cyst of *Sarcocystis grueneri* from the heart of *Cervus elaphus*. (A) The sarcocyst is enclosed by a thin wall that consist of protrusions and ground substance. The protrusions of the cyst wall adjacent to the sarcoplasm of host cells. (B) The cross sectioned anterior region of merozoite containing several rhoptries. (C) The single merozoite (circle). The merozoites contain numerous amylopectin granules. (D) The merozoites in a component (circle). The component separated by thin septa (arrow) of ground substance. A, amylopectin granule; CW, cyst wall; F, fibrous material; GS, ground substance; MN, micronemes; N, nucleus; PR, protrusion; R, rhoptry; S, septa; SP, sarcoplasm. Scale bar = 1  $\mu\text{m}$ .

adjacent to the sarcoplasm (parasitophorous vacuole) of host cells. The primary cyst wall (0.45-0.6  $\mu\text{m}$  thick) was made up of the former parasitophorous vacuole membrane with a border of elongated protrusions that folded over. The primary cyst wall formed extremely thin, strip-like configuration of the cyst wall protrusions which were 0.2-0.3  $\mu\text{m}$  wide and up to 4.2  $\mu\text{m}$  long. The protrusions were running in parallel with the surface of the cyst. The cyst wall was very thin, electron-dense, and bears flattened protrusions that did not contain fibrils. The ground substance located around the base of the projections was 0.25-0.3  $\mu\text{m}$  thick and formed by a concentration of electron-dense granules which were also scattered irregularly through the ground substance including the septa (Fig 2-A). The cysts were separated by thin septa into compartments and all sarcocysts had prominent septa (Fig 2-D). A characteristic feature of the cyst wall was absence of fibrillar elements inside the protrusions. Merozoites in the compartment were elongated with a pointed anterior end and a rounded posterior end, measuring about  $15 \times 4 \mu\text{m}$ . The merozoites consisted of four regions: an anterior region containing rhoptries and a large number of micronemes, two fourth region with abundant amylopectin granules, three fourth region containing the nucleus, and a posterior region containing abundant amylopectin granules (Fig 2-B,C). The several rhoptries appeared in cross sectioned anterior region of merozoite. The number of rhoptry was counted in 7-13 (Fig 2-B).

## Discussion

This report described the ultrastructure of sarcocyst from red deer in Korea. The cysts found in heart tissue appear thin-walled in the light and electron microscope. All the cysts studied appeared to be in the same developmental stage. The structure of the cysts was typical for *Sarcocystis* spp. in that they have a primary cyst wall, beneath which was a ground substance layer which was continuous with septa dividing the interior of the cysts into compartments (22).

Micrograph has that all *Sarcocystis* species (*S. cervicanis*, *Sarcocystis* sp., *S. wapiti* and *S. sybillence*) hitherto reported in the genus *Cervus* share a common morphological pattern (6,10,18,29). However, there are considerable differences in structure and thickness of cyst walls among the sarcocysts of cervid. The cysts are described as thick-walled ( $> 10 \mu\text{m}$ ) or thin-walled (1-3  $\mu\text{m}$ ) by the thickness (6,9,10,22). A hypothesis was proposed that the thin-walled cysts of *Sarcocystis* with band like villar protrusions detected in cervids populating all the Holarctic belong to the same species and named this species *S. cf. grueneri* by Wesemeier and Sedaczek (31). The name was confirmed as *S. grueneri*. Also, they reported two more species in red deer, which were named *S. cf. capreolicanis* and *S. cf. hofmanni*. There were distinct hair and finger like villar of protrusions, respectively. The finger like protrusions were found in *S. gracilis*, *S. hominis*, *S. hirsuta*, etc. (7,10,13, 27).

Kutkiene (20) reported that three types of cysts differentiated

under a light microscope from red deer were identified as belonging to the species *S. cf. capreolicanis*, *S. cf. hofmanni* and *Sarcocystis* sp. (*S. cf. grueneri*?). Dahlgren *et al* (3) reported that the five species were found by the light and scanning electron microscopy or DNA amplification and sequencing at the small subunit rRNA gene. The three sarcocyst types were newly named, i.e. *S. alces*, *S. ovalis*, and *S. scandinavica*. He concluded that molecular methods are necessary for unequivocal species identification, as different cervid hosts harbour morphologically indistinguishable sarcocysts.

The characteristic protrusions of primary cyst wall in this study were very similar to those of *S. grueneri* from reindeer (16). The protrusions of cyst wall with strip-like folds were very thin and measured 0.25-0.3  $\mu\text{m}$  in thickness. Based on their cyst wall structure and location in cardiac muscle, the cysts in this paper belong to as described by Gjerde (15) and Gjerde (16). Gjerde (16) asserted that the name *S. grueneri* should not be used for a *Sarcocystis* sp. of the red deer. Because the original descriptions of *S. grueneri* were mainly concerned with sarcosporidia of reindeer. But the synonym of *S. grueneri*, *S. alceslatrans*, *S. cervicanis* and *S. wapiti* is very probable (6,16,24,25,28,31,32). In fact, the host was *C. elaphus* of *S. cervicanis* by Hernandez-Rodríguez *et al* (18), *Sarcocystis* sp. by Entzeroth *et al* (11) in red deer, *S. wapiti* by Speer *et al* (29) in wapiti and *S. sybillensis* by Dubey *et al* (6) in North American elk.

The final host in this study was not determined, but it is possible that these deer intermediate hosts may harbour a common species of *Sarcocystis* on the basis of other reports (11,18,29). In general, *Sarcocystis* species are specific for their intermediate hosts. But the occurrence of unusual *Sarcocystis* species has been reported (14,17,23). This paper is the first report of *S. grueneri*-like sarcocysts in red deer in Korea. It will be investigated the future studies to the identification and distribution of this species of sarcocyst in the flocks in Korea.

## References

1. Atkinson CT, Wright SD, Telford SR, Grace SJr, McLaughlin GS, Forrester DJ, Roelke ME, McCown JW. Morphology, prevalence, and distribution of *Sarcocystis* spp. in white-tailed deer (*Odocoileus virginianus*) from Florida. *J Wildl Dis* 1993; 29(1): 73-84.
2. Colwell DD, Mahrt JL. Ultrastructure of the cyst wall and merozoites of *Sarcocystis* from moose (*Alces alces*) in Alberta, Canada. *Z Parasitenkd* 1981; 65: 317-329.
3. Dahlgren SS, Gjerge B. *Sarcocystis* in moose (*Alces alces*): molecular identification and phylogeny of six *Sarcocystis* species in moose, and a morphological description of three new species. *Parasitol Res* 2008; 103: 93-110.
4. Dahlgren SS, Gjerge B. *Sarcocystis* in Norwegian roe deer (*Capreolus capreolus*): molecular and morphological identification of *Sarcocystis oviformis* n. sp. and *Sarcocystis gracilis* and their phylogenetic relationship with other *Sarcocystis* species. *Parasitol Res* 2009; 104: 993-1003.
5. Dubey JP. Coyote as a final host for *Sarcocystis* species of goats, sheep, cattle, elk, bison and moose in Montana. *Am*

- J Vet Res 1980; 41: 1227-1229.
6. Dubey JP, Jolly WR, Thorne ET. *Sarcocystis sybillensis* sp. nov. from the North America elk (*Cervus elaphus*). Can J Zool 1983; 61(4): 737-742.
  7. Dubey JP, Speer CA, Fayer R. *Sarcocystis* of animals and man. CRC Press, Boca Raton, FL. 1989; 2-13.
  8. Enzeroth R. Light, scanning, and transmission electron microscope study of the cyst wall of *Sarcocystis gracilis* Ratz, 1909 (Sporozoa, Coccidia) from the roe deer (*Capreolus capreolus* L.). 1986; 129: 183-186.
  9. Enzeroth R, Chobotar B, Scholtyseck E. Ultrastructure of *Sarcocystis* sp. from the muscle of a white-tailed deer (*Odocoileus virginianus*). Z Parasitenkd 1982; 68: 33-38.
  10. Enzeroth R, Chobotar B, Scholtyseck E, Nemeséri L. Light and electron microscope study of *Sarcocystis* sp. from the fallow deer (*Cervus dama*). Z Parasitenkd 1985; 71:33-39.
  11. Enzeroth R, Nemeséri L, Scholtyseck E (1983) Prevalence and ultrastructure of *Sarcocystis* sp. from the red deer (*Cervus elaphus* L.) in Hungary. Parasitol Hung 16:47-52.
  12. Erber M, Boch J, Bar D. Drei Sarkosporidienarten des Rehweides. Berl Münch Tierärztl Wsch 1978; 91:482-486.
  13. Gajadhar AA, Yates WDG, Allen JR. Association of eosinophilic myositis with an unusual species of *Sarcocystis* in a beef cow. Can J Vet Res 1987; 51: 373-378.
  14. Giannetto S, Poglayen G, Brianti E, Gaglio G, Scala A. *Sarcocystis gracillis*-like sarcocysts in a sheep. Vet Rec 2005; 156: 322-323.
  15. Gjerde B. A light microscopic comparison of the cysts of four species of *Sarcocystis* infecting the domestic reindeer (*Rangifer tarandus*) in northern Norway. Acta Vet Scand 1984; 25: 195-204.
  16. Gjerde B. Ultrastructure of the cysts of *Sarcocystis grueneri* from cardiac muscle of reindeer (*Rangifer tarandus tarandus*). Z Parasitenkd 1985; 71:189-198.
  17. Gjerde B. Ultrastructure of the cysts of *Sarcocystis rangi* from skeletal muscle of reindeer (*Rangifer tarandus tarandus*). Rangifer 1985; 5: 43-52.
  18. Hernández-Rodríguez S, Navarrete I, Martínez-Gómez F. *Sarcocystis cervicanis*, nueva especie parásita del ciervo (*Cervus elaphus*). Rev Ibér Parasitol 1981; 41(1): 43-51.
  19. Hudkins G, Kistner TP. *Sarcocystis hemionilatrantis* (Sp. N.) life cycle in mule deer and coyotes. J Wildl Dis 1977; 13: 80-84.
  20. Kutkiene L. Investigations of red deer (*Cervus elaphus*) *Sarcocystis* species composition in Lithuania. Acta Zoologica Lituanica 2003; 13(3): 390-395.
  21. Levine ND. Taxonomy of *Sarcocystis* (Protozoa, Apicomplexa) species. J Parasitol 1986; 72(30): 372-382.
  22. Mehlhorn H, Hartly WJ, Heydorn AO. A comparative ultrastructure study of the cyst wall of 13 *Sarcocystis* species. Protistologica 1976; 12: 451-467.
  23. Odening K, Stolte M, Bockhardt I. On the diagnostics of *Sarcocystis* of a species unusual for *Bos taurus* in dwarf zebu. Vet Parasitol 1996; 66: 19-24.
  24. Odening K. The present state of species-systematics in *Sarcocystis* Lankester, 1882 (Protista, Sporozoa, Coccidia). System Parasitol 1998; 41: 209-233.
  25. Odening K, Quandt S, Bengis RG, Stolte M, Bockhardt I. Two new *Sarcocystis* species (Protozoa: Sarcocystidae) from the hippopotamus (Artiodactyla: Hippopotamidae) in South Africa. Acta Parasitol 1997; 42: 187-191.
  26. Odening K, Stolte M, Walter G, Bockhardt I. The european badger (Carnivora: Mustelidae) as intermediate host of further three *Sarcocystis* species (Sporozoa). Parasite 1994; 1: 23-30.
  27. Pena HFJ, Ogassawara S, Sinhorini IL. Occurrence of cattle *Sarcocystis* species in raw kibbe from arabian food establishments in the city of Sao Paulo, Rrazil, and experimental transmission to humans. J Parasitol 2001; 87: 1459-1465.
  28. Sedlaczek J, Wesemeier H-H. On the diagnosis and nomenclature of *Sarcositis* species (Sporozoa) in roe deer (*Capreolus capreolus*). Appl Parasitol 1995; 36: 73-82.
  29. Speer CA, Dubey JP. *Sarcocystis wapiti* sp. nov. from the North American wapiti (*Cervus elaphus*). Can J Zool 1982; 60: 881-888.
  30. Soulsby EJJ. Helminths, arthropods and protozoa of domesticated animals. 7th ed. London, Balliere Tindall 1982; 670-691.
  31. Wesemeier HH, Sedlaczek J. One known *Sarcocystis* species and two found for the first time in red deer and fallow deer wapiti (*Cervus elaphus*) in Europe. Appl Parasitol 1995; 36: 245-251.
  32. Wesemeier HH, Sedlaczek J. One known *Sarcocystis* species and one found for the first time in fallow deer (*Dama dama*). Appl Parasitol 1995; 36: 299-302.

## 한국산 Red Deer (*Cervus elaphus*)의 심근에서 관찰된 *Sarcocystis grueneri* 양 포낭의 투과전자현미경 소견

손화영 · 김남수 · 류시윤 · 김현철\* · 이주희\*\* · 조정곤\*\*\* · 박배근<sup>1</sup>

충남대학교 수의과대학 · 동물의과학연구소, \*강원대학교 수의과대학,  
\*\*경기도 가축위생연구소, \*\*\*전북대학교 수의과대학

**요 약** : 한국산 양축 엘크시슴 (*Cervus elaphus*)의 심장 조직에서 *Sarcocystis grueneri* 양 포낭을 광학 및 투과전자현미경으로 관찰하였다. 심장조직의 병리소견에서는 다수의 포낭이 관찰되었으며, 염증 및 근섬유의 변성은 관찰되지 않았다. 염증 및 근섬유의 변성은 관찰되지 않았으며 다수의 포낭이 관찰되었다. 포낭은 난형에서 난원형 이었으며, 크기는  $90-170 \times 110-380 \mu\text{m}$ 로 측정되었다. 투과전자현미경 소견에서 포낭은 숙주세포 유래의 sarcoplasm에 싸여 있었고  $0.45-0.6 \mu\text{m}$  두께의 매우 얇은 포낭벽을 갖고 있었으며, 포낭벽은 protrusion 및 ground substance로 구성되어 있었다. 다수의 길고 가느다란 protrusion 층의 높이는  $0.2-0.3 \mu\text{m}$ , protrusion의 길이는 최장  $4.2 \mu\text{m}$ 로 측정되었다. Protrusion은 포낭의 표면과 평행하게 주행하였다. 포낭은 중격에 의하여 소실로 나뉘어져 있었고 소실에는 크기가 약  $15 \times 4 \mu\text{m}$ 인 다수의 merozoites가 존재하였다. 관찰된 모든 포낭은 같은 발육기를 갖고 있었다. Merozoite는 4개 구역 (micronemes and rhoptries, amylopectin granules, 핵 및 amylopectin granules)으로 구분되었으며 7-11 개의 rhoptry가 층체의 전방에 분포하였다.

**주요어** : *Sarcocystis grueneri*, 포낭, *Cervus elaphus*, 투과전자현미경.