

The Use of Internal Obturator Transposition for Perineal Herniorrhaphy in Three Dogs

Hun-Young Yoon, Myung-Gon Kang* and Soon-Wuk Jeong¹

Department of Veterinary Surgery, College of Veterinary Medicine, Konkuk University, Seoul 143-701, Korea

*Hangang Animal Hospital, Namyangjus 472-824, Korea

(Accepted: October 07, 2009)

Abstract : Three dogs presented to the Veterinary Medical Teaching Hospital of the University of Konkuk and Hangang Animal Hospital with a history of perineal swelling. No tenesmus, stranguria, or any clinical signs other than the swelling was observed by the owners in three dogs. On physical examination, the swelling was observed unilaterally in two dogs and bilaterally in a dog. Digital palpation to the swelling confirmed reducible perineal herniation in two dogs and irreducible perineal herniation in a dog. Plain radiographs revealed that no pelvic or abdominal contents other than the fat were displaced into subcutaneous perineal region in three dogs. Internal obturator transposition herniorrhaphy was performed for correction of perineal herniation in three dogs. Contralateral herniation involving fat was noted after surgery in a dog. The follow-up information was based on physical examination by veterinarians or telephone interview with owners. The owners reported that there was no evidence of complications related to surgery such as sciatic nerve injury, rectal prolapse, wound dehiscence, or perineal hernia recurrence in all dogs.

Key words : internal obturator transposition, perineal hernia, complication, dog.

Introduction

Perineal hernia results from a weakness, separation, and eventual failure of the muscular pelvic diaphragm that consists of the coccygeal and levator ani muscles, with subsequent displacement of pelvic or abdominal contents into subcutaneous perineal region (1,3,16,17). Perineal hernia is most common in older intact male dogs (12,13,19). Factors that have been proposed to contribute to the development of perineal hernia include chronic constipation as a result of rectal abnormalities, straining to defecate due to prostatomegaly, pelvic fracture and increased intra-abdominal pressure, and imbalance of gonadal hormones (8,15,18). Clinical signs associated with perineal hernia include constipation, obstipation, tenesmus, dyschezia, diarrhea, stranguria, and skin ulceration (4,9). Perineal hernia can become life threatening in case that the contents of hernia including the rectum and urinary bladder are irreducible concurrent with strangulation. Various herniorrhaphy techniques have been performed to treat dogs with perineal hernia and the herniorrhaphy techniques have been associated with 10% to 46% recurrence rate (2,6,11,16). There is one case report of surgical repair of perineal hernia using muscle transposition in Korea (10). The purpose of this case series is to describe the successful surgical repair of perineal hernia using internal obturator transposition in three dogs with perineal hernias.

Case 1

An 8-year-old intact male mixed breed dog weighing 7.9 kg presented to the Hangang Animal Hospital for examination of a left perineal swelling that had been present for approximately a month. No tenesmus, stranguria, or any clinical signs other than the swelling was observed by the owner. On physical examination, the swelling was observed ventral to the typical level of perineal herniation (Fig 1). Digital palpation to the swelling confirmed left reducible perineal herniation. Plain radiographs revealed that no pelvic or abdominal contents other than the fat were displaced into subcutaneous perineal

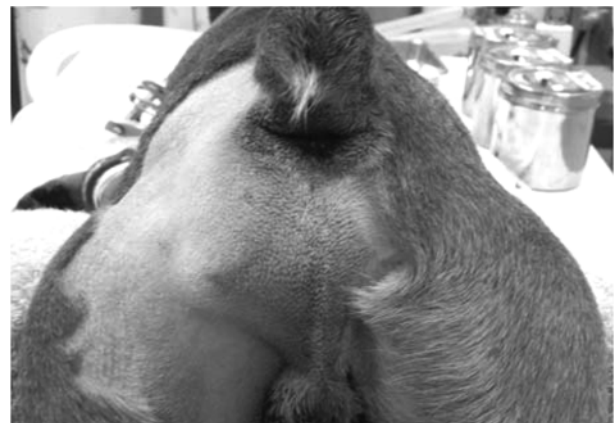

Fig 1. A left perineal swelling (Case No. 1). The swelling is located ventral to the typical level of perineal herniation.

¹Corresponding author.
E-mail : swjeong@konkuk.ac.kr

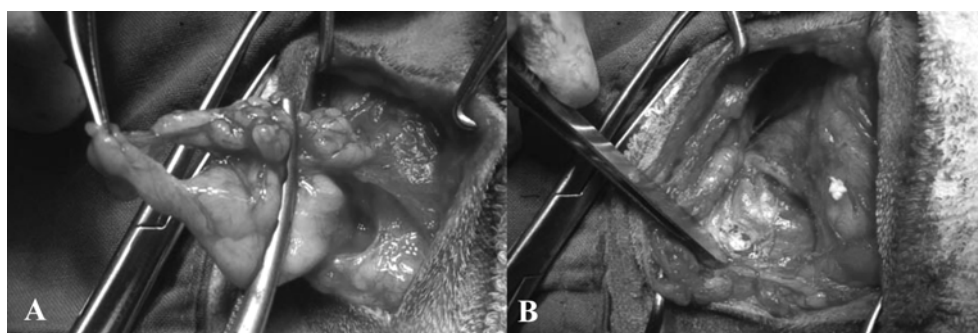


Fig 2. Pre- and post-removal photographs of retroperitoneal fat (Case No. 1). A. The retroperitoneal fat adhered to the perineal region is partially amputated using Carmalt forceps. B. Clear anatomy of the muscular pelvic diaphragm is obtained.

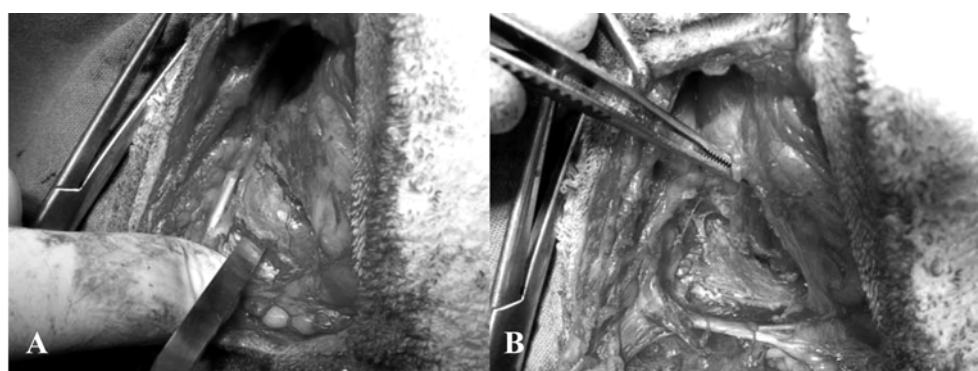


Fig 3. Pre- and post-elevation photographs of the internal obturator muscle (Case No. 1). A. The origin of the internal obturator muscle including the fascia and periosteum is incised and elevated along the caudal border of the ischium. B. Elevated internal obturator muscle is grasped using Adson-Brown tissue forceps.

region. A diagnosis of left reducible perineal hernia was made.

The patient was placed in a perineal position and the tail was fixed over the back with tape. The pelvic limbs were secured over the edge at the end of the table. In order to prevent fecal contamination during perineal surgery, a purse string suture was placed around the anus and tied to occlude the anus. Prior to tightening the purse string suture, a lubricated gauze tampon was placed in the rectum to contain feces. The surgical approach to the hernia was via a curvilinear left perineal skin incision. After blunt dissection through the hernia sac, the hernia content (retroperitoneal fat) was observed to protrude into the perineal region between the levator ani, external anal sphincter, and internal obturator muscles. The herniated fat was partially amputated and reduced (Fig 2A). The pelvic diaphragm structures (external anal sphincter, levator ani, and coccygeus muscles) and the internal obturator muscle were identified before closure (Fig 2B). Atrophy of the levator ani muscle was observed. The origin of the internal obturator muscle including the fascia and periosteum was incised along the caudal border of the ischium. Then, the periosteum and internal obturator muscle were elevated using a periosteal elevator (Fig 3). The external anal sphincter was secured to the levator ani muscle and coccygeus muscle with simple interrupted 3-0 nylon (Nylon[®]; Namhae. Co., Ltd, Korea) sutures. Then, sutures were placed from the external

anal sphincter muscle to the internal obturator muscle and from the internal obturator muscle to the coccygeus muscle respectively to close ventral defect. The subcutaneous tissues and skin were closed using 3-0 polyglycolic acid (Safil[®]; B/Braun) and 3-0 nylon (Nylon[®]; Namhae. Co., Ltd, Korea) respectively. The owner did not consent to perform a castration. The follow-up was completed by telephone 3 months after surgery. The owner was asked if there was tenesmus, stranguria, or perineal swelling related to surgery. The owner reported that there was no evidence of complications related to surgery.

Case 2

A 9-year-old castrated male mixed breed dog weighing 5.8 kg referred to the Hangang Animal Hospital for evaluation of perineal hernia recurrence that presented 5 days after surgery. The owner reported that the patient had surgery for perineal hernia twice. No tenesmus, stranguria, or any clinical signs other than the swelling was observed by the owner. On physical examination, the swelling was observed bilaterally. Digital palpation to the swelling confirmed bilateral irreducible perineal herniation. Plain radiographs revealed that no pelvic or abdominal contents other than the fat were displaced into subcutaneous perineal region. A diagnosis of bilateral irre-

ducible perineal hernia was made.

Surgical preparation was performed the same as case 1. The surgical approach to the hernia was via a curvilinear bilateral perineal skin incision. Severe adhesions of the hernia content (retroperitoneal fat) to the subcutaneous tissues were observed in the bilateral swelling. After blunt dissection, the herniated fat was partially amputated. The hernia content (retroperitoneal fat) was observed to protrude into the perineal region between the levator ani and coccygeus muscles in the bilateral perineal hernia. The remnant herniated fat was reduced. The pelvic diaphragm structures were identified before closure. Atrophy of the levator ani muscle was observed in the bilateral perineal hernia. The origins of the right and left internal obturator muscle including the fascia and periosteum were incised along the caudal border of the ischium. Then, the periosteum and internal obturator muscle were elevated using a periosteal elevator. The external anal sphincter muscle was secured to the levator ani muscle and coccygeus muscle with simple interrupted 3-0 nylon (Nylon[®]; Namhae. Co., Ltd, Korea) sutures. Then, sutures were placed from the external anal sphincter muscle to the internal obturator muscle and from the internal obturator muscle to the coccygeus muscle respectively to close ventral defect. The subcutaneous tissues and skin were closed using 3-0 polyglycolic acid (Safil[®]; B/Braun) and 3-0 nylon (Nylon[®]; Namhae. Co., Ltd, Korea) respectively. The follow-up was completed by veterinarian's physical examination 3 months after surgery. The owner was asked if there was tenesmus, stranguria, or perineal swelling related to surgery. The owner reported that there was no evidence of complications related to surgery.

Case 3

A 5-year-old castrated male Chihuahua weighing 1.8 kg presented to the University of Konkuk Veterinary Medical Teaching Hospital for examination of a right perineal swelling that had been present for approximately a month. No tenesmus, stranguria, or any clinical signs other than the swelling was observed by the owner. On physical examination, digital palpation to the swelling confirmed right reducible perineal herniation. Plain radiographs revealed that no pelvic or abdominal contents other than the fat were displaced into subcutaneous perineal region. A diagnosis of right reducible perineal hernia was made.

Surgical preparation was performed the same as case 1. The surgical approach to the hernia was via a curvilinear right perineal skin incision. After blunt dissection through the hernia sac, the hernia content (retroperitoneal fat) was observed to protrude into the perineal region between the levator ani and coccygeus muscles. The herniated fat was partially amputated and reduced. The pelvic diaphragm structures were identified before closure. Atrophy of the levator ani and coccygeus muscles was observed. The origin of the internal obturator muscle including the fascia and periosteum was incised along the caudal border of the ischium. Then, the periosteum and

internal obturator muscle were elevated using a periosteal elevator. The external anal sphincter muscle was secured to the levator ani muscle, coccygeus muscle, and sacrotuberous ligament with simple interrupted 3-0 polyglycolic acid (Safil[®]; B/Braun) sutures. Then, sutures were placed from the external anal sphincter muscle to the internal obturator muscle and from the internal obturator muscle to the sacrotuberous ligament respectively to close ventral defect. The subcutaneous tissues and skin were closed using 3-0 polyglycolic acid (Safil[®]; B/Braun) and 3-0 nylon (Nylon[®]; Namhae. Co., Ltd, Korea) respectively. Complication was noted after surgery. The dog was presented a month after surgery with contralateral herniation involving fat. Internal obturator transposition was performed to treat contralateral herniation. The follow-up was completed by veterinarian's physical examination 3 months after the second surgery. The owner was asked if there was tenesmus, stranguria, or perineal swelling related to surgery. The owner reported that there was no evidence of complications related to surgery.

Discussion

Sexually intact dogs may be predisposed to perineal hernia in that hormonal influences have been implicated in weakening the pelvic musculature (12,15). In this case report, a dog (case 1) was sexually intact and two dogs (case 2, 3) were castrated. No underlying rectal disease or prostatic disease was observed in cases 2 and 3. In the cases 2 and 3, neurogenic atrophy of the levator ani and coccygeus muscles or myopathy might be a factor that results in anatomic variation of the pelvic diaphragm. Perineal hernia develops exclusively in male dogs, suggesting an anatomic difference between males and females with a possible hormonal contribution. In this case report, three dogs were male as well.

Four types of canine perineal hernia have been described: (1) dorsal perineal hernia—herniation between the coccygeus and levator ani muscles; (2) sciatic perineal hernia—herniation between the coccygeus muscle and sacrotuberous ligament; (3) caudal perineal hernia—herniation between the external anal sphincter, levator ani, and internal obturator muscles; and (4) ventral perineal hernia—herniation ventral to the ischio-urethralis muscle, between the bulbocavernosus and ischiocavernosus muscles (13,19). In case 1, the swelling was observed ventral to the typical level of perineal herniation. During surgery, a type of herniation was confirmed as caudal perineal hernia. Location of swelling might be helpful to presume a type of perineal hernia and determine surgical approach.

Choosing an appropriate technique for herniorrhaphy is very important to prevent perineal hernia recurrence, restore normal defecation and urination, and minimize postoperative complication. Traditional technique, muscle flap technique (the internal obturator, superficial gluteal, semitendinosus muscles), and use of implants (synthetic mesh, porcine dermal collagen, porcine small intestinal submucosa) are commonly used repair technique (16). In this case report, muscle flap technique

using the internal obturator muscle transposition was performed. Typically, internal obturator muscle transposition is favored over the traditional technique for perineal hernia with severe muscle atrophy because of the low recurrence rate and minimal complication (15). Especially the internal obturator muscle transposition was very effective to repair defect of pelvic diaphragm in case 1 that a type of herniation was caudal perineal hernia. Traditional herniorrhaphy does not provide proper repair to ventral portion of defect in caudal perineal hernia. However, if the internal obturator muscle is atrophied, repair can be difficult. Previous report described use of polypropylene mesh in 59 perineal hernia with atrophy of the internal obturator muscle, having an overall success rate of 80.5% (17).

Some technical and anatomic consideration in surgery may increase the likelihood of a successful surgery. The external anal sphincter muscle should be secured to the sacrotuberous ligament as well as the levator ani and coccygeus muscles in case that the levator ani and coccygeus muscles are atrophic, taking care to not place the suture around or through the sciatic nerve because of the proximity of the nerve to this ligament. When the origin of the internal obturator muscle is incised and elevated along the caudal border of the ischium, the fascia and periosteum should be included to provide greater holding power on repairing defect of perineal hernia. The retroperitoneal fat can be partially amputated and then reduced. A blunt dissection may not be effective to provide anatomy of the muscular pelvic diaphragm in case that the retroperitoneal fat is adherent to the perineal region severely. Fail to obtain anatomy of the muscular pelvic diaphragm can decrease the likelihood of a successful surgery.

Castration is recommended during herniorrhaphy because the cause of pelvic diaphragm weakening is believed to be associated with male hormones (19). The effects of castration on recurrence rates have been reported (7). One study documented a recurrence risk 2.7 times higher in non-castrated dogs than in castrated dogs (7). In case 1, castration was considered; however, the owner did not consent to perform a castration.

Contralateral herniation is not common complication described after perineal hernia repair, accounting for 3.5% of dogs with perineal hernia (9). Although herniation occurs unilaterally, the contralateral side is frequently weak (5). In case 3, severe atrophy of the levator ani and coccygeus muscles was observed during surgery and the contralateral pelvic musculature weakening was presumable.

Conclusion

This case series described the successful surgical repair of perineal hernia using internal obturator transposition in three dogs with perineal hernias. A study of large case series with long-term follow-up is warranted to better determine the overall success and complication rates of surgical repair of perineal hernia using internal obturator transposition.

References

- Bellenger CR, Canfield RB. In: Slatter D (ed), Text book of small animal of surgery, 3rd ed. Philadelphia: Saunders. 2003: 487-498.
- Bilbrey SA, Smeak DD, Dehoff W. Fixation of the deferent ducts for retrodisplacement of the urinary bladder and prostate in canine perineal hernia. *Vet Surg* 1990; 19: 24-27.
- Bongartz A, Carofiglio F, Balligand M, Heimann M, Hamaide A. Use of autogenous fascia lata graft for perineal herniorrhaphy in dogs. *Vet Surg* 2005; 34: 405-413.
- Brissot HN, Dupré GP, Bouvy BM. Use of laparotomy in a staged approach for resolution of bilateral or complicated perineal hernia in 41 dogs. *Vet Surg* 2004; 33: 412-421.
- Burrows CF, Harvey CE. Perineal hernia in the dog. *J Small Anim Pract* 1973; 14:315 -332.
- Gilley RS, Caywood DD, Lulich JP, Bowersox TS. Treatment with a combined cystopexy-colopecty for dysuria and rectal prolapsed after bilateral perineal herniorrhaphy in a dog. *J Am Vet Med Assoc* 2003; 222: 1717-1721.
- Hayes HM, Wilson GP, Tarone RE. The epidemiologic features of perineal hernia in 771 dogs. *J Am Anim Hosp Asso* 1978; 14:703-707.
- Head LL, Francis DA. Mineralized paraprostatic cyst as a potential contributing factor in the development of perineal hernias in a dog. *J Am Vet Med Assoc* 2002; 221: 533-535.
- Hosgood G, Hedlund CS, Pechman RD, Dean PW. Perineal herniorrhaphy: perioperative data from 100 dogs. *J Am Anim Hosp Asso* 1995; 31:331-342.
- Lee HB, Choi SJ, Lee CH, Chon SK, Choi IH, Kim NS. Surgical corrections of perineal hernia by muscle transposition in dogs. *J Vet Clin* 2005; 22: 435-438.
- Matthiesen DT. Diagnosis and management of complications occurring after perineal hemiorrhaphy in dogs. *Compend Contin Educ Pract Vet* 1989; 11: 797-822.
- Niles JD, Williams JM. Perineal hernia with bladder retroflexion in a female cocker spaniel. *J Small Anim Pract* 1999; 40: 92-94.
- Rochat MC, Mann FA. Sciatic perineal hernia in two dogs. *J Small Anim Pract* 1998; 39: 240-243.
- Sjollem BE, Van-sluis FJ. Perineal hernia repair in the dog by transposition of the internal obturator muscle II: complications and results in 100 patients. *Vet Q* 1989; 11: 18-23.
- Sontas BH, Apaydin SÖ, Toydemir TSF, Kasikci G, Ekici H. Perineal hernia because of retroflexion of the urinary bladder in a Rottweiler bitch during pregnancy. *J Small Anim Pract* 2008; 49: 421-425.
- Stoll MR, Cook JL, Pope ER, Carson, WL, Kreeger JM. The use of porcine small intestinal submucosa as a biomaterial for perineal herniorrhaphy in the dog. *Vet Surg* 2002; 31: 379-390.
- Szabo S, Wilkens B, Radasch, RM. Use of polypropylene mesh in addition to internal obturator transposition: a review of 59 cases (2000-2004). *J Am Anim Hosp Asso* 2007; 43: 136-142.
- Welches CD, Scavelli TD, Aronsohn MG, Matthiesen DT. Perineal hernia in the cat: a retrospective study of 40 cases. *J Am Anim Hosp Asso* 1992; 28: 431-438.
- Fossum TW. Perineal hernia. In: Small animal surgery, 3rd ed. St. Louis: Mosby. 2007: 515-520.

개에서 내폐쇄근 변위술을 이용한 회음탈장 정복 3예

윤현영 · 강명곤* · 정순욱¹

건국대학교 수의과대학 수의외과학 교실, *한강 동물병원

요 약 : 회음부 팽대 병력을 보이는 세 마리 개가 건국대학교 부속 동물병원과 한강 동물병원에 내원하였다. 회음부 팽대 외에 다른 증상이 없었으며 신체 검사에서 두 마리는 환납성 한 마리는 비 환납성임을 확인 하였다. 일반 방사선 사진에서 골반강 또는 복강 내 장기가 탈장 낭 내에 없음을 확인하였다. 회음 탈장의 교정을 위해 내폐쇄근 변위 탈장 봉합술 실시 하였다. 한 마리에서 수술 후 지방을 함유하고 있는 대축 탈장이 확인되었다. 수술 후 정기 점진은 수의사의 신체 검사 혹은 보호자와의 전화 통화를 통해 실시 되었으며 세 마리 모두에서 수술과 관련한 좌골 신경 손상, 직장 탈출, 수술 부위 열개, 회음 탈장 재발과 같은 합병 증상이 없음을 확인하였다.

주요어 : 내폐쇄근 변위 탈장 봉합술, 회음 탈장, 합병 증상, 개.