

## Repair of the Traumatic Oronasal Communication in a Dog with a Palatal Prosthesis : a Case Report

Kyung Mi Shim<sup>1</sup>

Department of Radiology, Nambu University, Gwangju 506-706, Korea

(Accepted : December 09, 2009)

**Abstract :** A 5-year-old intact female mixed dog was admitted to the Veterinary Teaching Hospital for reconstructive surgery of traumatic oronasal communication in the palatal region after suffering a facial gunshot injury. The surgical procedure involved making buccal mucosal flaps as well as a transposition flap of the hard palate mucoperiosteum from the tissue adjacent to the defect, followed by applying a prosthetic appliance to protect the surgical flaps. A satisfactory outcome was obtained using a palatal prosthesis.

**Key words :** oronasal communication, flap surgery, acrylic splint, dog.

### Introduction

Palatal defects occur in dogs and cats for various reasons including trauma, electrical shock, gunshot wounds, foreign body penetration, and pressure necrosis (10). Full-thickness palatal defects that result in the formation of an oronasal communication are rarely healed spontaneously. Most patients suffering from large palatal defects usually do not survive for a long period due to malnutrition or complications such as pneumonia (9) and inflammation.

Several techniques have been used to repair palatal defects (3). Large defects located in the palate can be difficult to repair, and postoperative dehiscence is a common complication (2). Our surgical procedure was performed using buccal mucosal flaps and a free graft flap of a hard palate mucoperiosteum from the tissue adjacent to the defect, and the application of a prosthetic appliance to protect the surgical flaps resulting in a satisfactory outcome. This report describes the management of this injury including reduction, and stabilization using a prosthetic appliance.

### Case

A 5-year-old intact female mixed dog weighing 25 kg, which had suffered a recurrent traumatic oronasal communication of the palatal region after a facial gunshot injury, was referred for a further investigation and treatment. The patient had 5 × 3 cm hard palatal defect located centrally between the maxillary premolars (Fig 1). Seven days before being referred, the dog was taken to a local veterinarian immediately after the trauma, and surgical repair was performed.

However, the patient's condition did not improve, and the dog showed bilateral nasal bleeding and open mouth breathing. However, the physical examination did not reveal particular systemic discomfort, and the hematological and serum chemistry values were within the reference ranges.

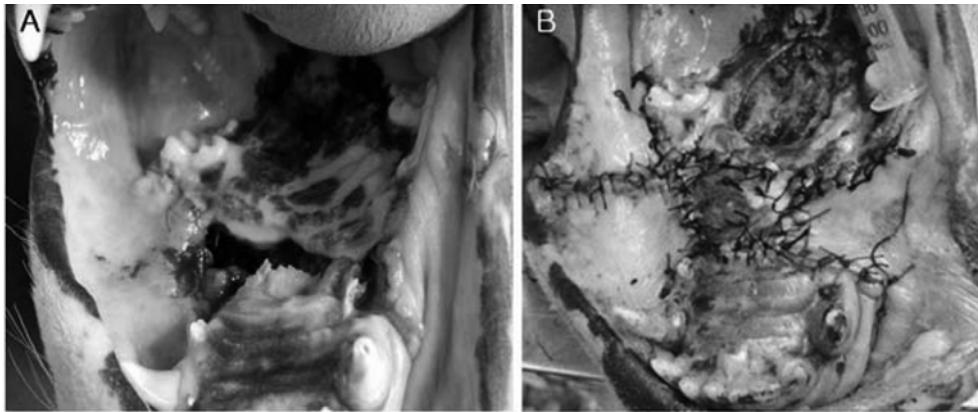The closed oral examination revealed a 5 × 3 cm hard palatal defect as well as communication between the oral and nasal cavities (Fig 1A).

For soft-tissue reconstruction, a double flap technique (buccal mucosal flaps and hard palatal free flap) was used to repair the defect. First, the buccal flap on the left side of the defect was inverted over the defect to provide a mucosal surface on the nasal aspect. Second, the buccal flap on the right side of the defect was advanced over the first buccal flap, but was too small to cover all parts of the first buccal flap. Therefore, a hard palatal free flap was harvested and used to cover the remaining portion of the first buccal flap using 3-0 monofilament polygalactin-910 in a simple interrupted pattern (Fig 1B). All surgical procedures followed the basic guidelines of using sufficient tissue in the flap, taking large bites, not placing sutures directly over the defect, and allowing no tension on the suture line.

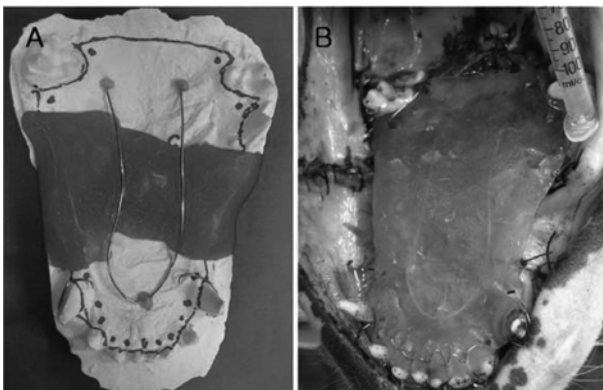
Before surgery, an impression was taken using arginate, and poured with hard stone. Based on this model, a prosthetic appliance was made using methylmethacrylate resin and wire. After the surgical soft-tissue reconstruction, the prosthetic appliance was fixed to both maxillary incisors, canine and 1st molar teeth using dental wire (Fig 2).

The dog adapted well to the dental implant after being discharged from hospital. However, 2 weeks after surgery, the oral examination revealed a 3 × 2 cm hard palatal dehiscence and the communications between oral and nasal cavities (Fig 3A). A second surgical procedure was performed using the same technique except for the hard palatal free flap (Fig 3B).

<sup>1</sup>Corresponding author.  
E-mail : kmshim@nambu.ac.kr



**Fig 1.** The patient had a 5 × 3 cm hard palatal defect centrally with communication between the oral and the nasal cavities (A). A primary surgery was performed using buccal mucosal flaps and a free graft flap of hard palate mucoperiosteum from the tissue adjacent to the defect (B).

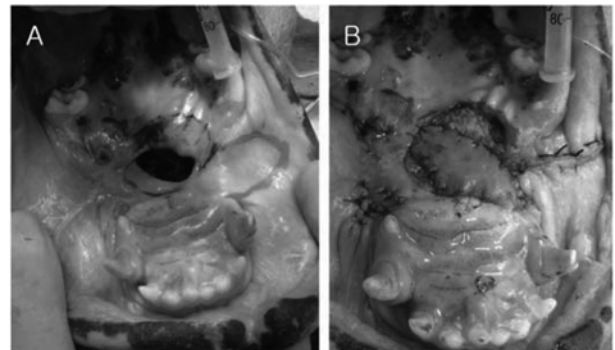


**Fig 2.** A prosthetic appliance was made using methylmethacrylate resin and wire based on a dental stone model (A). The prosthetic appliance was fixed to both maxillary incisors, canines and 1st molar teeth using dental wire (B).

A reevaluation performed 2 weeks after surgery showed that the palatal defect had reduced considerably but a small defect remained. The prosthesis was maintained for an additional week. Although the hard palatal defect was not completely closed, the defect was minimal and the dog showed no signs of sneezing or nasal discharge. One year after surgery, the dog is functioning well.

### Discussion

The closure of a large palatal defect can sometimes be difficult to achieve using a flap technique. Although many techniques have been described, the inability to close the defect, tension at the suture lines and dehiscence are common complications (5). Repeated surgery was performed in our case. At the primary surgery, which was performed by another local veterinarian, buccal mucosal flaps were used to close the palatal defect, but the flaps did not tolerate irritation as a result of tongue movement. Therefore, we performed a double-layer flap consisting of buccal mucosal flaps and a free graft



**Fig 3.** At 2 weeks after surgery, the patient had a 3 × 2 cm hard palatal dehiscence as well as communication between the oral and the nasal cavity (A). A secondary surgery was performed using the same technique (primary surgery) except for the hard palatal free flap (B).

flap of hard palatal mucoperiosteum adjacent to the defect. This was followed by applying a prosthetic appliance to protect the surgical flaps.

The use of prosthetic appliances to treat palatal defects is common in humans (6) and has been described in the veterinary literature (1,7). The decrease in the palatal defect size might be the result of a combination of flap surgery and prosthesis. It is believed that a palatal prosthesis might be effective in protecting the surgical flaps and provide a better blood supply to the surgical flaps. A palatal prosthesis also prevents irritation of the tongue during movement and feeding.

In earlier studies, a prosthesis made from thermoplastics or alloy, such as cobalt and chromium, was used to cover the suture line or traumatic palate (4,8). The prosthesis was fixed bilaterally to the canines and premolars or molars using stainless steel wire that had been passed through the alveolar bone below the tooth roots. The prosthesis used in this case was made from acrylic resin and fixed bilaterally to the canines and 1st molars with stainless steel wire. It appears to be comfortable for the dog and is also practical because it can be

easily removed and fixed repeatedly. In humans, prosthetic appliances are removed daily for cleaning. It was not possible to remove and clean the appliance on a daily basis. In these cases, wire clasps wrapped around the teeth to hold the appliance in place may be placed close to the free gingival margin, and act as plaque-retaining areas. Therefore, daily oral home-care is very important (7).

### Conclusion

This case report shows that a prosthetic appliance can be used to manage a palatal defect and prevent self-mutilation. In addition, it is important that veterinarians have sufficient knowledge of flap surgery and carefully protect the surgical wound.

### References

1. Coles BH, Underwood LC. Repair of the traumatic oronasal fistula in the cat with a prosthetic acrylic implant. *Vet Rec* 1988; 122: 359-360.
2. Dundas JM, Fowler JD, Shmon CL, Clapson JB. Modification of the superficial cervical axial pattern skin flap for oral reconstruction. *Vet Surg* 2005; 34: 206-213.
3. Hale FA, Sylvestre AM, Miller C. The use of a prosthetic appliance to manage a large palatal defect in a dog. *J Vet Dent* 1997; 14: 61-64.
4. Ishikawa Y, Goris RC, Nagaoka K. Use of a corticocancellous bone graft in the repair of a cleft palate in a dog. *Vet Surg* 1994; 23: 201-205.
5. Kirby BM. Oral flaps. Principles, problems, and complications of flaps for reconstruction of the oral cavity. *Probl Vet Med* 1990; 2: 494-509.
6. Polyzois GL. Light-cured combination obturator prosthesis. *J Prosthet Dent* 1992; 68: 345-347.
7. Smith MM, Rockhill AD. Prosthodontic appliance for repair of an oronasal fistula in a cat. *J Am Vet Med Assoc* 1996; 208: 1410-1412.
8. Thoday KL, Charlton DA, Graham-Jones O, Frost PL, Pullen-Warner E. The successful use of a prosthesis in the correction of a palatal defect in a dog. *J Small Anim Pract* 1975; 16: 487-494.
9. Waldron DR, Martin RA. Cleft palate repair. *Probl Vet Med* 1991; 3: 142-152.
10. Welch JA, Swaim SF. Nasal and facial reconstruction in a dog following severe trauma. *J Am Anim Hosp Assoc* 2003; 39: 407-415.

## 개에서 창상성 구비강 개통의 아크릴 부목을 이용한 치유 증례

심경미<sup>1</sup>

남부대학교 방사선학과

**요 약** : 5년령의 암컷 사냥개가 사냥 중 안면부 총상에 의한 구비강 개통으로 내원하였다. 협측피판 및 경구개 접막 골막피판술을 이용하여 구개부의 창상성 구비강 개통에 대한 재건술을 실시하였다. 그리고 수술부위의 보호를 위해 인상 과정을 통해 정교하게 제작된 아크릴 부목을 적용함으로써 비교적 큰 결손부를 성공적으로 치유한 증례를 보고하고자 한다.

**주요어** : 구비강 개통, 피판술, 아크릴 부목, 개.