

Clinical Article

Endoscopic Transforaminal Suprapedicular Approach in High Grade Inferior Migrated Lumbar Disc Herniation

Hyeun Sung Kim, M.D.,¹ Chang Il Ju, M.D.,² Seok Won Kim, M.D.,² Jong Gue Kim, M.D.²

Department of Neurosurgery,¹ Mokpo Hankook Hospital, Korea

Department of Neurosurgery,² College of Medicine, Chosun University, Gwangju, Korea

Objective : Although endoscopic procedures for lumbar disc diseases have improved greatly, the postoperative outcomes for high grade inferior migrated discs are not satisfactory. Because of anatomic limitations, a rigid endoscope cannot reach all lesions effectively. The purpose of this study was to determine the feasibility of endoscopic transforaminal suprapedicular approach to high grade inferior-migrated lumbar disc herniations.

Methods : Between May 2006 and March 2008, a suprapedicular approach was performed in 53 patients with high grade inferior-migrated lumbar disc herniations using a rigid endoscope and a semi-rigid flexible curved probe. One-to-four hours after surgery, the presence of remnant discs was checked with MRI. The outcomes were evaluated with the visual analogue scale (VAS) score and the Oswestry Disability Index (ODI) one week after surgery.

Results : The L2-3 level was involved in 2 patients and the L3-4 level was involved in 14 patients, while the L4-5 level was involved in 39 patients. There were single piece-type in 34 cases and a multiple piece-type in 19 cases. Satisfactory results were obtained in all cases. The mean preoperative VAS for leg pain was 9.32 ± 0.43 points (range, 7-10 points), whereas the mean ODI was 79.82 ± 4.53 points (range, 68-92 points). At the last follow-up examination, the mean postoperative VAS for leg pain was 1.78 ± 0.71 points and the mean postoperative ODI improved to 15.27 ± 3.82 points.

Conclusion : A high grade inferior migrated lumbar disc is difficult to remove sufficiently by posterolateral endoscopic lumbar discectomy using a rigid endoscope. However, a satisfactory result can be obtained by applying a transforaminal suprapedicular approach with a flexible semi-rigid curved probe.

KEY WORDS : Migrated disc herniation · Percutaneous endoscopic lumbar discectomy · Rigid endoscope · Flexible curved probe.

INTRODUCTION

A microscopic discectomy has generally been performed as the surgical treatment for lumbar disc diseases^{2,3,31,47}, however, endoscopic discectomy has improved considerably^{6,7,10,12,18,25,26,30,41,44,46,48}.

In endoscopic lumbar discectomy, the lateral approach has been favored primarily for levels higher than L4-5^{10,44,46,48} and the success rate exceeds 90%^{10,21,26,30,41,44,46,48}. The causes of surgical failure include the difficulty in reaching the lesion due to anatomic limitations, excessive foraminal migration, a centrally-located large disc (parti-

cularly when calcified), the presence of bony osteophytes, the presence of residual epidural scarring from a previous procedure and, especially, when the migrated protrusion is inferior along the nerve root^{10,26,41}. Due to anatomic reasons, lesions located in the epidural space are difficult to reach, thus remnants are readily left and the success rate of surgery is noticeably reduced^{25,26,41}. We applied a transforaminal suprapedicular approach to a high grade inferior-migrated lumbar disc using a rigid endoscope and a semi-rigid flexible curved probe, and report satisfactory results with a review of the literature.

MATERIALS AND METHODS

Patient

In 2007, Lee introduced a 4-zone classification of the disc migration based on the direction and distance from the disc

• Received : July 16, 2008 • Accepted : January 28, 2009

• Address for reprints : Chang Il Ju, M.D.
Department of Neurosurgery, College of Medicine, Chosun University,
588 Seoseok-dong, Dong-gu, Gwangju 501-717, Korea
Tel : +82-62-220-3126, Fax : +82-62-227-4575
E-mail : jchangil@hanmail.net

space in preoperative surgical MRI images. According to this classification, the high grade inferior migrated lumbar disc herniation was defined as zone 4 with disc material migrated far-downward from the center to the inferior margin of the lower pedicle^{25,26}. Fifty-three cases of high grade inferior-migrated lumbar disc herniation were included in this study.

All patients had severe radiating leg pain, 43 patients had buttock pain, 48 patients had back pain, and 23 patients had paresthesias and numbness along the painful leg dermatome, but there was no motor weakness of the lower extremities, or bladder or bowel dysfunction. Thirty-two migrated extrusion-type cases were beyond the confines of the posterior longitudinal ligament, but were still in continuity with the disc, and there were 21 migrated sequestered-type cases in which the disc material was no longer in continuity with the disc space.

Anesthesia

There is generally a trend in favor of a local anesthetic procedure for nerve root injury monitoring during surgery and for the early assessment of surgical results^{18,25,26,30,41,43,46}, nevertheless at our hospital, epidural anesthesia was performed in all cases. Either 100 µg fentanyl and 0.5% pucain were diluted by 1/2 and prepared 0.25% solution and approximately 15-20 cc was injected to the epidural space or 15-20 cc 0.5% pucain stock solution was injected to the epidural space^{9,15,32,38}. Anesthesia was assessed by checking the sensory level, and surgery was performed. During surgery, we were able to detect the patient's sensory and motor changes because this type of anesthetic procedure does not block the nerve root completely.

Surgical technique

The sequence of surgery was identical to the general transforaminal endoscopic procedure^{30,44,46,49}. Preoperative imaging studies, in addition to intraoperative fluoroscopy, were conducted to ascertain the entry site. The skin entry point was typically 8-12 cm from the midline. Prior to the procedure, using indigo-carmin dye, evocative chromodisography^{25,44} was performed. An operative sheath (YESS System : Wolf, Knittlingen, Germany) was installed in the disc space. Immediate suprapedicular approach was preferred for only sequestered migration type disc herniation without continuity to the disc space and disc of origin was not protruded. In suprapedicular approach, after disc extraction, epidural bleeding is inevitable, which greatly impedes performance of subsequent procedures. Therefore, if the case required disc decompression, it was better to first perform decompression identical to the posterolateral

procedure^{30,44,46,48}. After completion of the decompression, the cannula was removed carefully from the foraminal space, and moved to the upper margin of the lower vertebral pedicle. The pedicle was surrounded by abundant soft tissues, fat, and blood vessels. The superior margin of the pedicle was secured by removing these structures completely using a high voltage bipolar probe manufactured by Ellman (Ellman Innovation, New York, USA) and forceps. If the pedicle and upper margin of the lower vertebra were properly prepared, a sufficient space to perform the supra-pedicular approach could be obtained (Fig. 1). When spondylosis in the upper margin of the lower vertebra was present, we removed the upper margin of the lower vertebra using a punch to make a sufficient space. Upon performing the procedure, the epidural space and the traversing nerve root are exposed, and occasionally, the ruptured disc material is exposed first and thus it could be removed readily. However, the inferior migrated ruptured material is present below the traversing nerve root in most cases, and care must be exercised so as not to injure the traversing nerve root. In the endoscopic view, the blue-stained disc fragment was visible at the upper quadrant of the view, but a straight probe or forceps could not reach the disc area, so we used a semi-rigid flexible curved probe (RZ Medizin Technik GmbH, Tuttlingen, Germany) to carefully hook and pull the disc material out to the center of the endoscopic view. Then, a forceps could reach the disc fragment and easily remove it (Fig. 2). If the disc material was extracted and thus nerve root decompression was sufficient, massive bleeding could obscure the structural findings in the endoscopic view. However, this bleeding could be controlled by bipolar coagulation and saline irrigation, and the sufficiently movable traversing nerve root could be assessed. If the disc material stained blue was not detected, the disc material was extracted and the nerve root was decompressed. Finally, the cannula with the endoscope was removed carefully.

Evaluation

Based on MRI and 3D CT with discogram images taken prior to surgery, migration level, lesion type, and the relation with adjacent anatomical structures were analyzed (Fig. 3). Approximately 1-4 hours after surgery, the remnant disc was assessed by checking with MRI. Approximately 1 week after surgery, the improvement of patient was evaluated by Visual Analogue Pain Score (VAS) and Oswestry Disability Scores (ODI) including neurologic testing. The functional outcome was measured by the change in preoperative and postoperative VAS. A change of more than 7.5 points was deemed of an excellent results, 5 points

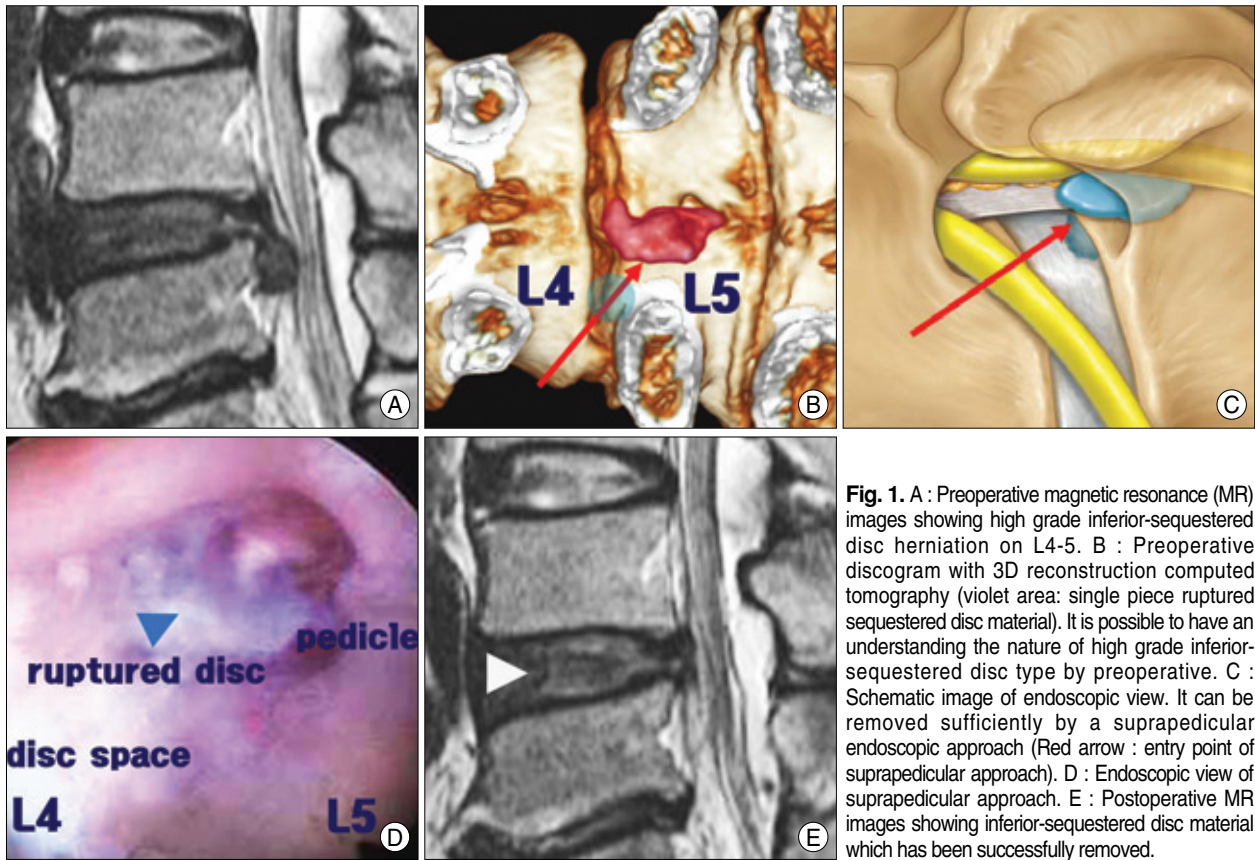


Fig. 1. A : Preoperative magnetic resonance (MR) images showing high grade inferior-sequestered disc herniation on L4-5. B : Preoperative discogram with 3D reconstruction computed tomography (violet area: single piece ruptured sequestered disc material). It is possible to have an understanding the nature of high grade inferior-sequestered disc type by preoperative. C : Schematic image of endoscopic view. It can be removed sufficiently by a suprapedicular endoscopic approach (Red arrow : entry point of suprapedicular approach). D : Endoscopic view of suprapedicular approach. E : Postoperative MR images showing inferior-sequestered disc material which has been successfully removed.

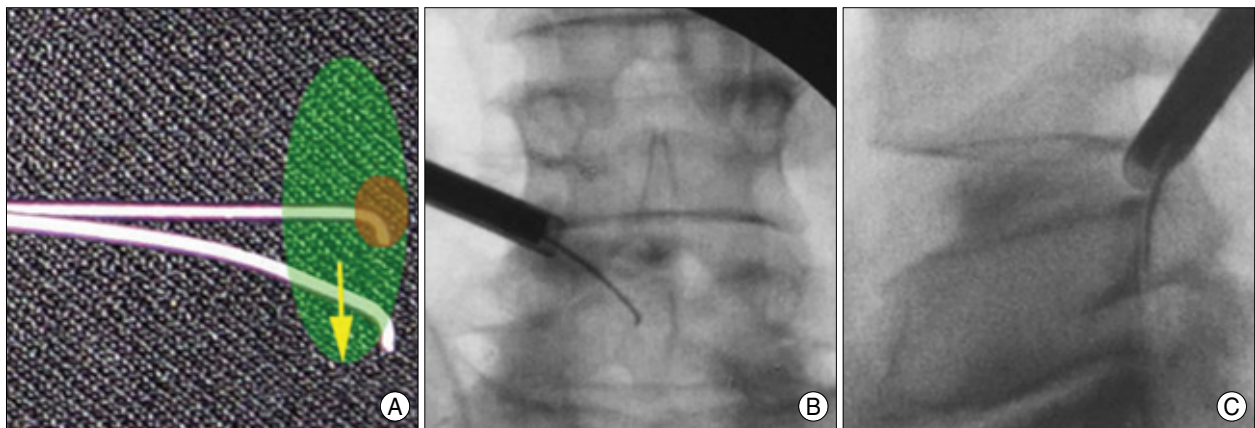


Fig. 2. A semi-rigid flexible curved probe (RZ Medizin Technik GmbH, Tuttlingen, Germany) is very useful to remove the far downward migrated disc material. A : A semi-rigid flexible curved probe can widen the range of reach to the migrated disc fragment and it is used to hook and pull out the disc fragment by manipulation of a rotation probe under an endoscope (green area). B and C : Manipulated probe is projected from just above the pedicle of L5 to the inferior-migrated disc area and the probe tip reaching the inferior margin of the pedicle of the lower vertebra, L5.

good, 2.5 points fair, whereas change of less than 2.5 points was considered poor.

RESULTS

A total of 53 patients were operated on during the period between May 2006 and March 2008 for high grade inferior-migrated disc herniation with the transforaminal supra-

pedicular endoscopic technique. There were 28 male and 25 female patients. The age distribution of patients is as follows : adolescence (1), 20s (6), 30s (8), 40s (11), 50s (13), 60s (9), and 70s (5). The L2-3 level was involved in 2 patients. The L3-4 level was involved in 12 patients, while the L4-5 level was involved in 39 patients. The preoperative MRI and 3D CT with discogram images showed a single piece-type in 34 cases and a multiple piece-type in 19 cases. One patient

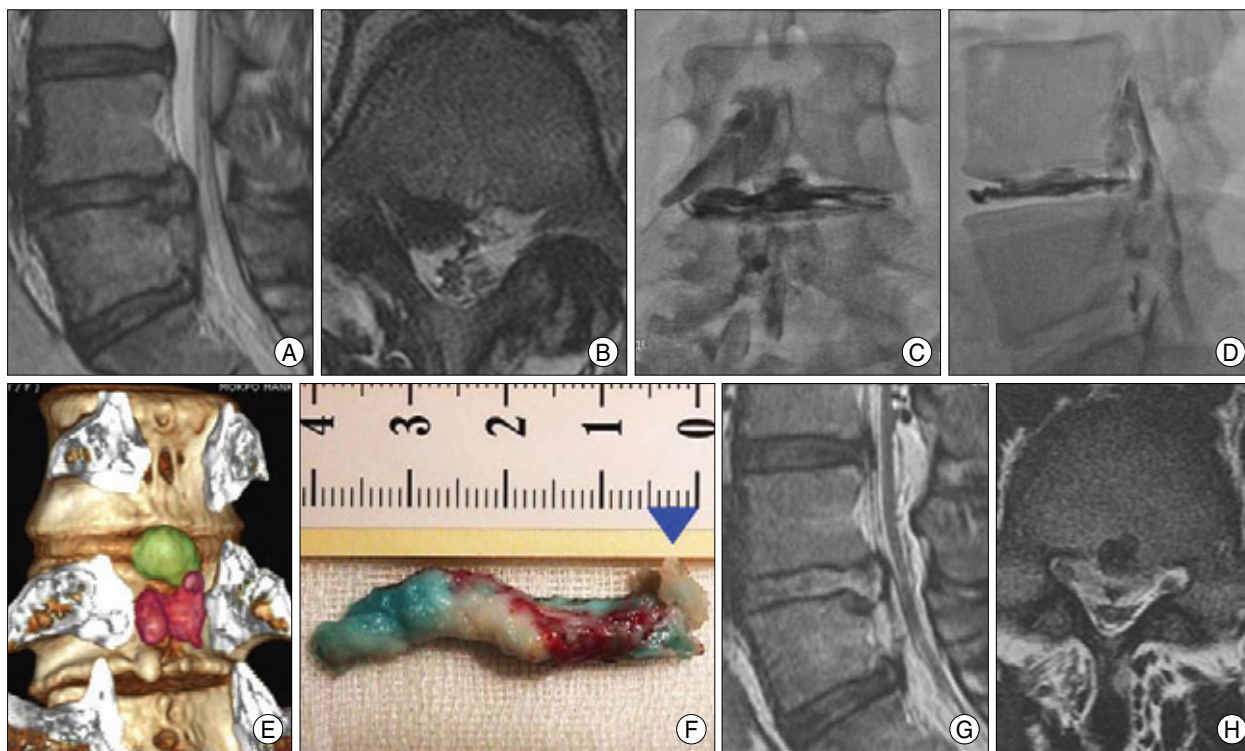


Fig. 3. High grade inferior-sequestered disc type. Preoperative magnetic resonance (MR) image showing a large, high grade inferior-ruptured sequestered disc material (A and B). Preoperative discography shows dye leaks through the ruptured disc to the epidural space (C and D). There is a single piece of fragment on the disco-computed tomography image (E), even though it looks like multiple ruptured fragments on the preoperative MR image (A and B). Because it is possible to grasp the site of the stalk precisely (I and J : blue arrow), it can be removed sufficiently by the endoscope (G and H).

Table 1. Results of the suprapedicular approach in high grade inferior-migrated lumbar disc

Level	Age							Total	Type			Results			
	10'	20'	30'	40'	50'	60'	70'		single	multiple	Excellent	Good	Fair	Poor	
L2-L3	0	0	0	0	1	1	0	2	2	0	1	1	0	0	
L3-L4	0	2	2	2	3	2	4	12	8	4	6	5	1	0	
L4-L5	1	4	6	9	9	6	5	39	24	15	21	16	1	1	
Total	1	6	8	11	13	9	5	53	34	19	28	22	2	1	

required conversion to an open surgery because of a large, ruptured, hard component disc not extracted from the epidural space. One patient had a fair result and 1 patient had a poor result at the 6 month follow-up (Table 1). Seven patients complained of paresthesias in the previous painful area, 2 patients complained of paraparesis transiently, but their symptoms resolved completely during the ensuing 4 weeks of observation. The operative times ranged from 30-150 minutes, with a mean operative time of 90 minutes.

The mean preoperative VAS for leg pain was 9.32 ± 0.43 points (range, 7-10 points), whereas the mean preoperative ODI was 79.82 ± 4.53 points (range, 68-92 points). At the last follow-up examination, after an average period of 6 months, the mean postoperative VAS for the leg pain was 1.78 ± 0.71 points (range, 1-3 points) and the mean postoperative ODI improved 15.27 ± 3.82 points (range, 8-22 points; Table 1). The mean hospital stay was 32 hours

(range, 8-72 hours). The postoperative MRI results showed that 42 patients (79%) had near-total disc removal. Postoperative residual disc remnants existed in 7 patients; however, a very small fragment did not cause symptoms, and they were satisfied with the

surgical results. The mean follow-up period was 9.84 months. Seven patients (13%) developed dysesthesias in the lower extremities in a dermatomal distribution that was different from the preoperative radiating pain, but the dysesthesias were transient and improved over 4 weeks. During this period, no patients developed recurrent disc herniation on the same side. There were no occurrences of infections, discitides, pareses, dural tears, vascular injuries, or systemic complications.

DISCUSSION

Recently, numerous studies involving endoscopic discectomy have been reported, and the outcomes have been improving gradually^{1,6,10,12,18,20,21,25,26,30,41,44,46,48}. The incidence of complications after endoscopic lumbar discectomy is low^{10,14,36}. Lumbar discectomy has many advantages over

minimally invasive procedures : by dispensing the possibility of resection of bone and ligament and performing selective evacuation of the intervertebral space, surgery-induced instabilities can be prevented^{5,8,16,19,23,24,27,33-35,49,50}. In addition, lumbar discectomy is less traumatizing, the operative time is shorter, scarring can be avoided, and the intact intra-epidural lubricant structures, such as epidural fat and yellow ligaments, can be conserved. Post-discectomy syndrome or other deteriorations associated with surgery do not develop, and revision surgery is easier. Epidural scarring develops in more than 10% of patients after conventional laminectomy and discectomy^{4,13,28,29,40,42}. However, in posterolateral endoscopic discectomy, such scar were not detected by MRI or revision surgery²¹. Therefore, subsequent endoscopic or conventional procedures are possible^{37,39}. In comparison with microscopic discectomy, endoscopic discectomy do not need general anesthesia and there are many advantages, such as less complications and morbidity in the elderly, shorter hospital stays, faster rehabilitation, earlier return to work or sports, and thus higher patient satisfaction^{11,43}. Despite such numerous advantages, endoscopic discectomy has not been universally adopted because of the steep learning curve. In comparison with microscopic discectomy, surgical outcomes after endoscopic discectomy are not considered better and the indications are limited. Lateral approach endoscopic discectomy has many restrictions due to anatomic limitations, and the approach is through the iliac wing; thus, the iliac wing and the height of the working disc space should be adequate⁴⁵ and the working disc space must be approached through the foraminal space, which is difficult¹⁰. Also, the approach in high grade migration and high canal compromise cases is difficult with a rigid endoscope²⁶. In other words, due to anatomic reasons, the indications for endoscopic surgery is limited and it is relatively contraindicated for non-contained high grade canal compromise or migration type cases^{25,26}. Lee et al.²⁶ analyzed 55 failed cases among 1,586 cases of endoscopic discectomy, and the possibility of failure was increased in high grade migration and high canal compromise-type cases; thus, they suggested that open surgery should be performed. Ruetten et al.⁴¹ reported that in lateral endoscopic lumbar discectomy, for complete removal of the prolapsed disc, the epidural lesion is difficult to remove through the annulus defect using a retrograde approach, and thus direct visualization is required, therefore they utilized an extreme lateral access. It was difficult to remove the ruptured disc material by extreme lateral access, especially in cranial cases exceeding the lower edge of pedicle, and in caudal cases, exceeding the middle of the

pedicle. Lee et al.²⁵ divided the level of disc migration by 4 grades, and among them, satisfactory results in the cases of the far-downward migrated type (zone 4) were merely 78.9%. According to Ditsworth,¹⁰ it has been reported that despite endoscopic transforaminal lumbar discectomy having numerous advantages and showing good surgical results, it has several shortcomings; surgical manipulation is not easy, and thus it is possible to remove only a portion of the extruded disc, resulting in a lower success rate (83%). To overcome such limitations, it is important to understand the anatomic relationship of the disc and adjacent structures prior to surgery^{17,22,43}. To solve such problem in endoscopic discectomy by a lateral approach, it is necessary to understand the location in relation to the stalk of the ruptured disc and rest particles and the fragment level of the ruptured disc, and to obtain the volume of the lesion site and information on 3-dimensional imaging. We solved these problems by performing a discogram with 3D reconstruction CT (Fig. 3)¹⁰.

In the cases of high grade inferior migration-type lumbar disc herniation, the success rate of endoscopic discectomy is low^{25,26} because the endoscopic access to the lesion was interrupted by anatomic structures and a rigid endoscope, and a probe could not reach the lesion. Some surgeons reported that other methods, such as the extreme lateral access⁴¹ and epiduroscopic approach²⁵ and flexible working channel scope could solve such problems¹⁰. The transforaminal suprapedicular approach is a method to remove the migrated disc through the foraminal narrow space above the pedicle of the lower vertebra. The transforaminal suprapedicular approach has several advantages. The manipulation is performed at the foraminal level and thus it could have a sufficient angle to reach the migrated disc, the epidural space could be approached readily, and sufficient assessment of root decompression and disc extraction is feasible (Fig. 2). If a working cannula is installed in the disc space and subsequently the cannula is moved to the upper margin of the lower vertebral pedicle, the surrounding soft tissues can be clearly arranged by a high voltage bipolar probe manufactured by Ellman (Ellman Innovation, New York, USA), forceps. The suprapedicular entry space can be prepared (Fig. 1C and D). Through this route, the inferior-migrated disc material can be extracted by performing an epiduroscopic approach with the use of a semi-rigid flexible curved probe.

CONCLUSION

It is difficult to remove the disc fragment successfully in the high grade inferior migrated lumbar disc herniation by

posterolateral approach using rigid endoscope. However, satisfactory results could be obtained by applying transforaminal suprapedicular approach and using semi-rigid flexible curved probe.

• Acknowledgements

This paper was supported by research fund from Chosun University in 2007.

References

1. Ahn Y, Lee SH, Park WM, Lee HY, Shin SW, Kang HY : Percutaneous endoscopic lumbar discectomy for recurrent disc herniation : surgical technique, outcome, and prognostic factors of 43 consecutive cases. *Spine* 29 : E326-E332, 2004
2. Andrews DW, Lavyne MH : Retrospective analysis of microsurgical and standard lumbar discectomy. *Spine* 15 : 329-335, 1990
3. Asch HL, Lewis PJ, Moreland DB, Egnatchik JG, Yu YJ, Clabeaux DE, et al : Prospective multiple outcomes study of outpatient lumbar microdiscectomy : should 75 to 80% success rates be the norm? *J Neurosurg (1 Suppl)* 96 : 34-44, 2002
4. BenDebba M, Augustus van Alphen H, Long DM : Association between peridural scar and activity-related pain after lumbar discectomy. *Neurol Res (Suppl 1)* 21 : S37-S42, 1999
5. Calisaneler T, Ozdemir O, Karadeli E, Altinors N : Six months post-operative clinical and 24 hour post-operative MRI examinations after nucleoplasty with radiofrequency energy. *Acta Neurochir (Wien)* 149 : 495-500; discussion 500, 2007
6. Choi G, Lee SH, Bhanot A, Raiturker PP, Chae YS : Percutaneous endoscopic discectomy for extraforaminal lumbar disc herniations : extraforaminal targeted fragmentectomy technique using working channel endoscope. *Spine* 32 : E93-E99, 2007
7. Choi G, Lee SH, Raiturker PP, Lee S, Chae YS : Percutaneous endoscopic interlaminar discectomy for intracanalicular disc herniations at L5-S1 using a rigid working channel endoscope. *Neurosurgery (1 Suppl)* 58 : ONS59-68; discussion ONS59-68, 2006
8. Couto JM, Castilho EA, Menezes PR : Chemonucleolysis in lumbar disc herniation : a meta-analysis. *Clinics* 62 : 175-180, 2007
9. Demirel CB, Kalayci M, Ozkocak I, Altunkaya H, Ozer Y, Acikgoz B : A prospective randomized study comparing perioperative outcome variables after epidural or general anesthesia for lumbar disc surgery. *J Neurosurg Anesthesiol* 15 : 185-192, 2003
10. Ditsworth DA : Endoscopic transforaminal lumbar discectomy and reconfiguration : a postero-lateral approach into the spinal canal. *Surg Neurol* 49 : 588-597; discussion 597-598, 1998
11. Donceel P, Du Bois M : Fitness for work after lumbar disc herniation : a retrospective study. *Eur Spine J* 7 : 29-35, 1998
12. Eustacchio S, Flaschka G, Trummer M, Fuchs I, Unger F : Endoscopic percutaneous transforaminal treatment for herniated lumbar discs. *Acta Neurochir (Wien)* 144 : 997-1004; discussion 1003-1004, 2002
13. Fritsch EW, Heisel J, Rupp S : The failed back surgery syndrome : Reasons, intraoperative findings and long term results : a report of 182 operative treatments. *Spine* 21 : 626-633, 1996
14. Gill K : Retroperitoneal bleeding after automated percutaneous lumbar discectomy-a case report. *Spine* 15 : 1376-1377, 1990
15. Greenbarg PE, Brown MD, Pallares VS, Tompkins JS, Mann NH : Epidural anesthesia for lumbar spine surgery. *J Spinal Disord* 1 : 139-143, 1988
16. Halldin K, Zoega B, Karrholm J, Lind BI, Nyberg P : Is increased segmental motion early after lumbar discectomy related to poor clinical outcome 5 years later? *Int Orthop* 29 : 260-264, 2005
17. Halldin K, Zoega B, Lind B, Cederlund CG : Clinical application of a new three-dimensional radiological classification of lumbar disc herniations. *Ups J Med Sci* 110 : 159-165, 2005
18. Jang JS, An SH, Lee SH : Transforaminal percutaneous endoscopic discectomy in the treatment of foraminal and extraforaminal lumbar disc herniations. *J Spinal Disord Tech* 19 : 338-343, 2006
19. Kambin P, Cohen LF, Brooks M, Schaffer JL : Development of degenerative spondylosis of the lumbar spine after partial discectomy : Comparison of laminotomy, discectomy and posterolateral discectomy. *Spine* 20 : 599-607, 1995
20. Kambin P, NASS : Arthroscopic microdiscectomy. *Spine J (3 Suppl)* 3 : 60S-64S, 2003
21. Kambin P, Savitz MH : Arthroscopic microdiscectomy : an alternative to open disc surgery. *Mt Sinai J Med* 67 : 283-287, 2000
22. Knop-Jergas BM, Zucherman JF, Hsu KY, DeLong B : Anatomic position of a herniated nucleus pulposus predicts the outcome of lumbar discectomy. *J Spinal Disord* 9 : 246-250, 1996
23. Kotilainen E : Long-term outcome of patients suffering from clinical instability after microsurgical treatment of lumbar disc herniation. *Acta Neurochir (Wien)* 140 : 120-125, 1998
24. Kotilainen E, Valtonen S : Clinical instability of the lumbar spine after microdiscectomy. *Acta Neurochir (Wien)* 125 : 120-126, 1993
25. Lee S, Kim SK, Lee SH, Kim WJ, Choi WC, Choi G, et al : Percutaneous endoscopic lumbar discectomy for migrated disc herniation : classification of disc migration and surgical approaches. *Eur Spine J* 16 : 431-437, 2007
26. Lee SH, Kang BU, Ahn Y, Choi G, Choi YG, Ahn KU, et al : Operative failure of percutaneous endoscopic lumbar discectomy : a radiologic analysis of 55 Cases. *Spine* 31 : E285-E290, 2006
27. Lee SH, Seo KS, Kazala K, Kim BJ, Kim MJ : Efficacy of IDET for relief of leg pain associated with discogenic low back pain. *Pain Pract* 4 : 281-285, 2004
28. Lewis PJ, Weir BK, Broad RW, Grace MG : Long-term prospective study of lumbosacral discectomy. *J Neurosurg* 67 : 49-53, 1987
29. Maroon JC, Abla A, Bost J : Association between peridural scar and persistent low back pain after lumbar discectomy. *Neurol Res (Suppl 1)* 21 : S43-S46, 1999
30. Mayer HM, Brock M : Percutaneous endoscopic discectomy : surgical technique and preliminary results compared to microsurgical discectomy. *J Neurosurg* 78 : 216-225, 1993
31. McCulloch JA : *Principles of Microsurgery for Lumbar Disc Diseases*. New York, NY : Raven Press; 1989
32. McLain RF, Kalfas I, Bell GR, Tetzlaff JE, Yoon HJ, Rana M : Comparison of spinal and general anesthesia in lumbar laminectomy surgery: a case-controlled analysis of 400 patients. *J Neurosurg Spine* 2 : 17-22, 2005
33. Mekhail N, Kapural L : Intradiscal thermal annuloplasty for discogenic pain: an outcome study. *Pain Pract* 4 : 84-90, 2004
34. Mochida J, Nishimura K, Nomura T, Toh E, Chiba M : The importance of preserving disc structure in surgical approaches to lumbar disc herniation. *Spine* 21 : 1556-1563; discussion 1563-1564, 1996
35. Mochida J, Toh E, Nomura T, Nishimura K : The risks and benefits of percutaneous nucleotomy for lumbar disc herniation. A 10-year longitudinal study. *J Bone Joint Surg Br* 83 : 501-505, 2001
36. Onik G, Mooney V, Maroon JC, Wiltse L, Helms C, Schweigel, et al : Automated percutaneous discectomy : a prospective multi-institutional study. *Neurosurgery* 26 : 228-232; discussion 232-233, 1990
37. Ozer AF, Oktenoglu T, Sasani M, Bozkus H, Canbulat N,

- Karaarslan E, et al : Preserving the ligamentum flavum in lumbar discectomy: a new technique that prevents scar tissue formation in the first 6 months postsurgery. *Neurosurgery* (1 Suppl 1) 59 : ONS126-133; discussion ONS126-133, 2006
38. Papadopoulos EC, Girardi FP, Sama A, Pappou IP, Urban MK, Cammisa FP Jr : Lumbar microdiscectomy under epidural anesthesia : a comparison study. *Spine J* 6 : 561-564, 2006
 39. Park YK, Kim JH, Chung HS : Outcome analysis of patients after ligament-sparing microdiscectomy for lumbar disc herniation. *Neurosurg Focus* 13 : E4, 2002
 40. Ross JS, Robertson JT, Frederickson RC, Petrie JL, Obuchowski N, Modic MT, et al : Association between peridural scar and recurrent radicular pain after lumbar discectomy : magnetic resonance evaluation. ADCON-L European Study Group. *Neurosurgery* 38 : 855-861; discussion 861-863, 1996
 41. Ruetten S, Komp M, Godolias G : An extreme lateral access for the surgery of lumbar disc herniations inside the spinal canal using the full-endoscopic uniportal transforaminal approach-technique and prospective results of 463 patients. *Spine* 30 : 2570-2578, 2005
 42. Ruetten S, Meyer O, Godolias G : [Epiduroscopic diagnosis and treatment of epidural adhesions in chronic back pain syndrome of patients with previous surgical treatment : first results of 31 interventions.] *Z Orthop Ihre Grenzgeb* 140 : 171-175, 2002
 43. Segnarbieux F, Van de Kelft E, Candon E, Bitoun J, Frerebeau P : Disco-computed tomography in extraforaminal and foraminal lumbar disc herniation : influence on surgical approaches. *Neurosurgery* 34 : 643-647; discussion 648, 1994
 44. Tomecek FJ, Anthony CS, Boxell C, Warren J : Discography interpretation and techniques in the lumbar spine. *Neurosurg Focus* 13 : E13, 2002
 45. Tsou PM, Alan Yeung C, Yeung AT : Posterolateral transforaminal selective endoscopic discectomy and thermal annuloplasty for chronic lumbar discogenic pain : a minimal access visualized intradiscal surgical procedure. *Spine J* 4 : 564-573, 2004
 46. Tsou PM, Yeung AT : Transforaminal endoscopic decompression for radiculopathy secondary to intracanal noncontained lumbar disc herniations : outcome and technique. *Spine J* 2 : 41-48, 2002
 47. Williams RW : Microlumbar discectomy. A 12-year statistical review. *Spine* 11 : 851-852, 1986
 48. Wu X, Zhuang S, Mao Z, Chen H : Microendoscopic discectomy for lumbar disc herniation: surgical technique and outcome in 873 consecutive cases. *Spine* 31 : 2689-2694, 2006
 49. Yeung AT, Tsou PM : Posterolateral endoscopic excision for lumbar disc herniation. Surgical technique, outcome, and complications in 307 consecutive cases. *Spine* 27 : 722-731, 2002
 50. Zander T, Rohlmann A, Klöckner C, Bergmann G : Influence of graded facetectomy and laminectomy on spinal biomechanics. *Eur Spine J* 12 : 427-434, 2003