

## Case Report

# Spinal Cord Stimulation for Intractable Visceral Pain due to Chronic Pancreatitis

Jin Kyung Kim, M.D.,<sup>1</sup> Seok Ho Hong, M.D.,<sup>1</sup> Myung-Hwan Kim, M.D.,<sup>2</sup> Jung-Kyo Lee, M.D.<sup>1</sup>

Departments of Neurosurgery,<sup>1</sup> Gastroenterology,<sup>2</sup> Asan Medical Center, University of Ulsan College of Medicine, Seoul, Korea

Pain caused by chronic pancreatitis is medically intractable and resistant to conventional interventional or surgical treatment. We report a case of spinal cord stimulation (SCS) for intractable pain due to chronic pancreatitis. The patient had a history of nonalcoholic chronic pancreatitis and multiple emergency room visits as well as repeated hospitalization including multiple nerve block and morphine injection for 3 years. We implanted surgical lead at T6-8 level on this patient after successful trial of percutaneous electrode. The patient experienced a decreased visual analog scale (VAS) scores for pain intensity and amount of opioid intake. The patient was followed for more than 14 months with good outcome and no further hospitalization. From our clinical case, spinal cord stimulation on intractable pain due to chronic pancreatitis revealed moderate pain control outcome. We suggest that SCS is an effective, noninvasive treatment option for abdominal visceral pain. Further studies and long term follow-up are needed to fully understand the effect of SCS on abdominal visceral pain.

**KEY WORDS :** Visceral pain · Spinal cord stimulation · Chronic pancreatitis.

## INTRODUCTION

A disorder that is singularly resistant to celiac plexus block is chronic pancreatitis. This has been a puzzle to pain management specialists for many years. Because the pain of pancreatic carcinoma usually responds dramatically to celiac plexus blockade, it would seem logical that chronic pancreatitis should respond well. Oddly enough, patients with chronic pancreatitis, no matter what the cause, usually get no relief or very brief or partial relief from celiac plexus block<sup>14</sup>. Recent studies have demonstrated significant involvement of dorsal column pathways in transmission of visceral pain syndrome<sup>3-5</sup>. Application of spinal cord stimulation (SCS) for the neuropathic pain, such as failed back surgery syndrome, angina pectoris, peripheral nerve injury pain, causalgia, reflex sympathetic dystrophy have been shown good outcome<sup>3-5,7,8,16</sup>. In addition, spinal cord stimulation suppresses visceral response to colon distension

in an animal model<sup>3,12,13,16</sup>. Case series in the literature report an effective outcome of SCS on intractable visceral pain<sup>3-5,16</sup>.

In this paper we present that SCS treatment could be the alternative option for intractable visceral pain due to chronic pancreatitis.

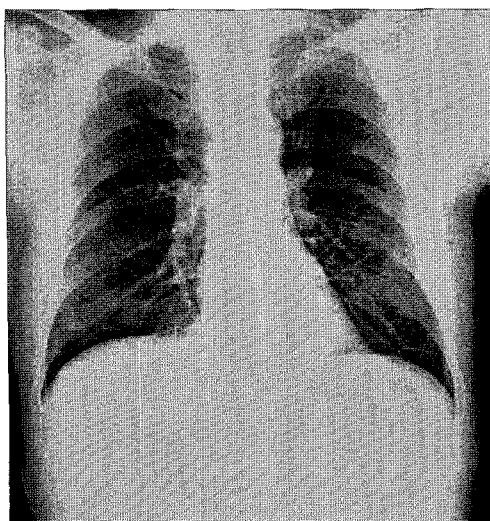
## CASE REPORT

A 51-year-old man presented with 3 years history of abdominal pain with diffuse upper thoracic area. The patient had a history of nonalcoholic chronic pancreatitis, cholecystitis, multiple emergency room visits and repeated hospitalization, including multiple abdominal work-ups, endoscopic retrograde cholangiopancreatographies and biliary internal stent insertion. Pain control could not be achieved medically or by other interventional procedures. Medications included intravenous injection of 10 mg of morphine every 12 hrs, 60 mg of oxycotin peroral, intravenous injection of 50 mg of pethidine every 6 hrs, fentanyl citrate patch, intravenous injection of 50 mg of tridol every 6 hrs, 370 mg of talniflumate (somalgen) every 8 hrs peroral and 20 mg of amitriptyline. These drugs could not reduce pain intensity sufficiently. Nerve block was performed twice with no significant result. The patient suffered from squee-

• Received : December 17, 2008 • Revised : February 11, 2009  
• Accepted : August 4, 2009  
• Address for reprints : Jung-Kyo Lee, M.D. Ph.D.  
Department of Neurosurgery, Asan Medical Center, University of Ulsan  
College of Medicine, 388-1 Pungnap 2-dong, Songpa-gu, Seoul  
138-736, Korea  
Tel : +82-2-3010-3553, Fax : +82-2-476-6738  
E-mail : jklee@amc.seoul.kr

zing epigastric pain that was either intermittent or continuous. Although these were treatment trials, pain scores were displayed at 7-10 point in VAS score. In Korean McGill Pain Questionnaire, pain rating index (PRI) was rated at 44/75 and present pain intensity score (PPI) was rated at 5/5. Functional disability was rated at 45/70 according to Korean Brief Pain Inventory.

The relatively non-invasive and non-destructive method is preferred as the first choice of pain treatment. Therefore, he underwent a SCS trial with placement of a eight-electrode percutaneous lead (Octrode lead, Advanced Neuromodulation Systems, Plano, TX, USA) at the midline of T7-8 level. The stimulation parameters were pulse width of 500-microsec, amplitude of 2.3 mA and frequency of 60 Hz. During trial, the patient reported excellent coverage of his usual pain and using temporal leads had excellent pain control. In order to prevent migration of electrode, a surgical permanent electrode (Lamitrode 88C Lead, Advanced Neuromodulation Systems, Plano, TX, USA) was placed at T6-8 after total laminectomy of T7 (Fig. 1). The patient experienced a decrease in VAS scores for pain intensity, amount of opioid consumed and other pain medications intake. There was a gradual reduction in preoperative pain medication intake. There was no considerable change in the parameter during the follow-up period. Postoperative medication included 30 mg of oxycontin at last follow up. The patient was followed up for more than 14 months, and he presented good outcome without complication. Pain scores decreased, from 10/10 to 5/10 in VAS, from 44/75 to 36/75 in PRI and from 45/70 to 42/70 in functional disability. He was a white-collar worker. He returned back to his work without further hospitalization.



**Fig. 1.** Anteroposterior radiograph showing a surgical permanent electrode (Lamitrode 88C Lead, Advanced Neuromodulation Systems, Plano, TX, USA) at T6-8 after total laminectomy of T7.

## DISCUSSION

The visceral pain is originated from damage or injury of internal organ, such as thorax, abdomen and pelvis<sup>4,5,12,16</sup>. Most cases cannot even be clearly explained the characteristics of pain, which is considered to be deep, dull and vague sensation. The visceral pain afferents receive the signal through the sympathetic and parasympathetic system, and the signal travels to the spinal cord and higher cortical centers<sup>3,5</sup>. The sympathetic pain pathway, which carry nociceptive information in small fiber, can be blocked by SCS<sup>3,5,11</sup>.

However, recent evidence indicates that chronic visceral pain may, in fact, not be nociceptive in nature, but a neuropathic pain syndrome. As the treatment method of intractable pain, SCS has been developed on basis of the gate control theory<sup>5,7-9,13,15</sup>. SCS has been employed for visceral pain due to pancreatitis, endometriosis and irritable bowel syndrome<sup>3-5,16</sup>. The mechanism of pain relief by SCS still remains unclear. However, the gate control theory of pain is widely accepted among many mechanism theories. According to this theory, cell associated with central transmission of pain in DC is controlled by the afferent activity of large-fiber or small-fiber in the peripheral nerve system<sup>9</sup>. This gate closes when an excess of large-fiber activity. The other theoretical basis of mechanisms in SCS include neural conduction blockade, activation of putative supraspinal pain centers, supraspinal or intraspinal sympathetic blockade and release of putative neuromodulators<sup>3,5-8,15</sup>.

DC lesion leads to decrease activation of thalamic and gracile neurons by visceral stimuli and to prevent potentiation of visceromotor reflex evoked by colorectal distention under inflammatory conditions in animal model experiments<sup>3,12,13</sup>. Pain control through SCS may mediate direct effects on DC lesion. Kapural et al.<sup>3,4</sup> reported one case and 6 case-series published efficacy of SCS on various visceral pains. Tiede et al.<sup>16</sup> applied SCS on two visceral pain patients and obtained good outcomes.

Nauta et al.<sup>10</sup> suggested that punctate midline myelotomy could control visceral pain. The theory is that there is an ascending midline dorsal column visceral pain pathway in humans and that its interruption may provide a way to relieve midline visceral pain syndrome. The benefit was probably derived not from the interruption of the crossing spinothalamic fibers but from the coincidental damage to the midline region of the dorsal columns<sup>10</sup>. That benefit could be regarded as a pain control mechanism of SCS for visceral pain. Both procedures could reduce pain via interruption of the spinothalamic fibers, but punctate midline myelotomy is an ablative procedure with the possibility of

moderate to severe complication. SCS is a less invasive procedure with minimal complications.

Krames et al.<sup>6</sup> suggested that chronic pain of visceral origin travels within the spinothalamic tracts and may be amplified by the postsynaptic dorsal column pathways. Thus, both procedures could be controlled at the spinal cord level by SCS and explain the efficacy of SCS for visceral painful disorder.

The incidence of chronic pancreatitis is reported to be approximately 13-75 cases per 100,000 patients per year<sup>1,2</sup>. In Korea, the exact prevalence is not known, but it is on the rise in Japan due to increased alcohol abuses. The characteristic pain of chronic pancreatitis is recurrent or permanent, and it leads to major socioeconomic problems such as narcotic addiction, physical and emotional disability<sup>1</sup>. In chronic pancreatitis, causes of sustained pain can be visceral inflammation, pancreatic ischemia, inflammatory injury to the nerve sheaths, and pancreatic-independent mechanism including plastic changes in the nervous system<sup>1,2</sup>. This pain has been difficult to be controlled medically or surgically and hypogastric plexus block has shown long term effect of only 10% patients<sup>3,4</sup>. There are only two articles regarding SCS treatment for chronic pancreatitis at present. The largest study was reported by Khan et al.<sup>5</sup> with five clinical cases. In this study, the target area was the T5-T6 level in the midline according to the dermatomal distribution of pain and its corresponding spinal levels. The pain relief for all patients achieved more than 50% and reduction of 4-5 point in VAS scores was observed 6-8 months after SCS. Kapural et al.<sup>4</sup> also presented the good outcome with reduction of 7 point in one patient. Their target area was same as Khan et al.<sup>5</sup> In our study, the patient was monitored for more than 10 months and presented a reduction of 4 point in VAS score without complication.

The most common complication of percutaneous SCS is electrode migration (11.7-21.5%)<sup>7,8,15</sup>. To prevent migration of electrode in percutaneous type, several methods were attempted such as combination with the each type of anchors such as short butterfly and long anchor and using the brace for immobilization during 4-6 weeks after operation. In contrast to percutaneous lead, surgical leads have technical advantages<sup>17</sup>. North et al.<sup>11</sup> showed a broader stimulation pattern and lower stimulation requirements of surgical electrodes. Also, surgical electrodes appeared to be associated with better long-term effectiveness. Other complications that have been reported with following incidences; hardware malfunction (8.1%), fractured electrode (2.9-5.9%), subcutaneous hematoma (4.4%), infection (3.4-3.9%), discomfort at the pulse generator site (1.2%), foreign body reaction (1%), rotation of the pulse generator (0.7%),

cerebrospinal fluid leak (0.5%)<sup>7,8,15</sup>.

## CONCLUSION

We report the application of SCS for the treatment option of intractable visceral pain. SCS can provide moderate pain relief with improved quality of life and less consumption of medication for patient with chronic pancreatitis.

## References

1. Dimcevski G, Sami SA, Funch-Jensen P, Le Pera D, Valeriani M, Arendt-Nielsen L, et al : Pain in chronic pancreatitis : the role of reorganization in the central nervous system. *Gastroenterology* 132 : 1546-1556, 2007
2. Fregni F, Pascual-Leone A, Freedman SD : Pain in chronic pancreatitis : a salutogenic mechanism or a maladaptive brain response? *Pancreatology* 7 : 411-422, 2007
3. Kapural L, Narouze SN, Janicki TI, Mekhail N : Spinal cord stimulation is an effective treatment for the chronic intractable visceral pelvic pain. *Pain Med* 7 : 440-443, 2006
4. Kapural L, Rakic M : Spinal cord stimulation for chronic visceral pain secondary to chronic non-alcoholic pancreatitis. *J Clin Gastroenterol* 42 : 750-751, 2008
5. Khan YN, Raza SS, Khan EA : Application of Spinal Cord Stimulation for the Treatment of Abdominal Visceral Pain Syndromes : Case Reports. *Neuromodulation* 8 : 14-27, 2005
6. Krames ES, Foreman R : Spinal Cord Stimulation Modulates Visceral Nociception and Hyperalgesia via the Spinothalamic Tracts and the Postsynaptic Dorsal Column Pathways : A Literature Review and Hypothesis. *Neuromodulation* 10 : 224-237, 2007
7. Kumar K, Hunter G, Demeria D : Spinal cord stimulation in treatment of chronic benign pain : challenges in treatment planning and present status, a 22-year experience. *Neurosurgery* 58 : 481-496; discussion 481-496, 2006
8. Lee AW, Pilitsis JG : Spinal cord stimulation : indications and outcomes. *Neurosurg Focus* 21 : E3, 2006
9. Melzack R, Wall PD : Pain mechanisms : a new theory. *Science* 150 : 971-979, 1965
10. Nauta HJ, Soukup VM, Fabian RH, Lin JT, Grady JJ, Williams CG, et al. : Punctate midline myelotomy for the relief of visceral cancer pain. *J Neurosurg* (2 Suppl) 92 : 125-130, 2000
11. North RB, Kidd DH, Olin JC, Sieracki JM : Spinal cord stimulation electrode design : prospective, randomized, controlled trial comparing percutaneous and laminectomy electrodes-part I : technical outcomes. *Neurosurgery* 51 : 381-389; discussion 389-390, 2002
12. Palecek J : The role of dorsal columns pathway in visceral pain. *Physiol Res* 53 Suppl 1 : S125-S130, 2004
13. Qin C, Lehw RT, Khan KA, Wienecke GM, Foreman RD : Spinal cord stimulation modulates intraspinal colorectal visceroreceptive transmission in rats. *Neurosci Res* 58 : 58-66, 2007
14. Stacey B, colantonio A, Vookles JL, Sibell D, Kulawiak L : Management of pain by anesthetic techniques, in Winn HR (ed) : *Youmans Neurological Surgery Fifth edition* : Saunders, 2004, Vol 3, p 2983
15. Sundaraj SR, Johnstone C, Noore F, Wynn P, Castro M : Spinal cord stimulation : a seven-year audit. *J Clin Neurosci* 12 : 264-270, 2005
16. Tiede JM, Ghazi SM, Lamer TJ, Obray JB : The use of spinal cord stimulation in refractory abdominal visceral pain: case reports and literature review. *Pain Pract* 6 : 197-202, 2006
17. Villavicencio AT, Leveque JC, Rubin L, Bulsara K, Gorecki JP : Laminectomy versus percutaneous electrode placement for spinal cord stimulation. *Neurosurgery* 46 : 399-405; discussion 405-406, 2000