

The Diameter of Maximum Distended Urethra in Male Dogs

Ye-Eun Byeon, Sun-Tae Lee, Oh-Kyeong Kweon and Wan-Hee Kim¹

Department of Veterinary Surgery, College of Veterinary Medicine, Seoul National University, Seoul 151-742, Korea.

(Accepted : August 18, 2009)

Abstract : This paper was performed to investigate the propensity of the diameter of maximum distended urethra from urethra to os penis in mature male dogs of 25 male dogs of different breeds. The measured sites of urethras were divided into 7 regions, i.e. prostate, membrane, isthmus, perineum, scrotum, prescrotum and os penis. By using the inflated balloon catheter filled with contrast medium, the maximum diameter of the distended urethras of each region was recorded and compared among regions. The mean diameter of the lumen from the prostatic urethra to the os penis urethra was gradually narrowed except for the isthmus portion, with a sense of resistance for retraction being noted at the level of ischiatic arch in 22 dogs. Proposed results from this should be utilized as a predictor of a treatment plan for the removal of urethroliths using an urohydropropulsion.

Key words : male dog, maximum urethra diameter, urethrolith, urohydropropulsion.

Introduction

Urinary tract obstruction, caused by the lodging of the uroliths in the urethra of male dogs, can be restored using various techniques including dissolution, lithotripsy, urohydropropulsion or surgical intervention like cystotomy and urethrotomy (2,5,12,14). Retrograde urohydropropulsion is a technique that utilizes fluid under pressure after dissolution and lithotripsy and causes a lower risk of iatrogenic trauma as compared to pushing a stone through the urethra with a catheter or urethrotomy (5,7,15).

On the urohydropropulsion procedure, the isolated segment of the urethra containing the uroliths under pressure is distended and the lodged urethroliths can then advance to the urinary bladder if the diameter of the urethra distends sufficiently. Its process generates huge pressure within the partial segment of the urethral lumen containing the urethroliths and increased distension of the urethral diameter than that of the normal urethra. The efficacy of this technique is thus related to the dilatation of a portion of the urethra containing urethroliths with fluid under pressure (15).

The present study attempted to create a similar condition of urohydropropulsion for partial urethral distension to its maximum capacity with hydrostatic pressure within the isolated segment of urethral lumen containing the uroliths. Under these conditions, the propensity of the diameter of maximum distended urethra from urethra to os penis in mature male dogs was investigated. It can be expected providing a predictor of fragmentation size during lithotripsy in various segments of the urinary tract. Furthermore, it can be also expected dem-

onstrating clinically applicable approach sites of surgery for the removal of urethroliths according to the size and site of urethroliths with or without dissolution.

Materials and Methods

Animals

Twenty-five mature male dogs of various breeds including ten Beagles, three Cocker spaniels, two Maltese, two Shih Tzu, two Yorkshire terriers, one Poodle, one Schnauzer and four crossbreeds were used for this study. The weight of the dogs ranged from 3.4 to 9.8 kg (mean 6.8 ± 6.7 kg). Eight dogs were older than 6 years. Four dogs were castrated while twenty one were intact. None of the animals had any lower urinary tract abnormalities. Before radiography, the dogs were allowed to fast for 12 hours.

Measurements of urethral diameters

The dogs were intravenously injected with cefazolin sodium (20 mg/kg, Cefazolin[®] injectable, Chong Kun Dang Pharm. Co., Korea) for prophylactic treatment and tramadol (4 mg/kg, Toranzine[®], Sam Sung Pharm. Co., Korea) for analgesia and preanesthetized with diazepam (0.5 mg/kg, Melode[®], Dong Hwa Pharm. Co., Korea) administered intravascularly. General anesthesia was induced with thiopental sodium (10 mg/kg, Thionyl[®] Dae Han Pharm. Co., Korea) and maintained with isoflurane (Forane[®] Sol., Choong Wae Pharma CO., Korea) and oxygen. All experiments were carried out the patients in accordance with the Institutional Animal Care and Use Committee (IACUC) of the Seoul National University.

The maximum distensible diameter of the balloon catheter (All-silicone Foley balloon catheter. 6 Fr, 1.5 cc, Sewoon Medical Co., Korea) used for this study was 1.6 ± 0.0 cm with

¹Corresponding author.
E-mail : whkim@snu.ac.kr

2.5 cc 50% diluted contrast medium. Before the catheter tip was advanced to the urinary bladder, the urinary bladder was to be empty and filled with 10% diluted contrast medium (Ultravist® 300 Schering) to confirm the site. Then the balloon was inflated with 50% diluted contrast medium. The urethra was subdivided into 7 parts to measure the maximum distensible diameter. These included the prostate, membrane, isthmus, perineum, scrotum, prescrotum and os penis (Fig 1). Fig 2 shows inflated balloon with contrast medium located in the urethra. The isthmus portion is the junction of the membranous urethra and root of the penile urethra at the level of the ischiatic arch with resistance for retraction of balloon catheter. Each urethral portion was distended using the balloon catheter with contrast medium until the inflated round shape balloon was appeared to be 'oval shape'.

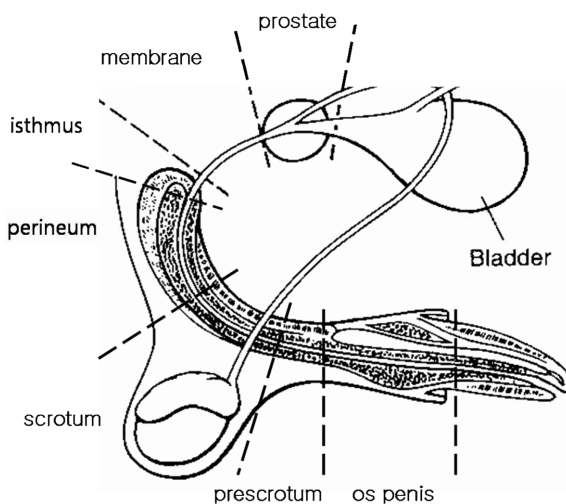


Fig 1. The urethra portion is divided into 7 parts. (Illustration from Fossum TW (modification): Surgery of the bladder and urethra. Mosby 2002).

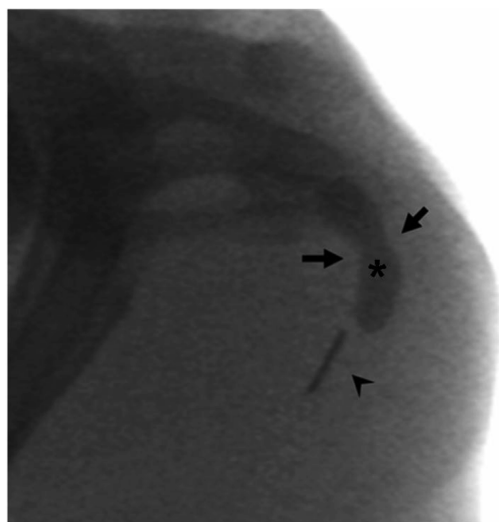


Fig 2. Asterisk indicates inflated balloon with contrast medium located in the urethra. Arrows indicates the isthmus portion. Arrowhead indicates 1-cm metallic strip.

The diameter of the distended urethral lumen was calculated using contrast image as observed by C - arm (KMC-950, Comed) in right lateral recumbency. The diameter of the urethra was measured at the middle of each portion. The results of the measurement of the urethral diameter were automatically displaced in the monitor as pixel units, which were then converted into centimeters (cm). A 1-cm metallic strip placed in the tip of the balloon catheter was included in each radiograph so that the magnification of the image could be calculated (Fig 2). Cephadrine® (20 mg/kg, Cephadrine capsule 500 mg, Choong Wae Pharm. Co., Korea) for prophylactic treatment were orally administered every 12 hours for 3 days after the measurement of the urethral diameter.

Histological evaluation

The organs of the lower urinary tract of 6 dogs, from the bladder to penis, were dissected en bloc with the surrounding tissue and confirmed grossly after euthanasia. To confirm the reason of the resistance for retraction of the isthmus portion, it was resected in the sagittal planes and fixed in 4% buffered formalin, embedded in paraffin and cut into 5-micrometer-thickness sections. The section was stained with H&E stain.

Statistical analysis

Statistical analysis for comparison of the differences in the urethral diameters depending on age (less than 6 years and more than 6 years), body weight (over 5 kg and less 5 kg) and gender (male and neutered male) were performed with Student t-test. Comparisons between each portion of the urethra in each factor were performed with ANOVA (analysis of variance) test using the SPSS 12.0 K for Windows. Post hoc comparisons were performed using Tukey's method to test the significance at a level of $P < 0.05$.

Results

No relevance of body weight, age and neutralization to the maximum distended diameters of urethra was observed in

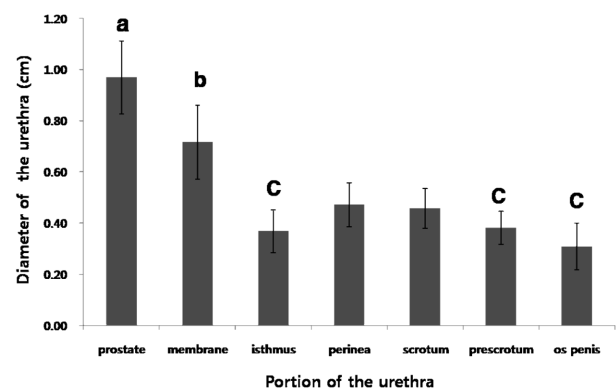


Fig 3. The mean maximum distended urethra diameter in 25 male dogs. The error bars at each point represent the standard deviation of the urethra diameter. a, b, c were significantly different with no relevance of body weight, age and neutralization ($P < 0.05$).

this study. The propensity of the maximum distended urethral diameter from the prostatic urethra to the os penis urethra is shown in Fig 3. The maximum distended diameters were found to be variable in each part but the prostatic urethra displayed the greatest diameter of all the portions of the urethra studied. The maximum distended diameter of prostatic, membranous, isthmus and perineal portions were significantly different ($P < 0.05$) and there were no differences of the diameters between isthmus, prescrotum and os penis portions.

In this investigation, the highest diameter of the maximum distended prostatic urethra was confirmed to be 1.32 cm. The maximum distended urethral lumen narrowed toward the os penis except isthmus portion between the membranous and perineal portion at the level of the ischiatic arch. This site was confirmed a sense of resistance during retraction in all the dogs in this study. The diameter of the lumen was narrower than both in the proximal portion (membranous urethra) and the distal portion (perineal urethra) in 22 of 25 dogs. The diameter of the isthmus portion of the remaining 3 dogs was found to be narrower than in the proximal portion but more distended in the distal portion.

In the gross and histological examination, the isthmus portion was found to be released when the corpus cavernosus penis was separated from the urethra at the dorsal region. The isthmus region was confirmed to be the root of the penis and the origin of the corpus cavernosum penis enveloped by a thick covering of collagenous and elastic fibers, the tunica albuginea (Fig 4(a), (b), (c)).

Discussion

Previous studies on retrograde urethrography have identified a significant variation in urethral diameter, especially in the prostatic urethra, depending on the degree of bladder distension. The technique used in previous studies was maximum distension retrograde urethrography (MDRU) where the bladder was pre-distended and the vesicourethral junction distended, during radiography (6,9,17). The finding that the maximum distension of the prostatic urethra in this study has a greater diameter than the membranous urethra is consistent with previous reports (6).

Smooth muscle is present throughout the length of the urethra, and striated muscle is present in the walls of the distal two thirds of the urethra of the male dog (3,4). The submucosa of the prostatic portion contains abundant elastic fibers while the membranous urethra, which runs from the apex of the prostate to the start of the penis in males, contains some smooth but mostly striated muscle. Thus when the intraluminal pressure increases, great distension of urethral lumen in pelvic portions occurs (4,19). In contrast to this, the root of penis enveloped by a thick covering of collagenous and elastic fibers, the tunica albuginea. Especially, isthmus portion with restriction of distension between the membranous and perineal area was confirmed the junction of this anatomical structure and the diameter of the lumen in this area was narrower than both membranous and perineal portions in 22 of 25 dogs. In male dogs, uroliths most often lodge at the ischiatic arch or immediately caudal to the os penis (1,15). Restricted distension of os penis urethra is due to os penis and the reason of the often lodgment of uroliths. Isthmus portion is likewise restricted of distension by insertion of the root of penis, tunica albuginea. This could be suggested the reason of the often lodgment of uroliths at the ischiatic arch.

Lower urinary tract function morphologically and physiologically changes significantly according to age and gender. Benign prostatic hypertrophy (BPH) is commonly seen in dogs of over 6 years old (18) and this may affect the results of this study, however, our results was confirmed there was no significantly differences between less than 6 years group (17 dogs) and over than 6 years (8 dogs) in each portion of urethra. In addition, recent report has revealed the proportion of collagen increases and the proportion of muscle decreases following gonadectomy and collagen accumulation is suggested to cause stiffness and this may adversely affect the maximum distension of the male urethra (16). In this study, no difference was confirmed between neutered dogs and intact dogs but further study is needed on a larger sample of dogs because only 4 neutered males were contained in this study.

Our study had limitations of using healthy dogs with no stones and no chronic mucosal damage that could have narrowed the urethral diameter but the results obtained from this study imply that if the urethroliths are not as large as the

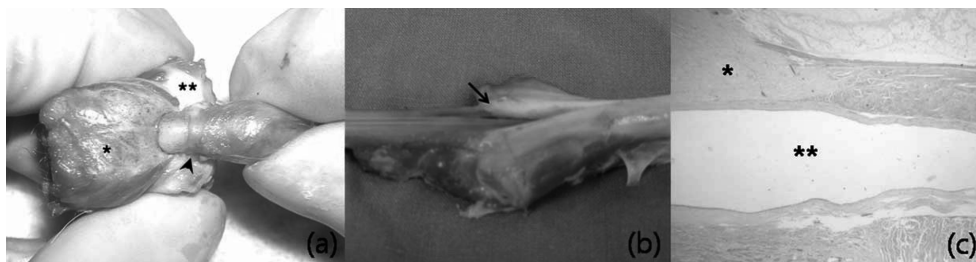


Fig 4. (a) The gross appearance of the isthmus portion with balloon catheter. *: bulbospongiosus muscle, **: corpus cavernosum, Arrow head: isthmus portion with resistance of balloon inflation. (b) The gross appearance of isthmus portion in sagittal view. Arrow indicates the origin of the corpus cavernosum penis. (c) Histological examination of the isthmus portion in sagittal resection ($\times 400$). The urinary bladder is located on the right site. *: collagenous and elastic fibers, the tunica albuginea, **: lumen of the urethra.

diameter of the os penis urethra, all lodged uroliths can be successfully advanced back and forth by urohydropropulsion with adequate pressure and sufficient urethral dilation. Another limitation of the technique used in this study to measure the urethral distension, is that we will not achieve the same level of distension with the saline injection as with the balloon.

There are many ways to remove the uroliths in the male urethra. Narrowing of urethral lumen and excessive and unnecessary manipulation of urethra during restoring the urinary tract are possible cause of treatment failure (15). The results of this study could help to select candidates for lithotripsy as part of the procedures requiring voiding urohydropropulsion or clinically applicable approach sites of surgery for the removal of urethroliths according to the size and site of urethroliths and it could potentially minimize the injury of the urethral lumen.

Acknowledgements

This work was supported by the Research Institute for Veterinary Science of Seoul National University.

References

1. Bjorling DE, Hosgood G, Slatter D, Holmberg DL. The Urethra. In: Textbook of small animal surgery, 3rd ed. Philadelphia: Saunders. 2002; 1638-1651.
2. Caywood DD, Osborne CA. Surgical removal of canine uroliths. *Vet Clin North Am Small Anim Pract* 1986; 16: 389-407.
3. Creed KE, Van Der Werf BA, Kaye KW. Innervation of the striated muscle of the membranous urethra of the male dog. *J Urol* 1998; 159: 1712-1716.
4. Cullen WC, Fletcher TF, Bradley WE. Histology of the canine urethra II: Morphometry of the male pelvic urethra. *Anat Rec* 1981; 199: 187-195.
5. Davidson EB, Ritchey JW, Higbee RD, Michael D, Lucroy, Bartels KE. Laser Lithotripsy for Treatment of Canine Uroliths. *Vet Surg* 2004; 33: 56-61.
6. Feeney DA, Johnston GR, Osborne CA, Tomlinson MJ. Dimensions of the prostatic and membranous urethra in normal male dogs during maximum distension retrograde urethrocystography. *Vet Radiol Ultrasound* 1984; 25: 249-253.
7. Fossum TW, Hedlund CS, Hulse DA, Johnson AL. Surgery of the Bladder and Urethra. In: *Small Animal Surgery*, 2nd ed. Missouri: Mosby. 2002: 572-609.
8. Grant DC, Werre SR, Gevedon ML, Holmium: YAG laser lithotripsy for urolithiasis in Dogs. *J Vet Intern Med* 2008; 22: 534-539.
9. Johnston GR, Feeney DA, Osborne CA, Johnston SD, Smith FO, Jessen CR. Effects of intravesical hydrostatic pressure and volume on the distensibility of the canine prostatic portion of the urethra. *Am J Vet Res* 1985; 46: 748-751.
10. Johnston GR, Stevens JB, Jessen CR, Osborne CA. Effects of prolonged distention of retention catheters on the urethra of dogs and cats. *Am J Vet Res* 1983; 44: 223-228.
11. Lulich JP, Adams LG, Grant D, Albasan H, Osborne CA. Changing Paradigms in the Treatment of Uroliths by Lithotripsy. *Vet Clin North Am Small Anim Pract* 2009; 39: 143-160.
12. Lulich JP, Osborne CA, Carlson M, Unger, LK, Samelson LL, Koehler LA, et al. Nonsurgical removal of urocystoliths in dogs and cats by voiding urohydropropulsion. *J Am Vet Med Assoc* 1993; 203: 660-663.
13. Lulich JP, Osborne CA, Sanderson SL, Ulrich, LK, Koehler LA, Bird KA, et al. Voiding urohydropropulsion: Lessons from 5 years of experience. *Vet Clin North Am Small Anim Pract* 1999; 29: 283-291.
14. Osborne CA, Kruger JM, Johnston GR, Polzin DJ. Dissolution of canine ammonium urate uroliths. *Vet Clin North Am Small Anim Pract* 1986; 16: 375-388.
15. Osborne CA, Lulich JP, Polzin DJ. Canine retrograde urohydropropulsion: Lessons from 25 years of experience. *Vet Clin North Am Small Anim Pract* 1999; 29: 267-281.
16. Ponglowhapan S, Church DB, Khalid M. Differences in the proportion of collagen and muscle in the canine lower urinary tract with regard to gonadal status and gender. *Theriogenology* 2008; 70: 1516-1524.
17. Poogird W, Wood AK. Radiologic study of the canine urethra. *Am J Vet Res* 1986; 47: 2491-2497.
18. Smith J. Canine prostatic disease: A review of anatomy, pathology, diagnosis, and treatment. *Theriogenology* 2008; 70: 375-383.
19. Van Der Werf BA, Hidaka T, Creed KE. Continence and some properties of the urethral striated muscle of male greyhounds. *BJU Int* 2000; 85: 341-349.

수컷 개에서 최대 확장된 요도의 직경

변예은 · 이선태 · 권오경 · 김완희¹

서울대학교 수의과대학 수의외과학교실

요 약 : 25마리의 다양한 종의 수컷 개에서 전립선에서 음경끝까지 각 부위의 요도를 최대로 확장하여 측정 후 그 경향을 조사하였다. 전립선, 요도막, 협부, 회음부, 고환, 고환앞, 음경골 부위에 각각 풍선카테터를 위치한 후 풍선 내에 조영제를 주입하여 영상촬영 후 분석하였다. 협부를 제외하고 전립선에서부터 음경골로 갈수록 각 부위의 최대 확장된 직경은 점점 줄어들었다. 골반 부위 근처에 위치한 협부에서 카테터의 풍선을 전립선 부위와 회음부로 견인 시 25 마리 중 22마리의 개에서 강한 저항감이 있었고 직경 또한 원위부와 근위부의 직경보다 더 작았다. 이러한 결과는 요도를 확장시켜 요도 내 결석을 제거하는 수압추진법의 적용 계획을 세우는 데 기여할 것으로 사료된다.

주요어 : 수컷 개, 최대 확장 요도, 요도 결석, 수압추진법.