

# *Echinostoma hortense* and Heterophyid Metacercariae Encysted in Yellowfin Goby, *Acanthogobius flavimanus*, from Shinan-gun and Muan-gun (Jeollanam-do), Korea

Woon-Mok Sohn<sup>1,\*</sup>, Byoung-Kuk Na<sup>1</sup> and Shin-Hyeong Cho<sup>2</sup>

<sup>1</sup>Department of Parasitology and Institute of Health Sciences, Gyeongsang National University School of Medicine, Jinju 660-751, Korea;

<sup>2</sup>Department of Malaria and Parasitic Diseases, National Institute of Health, Korea Centers for Disease Control and Prevention, Seoul 122-701, Korea

**Abstract:** Fishborne trematode (FBT) metacercariae were investigated in yellowfin goby, *Acanthogobius flavimanus*, collected from Shinan-gun and Muan-gun, Jeollanam-do (province), Korea. All collected fishes were examined using the artificial digestion method. In all of 15 gobies from Aphae-myeon in Shinan-gun, metacercariae of *Stictodora* spp. (334 metacercariae/fish), *Heterophyes nocens* (153/fish), and *Heterophyopsis continua* (20/fish) were detected. In 2 of 14 gobies from Jido-myeon in Shinan-gun, 8 *Echinostoma hortense* metacercariae in total were detected. In 15 gobies from Haeje-myeon in Muan-gun, the metacercariae of *H. continua* were found in 100%, *Stictodora* spp. in 86.7%, and *H. nocens* in 6.7% of fish examined. The average numbers of metacercariae per infected fish were 23.3 (*H. continua*), 416.0 (*Stictodora* spp.), and 2.0 (*H. nocens*), respectively. The metacercariae of *E. hortense* found in gobies were elliptical, with 150 × 138 μm in average size, and had 27 collar spines on the head crown. The above results suggest that yellowfin gobies from 2 localities may be the potential infection sources of FBT. Moreover, it is proved for the first time that the yellowfin goby, *A. flavimanus*, acts as a second intermediate host for *E. hortense*.

**Key words:** *Echinostoma hortense*, heterophyids, fishborne trematode metacercariae, yellowfin goby, Shinan-gun, Muan-gun

More than 50 million people are currently estimated to be infected with intestinal trematodes, including at least 18 million people infected by fishborne trematodes (FBT) around the world. Heterophyid (Heterophyidae) and echinostomatid flukes (Echinostomatidae) are regarded as the most important groups found in the intestinal tract of humans [1,2]. With regard to heterophyids, 10 species in 7 genera, i.e. *Metagonimus yokogawai*, *Metagonimus takahashii*, *Metagonimus miyatai*, *Heterophyes nocens*, *Heterophyopsis continua*, *Stellantchasmus falcatus*, *Pygidiopsis summa*, *Centrocestus armatus*, *Stictodora fuscata*, and *Stictodora lari*, have been reported as human-infecting species in the Republic of Korea [2]. Among them, 6 species, namely, *H. nocens*, *H. continua*, *P. summa*, *S. falcatus*, *S. fuscata*, and *S. lari*, are infected by consumption of raw flesh of estuarine fish [1,2]. Among these fish hosts, yellowfin goby, *Acanthogobius flavimanus*, are sometimes heavily infected with the metacercariae of heterophyid flukes, and are popularly eaten raw by many residents in coastal areas of Korea [3-7]. However, echinostomatid metacercariae have never been reported from yellowfin gobies in the Republic of Korea.

Therefore, we performed an epidemiological survey to know the infection status of FBT metacercariae in yellowfin gobies collected in Shinan-gun and Muan-gun, Jeollanam-do (province), the Republic of Korea.

On September 2006, 14-15 gobies were collected, and examined by artificial digestion method (Table 1). Trematode metacercariae were segregated, collected under a stereomicroscope, and categorized according to measurements and morphological characteristics. Infection rates and intensities were then calculated. A total of 8 *Echinostoma hortense* metacercariae collected in gobies from Jido-myeon in Shinan-gun were used to experimentally infect a rat to obtain adult worms. Two weeks after the infection, 4 adult flukes were recovered from the small intestine of the rat, which were fixed in 10% neutral buffered formalin, and stained with Semichon's acetocarmine in order to observe their morphological characteristics.

Metacercariae of *H. nocens*, *H. continua*, and *Stictodora* spp. were detected in all of 15 gobies caught from Aphae-myeon in Shinan-gun. The average numbers of metacercariae per infected fish were 153 (*H. nocens*), 20 (*H. continua*), and 334 (*Stictodora* spp.) respectively. A total of 11 *P. summa* metacercariae were collected in only 1 goby from Aphae-myeon (Table 2). In 2 of 14 gobies

• Received 11 February 2009, revised 12 April 2009, accepted 24 April 2009.

\* Corresponding author (wmsohn@gnu.ac.kr)

from Jido-myeon in Shinan-gun, 8 *E. hortense* metacercariae were detected; however, no other kinds of metacercariae were found in 14 gobies from Jido-myeon. In 15 gobies from Haeje-myeon in Muan-gun, the metacercariae of *H. continua* were found in 100%, *Stictodora* spp. in 86.7%, and *H. nocens* in 6.7% of gobies examined. The average numbers of metacercariae per infected fish were 23.3 (*H. continua*), 416 (*Stictodora* spp.), and 2.0 (*H. nocens*), respectively (Table 2).

The metacercariae of *E. hortense* found in gobies were elliptical, 140-163 × 130-143 μm (mean 150 × 138 μm) in size, and had 27 collar spines on the head crown, and excretory granules were arranged posteriorly in V-shape from the pharynx level (Fig. 1). Adults of *E. hortense* recovered from an experimental rat at 2 week after infection were 8.20-9.05 × 1.35-1.63 mm (mean 8.72 × 1.51 mm) in size, had 27 collar spines, and the other morphological characteristics, for example, the right-side deviated round ovary, lobular testes, diffusely distributed vitellaria, and intrauterine eggs, were compatible with previous studies. One adult specimen (Semichon's acetocarmine stained) of *E. hortense* is deposited in Invertebrate Research Division, National Institute of Biological Resources, Korea (NIBRIV0000128379).

It has been proved for the first time in this study that the yellowfin goby, *Acanthogobius flavimanus*, acts as a second intermediate host for *E. hortense*. As the second intermediate hosts of this fluke, several species of freshwater fish, i.e. muddy loach (*Misgurnus anguillicaudatus*), Chinese muddy loach (*Misgurnus mizolepis*), dark sleeper (*Odontobutis interrupta*), Chinese minnow (*Rhynchocypris oxycephalus*), Japanese aucha perch (*Coreoperca kawabari*), short barbel gudgeon (*Squalidus japonicus coreanus*), and some species of amphibians, frogs (*Rana nigromaculata*, *Rana rugosa*, *Rana catesbiana*), salamanders (*Hynobius naevius*, *Hynobius nebulosus*), and toad (*Bufo vulgaris japonicus*) have been reported in Japan, Korea, and China [8-15].

Human infections with *E. hortense* have been reported in Japan, Korea, and China [16-18]. Especially in the Republic of Korea, a 22.4% (59/263) egg-positive rate was reported in a survey of residents in Cheongsong-gun, Gyeongsangbuk-do [13], and recently, clinical cases have been diagnosed occasionally by the gastroduodenal endoscopy [19-23].

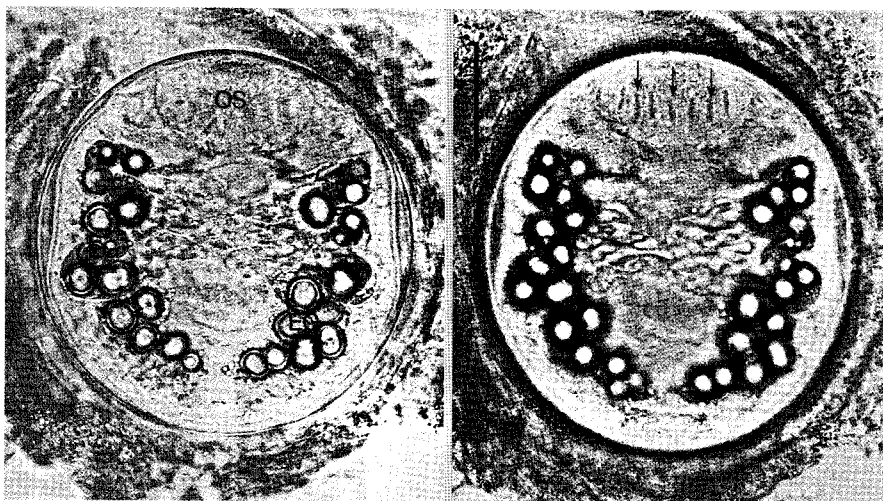
Human infections with *E. hortense* have been reported in Japan, Korea, and China [16-18]. Especially in the Republic of Korea, a 22.4% (59/263) egg-positive rate was reported in a survey of residents in Cheongsong-gun, Gyeongsangbuk-do [13], and recently, clinical cases have been diagnosed occasionally by the gastroduodenal endoscopy [19-23].

**Table 2.** Infection status of heterophyid metacercariae in gobies from Aphae-myeon, Shinan-gun and Haeje-myeon, Muan-gun (Jeo-llanam-do), Korea

Locality of fish & trematode species	No. (%) infected	No. of metacercariae detected		
		Total	Range	Average
Aphae-myeon, Shinan-gun				
<i>Stictodora</i> spp.	15 (100)	5,012	12-982	334.1
<i>Heterophyes nocens</i>	15 (100)	2,298	12-282	153.2
<i>Heterophyopsis continua</i>	15 (100)	299	3-75	19.9
<i>Pygidiopsis summa</i>	1 (6.7)	11	-	11.0
Haeje-myeon, Muan-gun				
<i>Heterophyopsis continua</i>	15 (100)	350	1-102	23.3
<i>Stictodora</i> spp.	13 (86.7)	5,407	9-3,226	415.9
<i>Heterophyes nocens</i>	1 (6.7)	2	-	2.0

**Table 1.** The yellowfin goby, *Acanthogobius flavimanus*, collected in Shinan-gun and Muan-gun (Jeollanam-do), Korea

Locality fish collected	No. of examined	Length (cm)		Weight (g)	
		Range	Average	Range	Average
Aphae-myeon, Shinan-gun	15	15.0-18.5	16.5	23.7-50.9	34.0
Jido-myeon, Shinan-gun	14	17.5-27.0	21.6	36.5-124.2	75.0
Haeje-myeon, Muan-gun	15	14.2-22.7	19.1	22.9-78.4	52.1



**Fig. 1.** The metacercariae of *Echinostoma hortense* detected in an yellowfin goby, *Acanthogobius flavimanus*, from Jido-myeon, Shinan-gun (Jeollanam-do), Korea. They are elliptical with 150 × 138 μm average size, and had an oral sucker (OS) and 27 collar spines (arrow marks) in the head crown, and excretory granules (EG) located posteriorly in V-shape from the pharynx level. Scale bar = 50 μm.

Endemic foci of heterophyid flukes are scattered around the southwestern coastal areas and islands, especially in Shinan-gun and Muan-gun (Jeollanam-do), Korea. Some species of estuarine fish, including *Lateolabrax japonicus*, *Clupanodon punctatus*, *Mugil cephalus*, and *A. flavimanus*, have been reported as sources of human infection in these endemic areas [2]. Among these fish hosts, *A. flavimanus* is sometimes heavily infected with heterophyid metacercariae, and are popularly eaten raw by many residents in southwestern coastal areas [3-7].

Several species of heterophyid fluke metacercariae, i.e. *H. nocens*, *H. continua*, *P. summa*, *S. fuscata*, *S. lari*, and *Acanthotrema felis*, were found in the yellowfin gobies in the Republic of Korea [3-7,24]. In the present study, metacercariae of *H. nocens*, *H. continua*, *Stictodora* spp., and *P. summa* were detected, and especially, high infection rates and intensities were revealed in gobies from Aphae-myeon in Shinan-gun. Metacercariae of *H. continua*, *Stictodora* spp., and *H. nocens* were detected in 15 gobies from Haeje-myeon in Muan-gun. However, except for *E. hortense*, no other metacercariae were found in 14 gobies from Jido-myeon in Shinan-gun. These findings together suggest that those who consume raw yellowfin gobies, *A. flavimanus*, from Shinan-gun and Muan-gun are at a high risk of infection with heterophyid flukes and *E. hortense*.

## ACKNOWLEDGEMENTS

This study was supported by an Anti-Communicable Diseases Control Program of the National Institute of Health (NIH 348-6111-215), Ministry of Health and Welfare, the Republic of Korea. We thank Miss A-Ra Cho and Hae-In Ryu, Department of Parasitology, Gyeongsang National University School of Medicine, Jinju, Korea, for their help in examination of fish.

## REFERENCES

- Chai JY. Intestinal flukes. In Food-Borne Parasitic Zoonoses: Fish and Plant-Borne Parasites. World Class Parasites (Vol. 11). New York, USA. Springer. 2007, p 53-115.
- Chai JY, Lee SH. Food-borne intestinal trematode infections in the Republic of Korea. *Parasitol Int* 2002; 51: 129-154.
- Seo BS, Hong ST, Chai JY, Cho SY. Studies on intestinal trematodes in Korea. IV. Geographical distribution of *Pygidiopsis* and *Heterophyes* metacercariae. *Seoul J Med* 1981; 22: 236-242.
- Chai JY, Park SK, Hong SJ, Choi MH, Lee SH. Identification of *Stictodora lari* (Heterophyidae) metacercariae encysted in the brackish water fish, *Acanthogobius flavimanus*. *Korean J Parasitol* 1989; 27: 253-259.
- Sohn WM, Chai JY, Lee SH. *Stictodora fuscatum* (Heterophyidae) metacercariae encysted in gobies, *Acanthogobius flavimanus*. *Korean J Parasitol* 1994; 32: 143-148.
- Sohn WM, Moon BC. Infection status with the metacercariae of heterophyid trematode in mullet and goby collected from western coastal areas of Cholla-do, Korea. *J Biomed Lab Sci* 2001; 7: 31-37.
- Kim DG, Kim TS, Cho SH, Song HJ, Sohn WM. Heterophyid metacercarial infections in brackish water fishes from Jinju-man (Bay), Kyongsangnam-do, Korea. *Korean J Parasitol* 2006; 44: 7-13.
- Asada S. On a new echinostomatid trematode and its life history. *Trans Jap Pathol Soc* 1926; 16: 293-294.
- Tani S. Studies on *Echinostoma hortense* (Asada, 1926) (1) Species identification of human echinostomiasis and its infection source. *Jpn J Parasitol* 1976; 25: 262-273.
- Tani S. Studies on *Echinostoma hortense* (Asada, 1926) (2) The intermediate and final hosts in Akita Prefecture. *Jpn J Parasitol* 1976; 25: 461-467.
- Chai JY, Hong SJ, Sohn WM, Lee SH, Seo BS. Studies on intestinal trematodes in Korea. XVI. Infection status of loaches with the metacercariae of *Echinostoma hortense*. *Korean J Parasitol* 1985; 23: 18-23.
- Ryang YS, Ahn YK, Lee KW, Kim TS, Hahn MH. Two cases of natural human infection by *Echinostoma hortense* and its second intermediate host in Wonju area. *Korean J Parasitol* 1985; 23: 33-40.
- Lee SK, Chung NS, Ko IH, Sohn WM, Hong ST, Chai JY, Lee SH. An epidemiological survey of *Echinostoma hortense* infection in Chongsong-gun, Kyongbuk Province. *Korean J Parasitol* 1988; 26: 199-206.
- Ryang YS. Studies on *Echinostoma* spp. in the Chungju Reservoir and upper streams of the Namhan River. *Korean J Parasitol* 1990; 28: 221-233.
- Yu SH, Mott KE. Epidemiology and morbidity of food-borne intestinal trematode infections. *Trop Dis Bull* 1994; 91: R125-R152.
- Miyamoto K, Nakao M, Inaoka T. Studies on the zoonoses in Hokkaido, Japan. 5. On the epidemiological survey of *Echinostoma hortense* Asada, 1926. *Jpn J Parasitol* 1983; 32: 261-269.
- Seo BS, Hong ST, Chai JY, Lee SH. Studies on intestinal trematodes in Korea. VII. A human case of *Echinostoma hortense* infection. *Korean J Parasitol* 1983; 21: 219-223.
- Chen XQ, Feng GX, Qian ZF. Survey on infection due to *Echinostoma hortense* Asada in Liaoning Province. *Chinese J Parasitol Parasit Dis* 1993; 11: 226.
- Chai JY, Hong ST, Lee SH, Lee GC, Min YI. A case of echinostomiasis with ulcerative lesions in the duodenum. *Korean J Parasitol* 1994; 32: 201-204.
- Lee SJ, Hong SJ. Gastric echinostomiasis diagnosed by endoscopy. *Gastrointestinal Endoscopy* 2002; 55: 440-442.
- Cho CM, Tak WY, Kweon YO, Kim SK, Choi YH, Kong HH, Chung DI. A human case of *Echinostoma hortense* (Trematoda: Echinostomatidae) infection diagnosed by gastroduodenal endoscopy in Korea. *Korean J Parasitol* 2003; 41: 117-120.

22. Chang YD, Sohn WM, Ryu JH, Kang SY, Hong SJ. A human infection of *Echinostoma hortense* in duodenal bulb diagnosed by endoscopy. *Korean J Parasitol* 2005; 43: 57-60.
23. Park CJ, Kim J. A human case of *Echinostoma hortense* infection diagnosed by endoscopy in area of southwestern Korea. *Korean J Med* 2006; 71: 229-234.
24. Sohn WM, Han EI, Seo M, Chai JY. Identification of *Acanthotrema felis* (Digenea: Heterophyidae) metacercariae encysted in the brackish water fish *Acanthogobius flavimanus*. *Korean J Parasitol* 2003; 41: 101-105.