

## Clinical Article

# Thoracic Myelopathy Caused by Ossification of the Ligamentum Flavum

Hyuk Hur, M.D., Jung-Kil Lee, M.D., Jae-Hyun Lee, M.D., Jae-Hyoo Kim, M.D., Soo-Han Kim, M.D.

Department of Neurosurgery, Chonnam National University Hospital and Medical School, Gwangju, Korea

**Objectives :** Ossification of the ligamentum flavum (OLF) is a rare cause of thoracic myelopathy. The aim of this study was to identify factors associated with the surgical outcome on the basis of preoperative clinical and radiological findings.

**Methods :** Data obtained in 26 patients who underwent posterior decompression for thoracic myelopathy, caused by thoracic OLF, were analyzed retrospectively. Patient age, duration of symptoms, OLF type, preoperative and postoperative neurological status using the Japanese Orthopedic Association (JOA) scoring system, surgical outcome, and other factors were reviewed. We compared the various factors and postoperative prognosis. All patients had undergone decompressive laminectomy and excision of the OLF.

**Results :** Using the JOA score, the functional improvement was excellent in 8 patients, good in 14, fair in 2, and unchanged in 2. A mean preoperative JOA score of 6.65 improved to 8.17 after an average of 27.3 months. According to our analysis, age, gender, duration of symptoms, the involved spinal level, coexisting spinal disorders, associated trauma, intramedullary signal change, and dural adhesions were not related to the surgical outcome. However, the preoperative JOA score and type of OLF were the most important predictors of the surgical outcome.

**Conclusion :** Early diagnosis and sufficient surgical decompression could improve the functional prognosis for thoracic OLF. The postoperative results were found to be significantly associated with the preoperative severity of myelopathy and type of OLF.

**KEY WORDS :** Ossification of ligamentum flavum · Thoracic myelopathy · Surgical outcome.

## INTRODUCTION

Thoracic ossification of the ligamentum flavum (OLF) is a relatively rare cause of myelopathy. It has been mainly reported in Asian patients. The diagnosis of this disorder is usually delayed due to its insidious onset and very slow progression; it is usually present with other spinal disorders. With increasing use of computed tomographic scanning or MRI, OLF is gradually being recognized as a cause of symptomatic thoracic spinal cord compression. An increasing number incidentally discovered cases without advanced symptoms have been recognized. Decompressive laminectomy and excision is the standard treatment of this condition; however, laminoplasty or extended partial laminectomy also has been reported<sup>1,2)</sup> for these patients. However,

the surgical outcome is not always satisfactory and the prognostic factors remain unclear.

Therefore, we retrospectively studied the clinical spectrum, surgical management, and postoperative prognosis in a series of 26 cases with OLF-induced thoracic myelopathy to clarify the clinical features and surgical outcomes. In addition, we investigated the various factors affecting the preoperative severity and postoperative improvement.

## MATERIALS AND METHODS

### Patient population

We analyzed 26 patients who underwent surgery between January 1998 and January 2008 for thoracic OLF at our institution. There were 17 males and 9 females with a mean age of 53 (range, 32-76 years). The diagnosis of thoracic myelopathy was established after thorough neurological examinations and subsequent imaging studies including computed tomography scanning and magnetic resonance imaging. The postoperative follow-up duration ranged from 11 months to 99 months (mean 27.3 months).

• Received : May 18, 2009 • Revised : August 4, 2009  
• Accepted : September 3, 2009  
• Address for reprints : Jung-Kil Lee, M.D.  
Department of Neurosurgery, Chonnam National University Hospital  
and Medical School, 8 Hak-dong, Dong-gu, Gwangju 501-757, Korea  
Tel : +82-62-220-6606, Fax : +82-62-224-9865  
E-mail : jk@chonnam.ac.kr

### Classification of OLF

The patients with thoracic OLF were classified into three types according to the radiological findings of the symptomatic lesions that required surgical decompression on preoperative CT scans : lateral, diffuse, or nodular. The lateral type lesion showed ossification at the facet joint capsule or extending to the lamina; the diffuse type showed thickened ossification with anteromedial enlargement or thickened bilateral ossified ligaments fused at the midline; the nodular type showed fused ossified ligaments growing anteriorly<sup>16)</sup>.

### Clinical evaluations

For the assessment of the neurological status, a modified Japanese Orthopedic Association (JOA)<sup>13)</sup> scoring system was used. The surgical outcome score was determined by the difference in the JOA score, before and after the OLF surgery (Table 1, 2).

To clarify the prognostic factors associated with the surgical outcomes, we evaluated the correlations between the difference in the JOA score and age, gender, level and number of segments affected by OLF, preoperative duration of symptoms, preoperative neurological score, co-existing spinal disorders, associated trauma, radiological findings, and the presence of dural adhesions observed intraoperatively.

### Surgical procedure

Decompressive laminectomy (total laminectomy or bi- or unilateral laminotomy of the limited levels of compression) and resection of the OLF were performed using a high speed drill in all cases. Ten patients underwent simultaneous or prior surgery for other spinal lesions in addition to the procedure for the thoracic OLF; coexisting spinal lesions could not be excluded as potential causes of the lower-extremity symptoms. The procedures used for treating co-existing lesions included : anterior cervical discectomy and fusion (one case), cervical corpectomy (one case), lumbar laminectomy (two cases), posterior lumbar interbody fusion (four cases), intradural tumor removal from the thoracic spine (one case), and thoracic ossified posterior longitudinal ligament removal and interbody fusion via an anterior approach (one case) (Table 3).

### Statistical analysis

For statistical purposes, the data were analyzed using the Pearson chi-square test. Using multiple regression, further analyses were conducted to determine

the variables best correlating to surgical outcome. A probability value of less than 0.05 was considered significant.

## RESULTS

### Clinical features

The mean duration of the initial symptoms was 18.1 months (range, 1 day to 10 years). In five patients there was a history of spinal trauma. The chief complaints were numbness and sensory dysfunction (92%), paraparesis (85%), tingling or pain in legs (31%), and low back pain (23%) (Fig. 1).

**Table 1.** Summary of the modified JOA scoring system for assessment of thoracic myelopathy

Neurological status	Score
Lower-limb motor dysfunction	
Unable to walk	0
Able to walk on flat floor w/walking aid	1
Able to walk up/downstairs w/handrail	2
Lack of stability & smooth reciprocation of gait	3
No dysfunction	4
Lower-limb sensory deficit	
Severe sensory loss or pain	0
Mild sensory deficit	1
No deficit	2
Trunk sensory deficit	
Severe sensory loss or pain	0
Mild sensory deficit	1
No deficit	2
Sphincter dysfunction	
Unable to void	0
Marked difficulty in micturition	1
Minor difficulty in micturition	2
No dysfunction	3

JOA : Japanese Orthopedic Association

**Table 2.** Evaluation of postoperative results

Surgical outcome	Change of JOA score
Excellent	JOA score improved more than 3 points
Good	JOA score improved 1-2 points
Fair	No JOA score change
Poor	Worsening of JOA score

JOA : Japanese Orthopedic Association

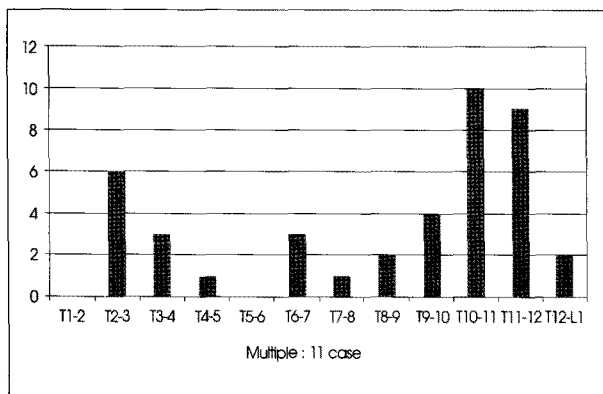
**Table 3.** Operation for coexisting spinal disorders

Disorder	Spinal lesion			Total (%)
	Cervical	Thoracic	Lumbar	
Canal stenosis	1		3	4 (15)
HIVD	1		2	3 (12)
OPLL		1		1 (4)
Spondylolisthesis			1	1 (4)
Schwannoma		1		1 (4)

HIVD : herniated intervertebral disc, OPLL : ossification of posterior longitudinal ligament

**Imaging study**

The surgically decompressed levels considered to be responsible for OLF-induced myelopathy are shown in Fig. 2. Among the 41 total of ossified segments in the series, 25 (61%) were located in the lower thoracic spine, 10 (24%) in the upper thoracic spine, and 6 (15%) in the midthoracic spine. There were 11 cases of multilevel ossified ligamentum flavum.

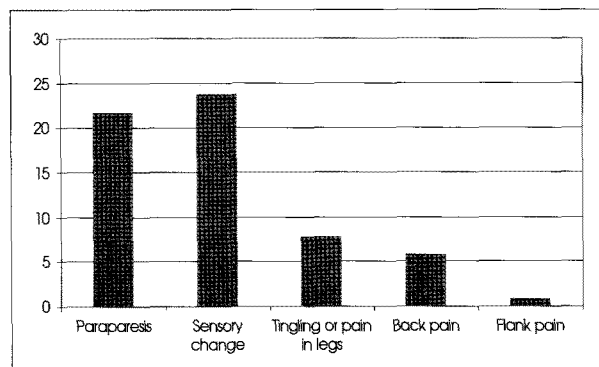


**Fig. 1.** Initial symptoms : most patients presented with paraparesis or sensory change.

The ossified lesions of thoracic ligamentum flavum were classified into three types according to the configuration of ossifications based on the CT and MR images : the lateral type in 20 patients, diffuse type in 5 patients, and nodular type in 1 patient (Fig. 2, Table 4).

**Surgical results**

All patients had laminectomy procedures and ligamen-



**Fig. 2.** Segmental distribution of thoracic ossification of the ligamentum flavum : about half case is at the T10-11 and T11-12 levels. In the upper thoracic region, T2-3 segments are most commonly affected.

**Table 4.** Demographics of the thoracic OLF patients

Patient No.	Gender/ Age (ys)	Level	Sx. Duration (mos)	Motor weakness	Sensory change	Bladder Sx.	Type signal change	Intramedullary	Complication
1	M/52	T10-11	48	4	+	-	Lateral	-	-
2	M/40	T10-11	1d	0	+	+	Lateral	+	-
3	M/46	T2-3	12	3	+	-	Diffuse	+	-
4	F/61	T11-12	48	3	+	-	Lateral	-	-
5	M/70	T11-12	10d	4	+	-	Lateral	-	-
6	F/49	T8-9, 10-11	7	3	+	-	Diffuse	+	-
7	F/65	T2-3, 4-5, 10-11	84	1	+	-	Lateral	+	-
8	M/37	T2-3-4	7	3	+	-	Lateral	-	Hemorrhage, infection
9	M/38	T6-7, 9-10	5d	0	+	+	Nodular	-	-
10	F/54	T10-11	7d	1	+	-	Lateral	-	-
11	M/57	T10-11-12	5	0	+	+	Lateral	+	-
12	F/32	T11-12	1d	0	+	+	Lateral	-	-
13	M/56	T9-10	2	3	+	-	Lateral	-	-
14	M/66	T10-11-12	2	0	+	-	Lateral	+	-
15	M/59	T2-3-4	2	3	-	-	Lateral	-	-
16	M/72	T6-7	7d	3	+	-	Diffuse	+	Dural tear
17	M/62	T6-7-8-9-10	24	3	+	-	Lateral	-	Dural tear
18	F/46	T9-10-11	2	2	+	-	Lateral	-	-
19	M/45	T11-12	36	2	+	-	Lateral	-	-
20	M/51	T2-3	3	3	+	-	Diffuse	+	-
21	F/56	T10-11	3d	1	+	-	Lateral	+	-
22	F/62	T10-11-12-L1	48	4	+	-	Lateral	-	Dural tear
23	F/49	T2-3-4	2	4	+	-	Diffuse	-	-
24	M/76	T12-L1	1	0	-	+	Lateral	+	Dural tear
25	M/64	T11-12	120	1	+	-	Lateral	-	-
26	M/68	T11-12	12	1	+	+	Lateral	+	-

OLF: ossification of the ligamentum flavum

tum flavum removal of the limited spinal level. Ten patients underwent additional procedures for coexisting lesions (cervical lesion in 2 patients, thoracic lesion in 2 patients and lumbar lesion in 6 patients) at the time of the laminectomy for the OLF or at a previous date.

The follow-up period ranged from 11 months to 99 months (average 27.3 months). The mean JOA score at the pre- and postoperative examinations were 6.65 and 8.17, respectively. Postoperatively, 22 out of 26 patients had improvement of the JOA score (excellent and good results), whereas no improvement (fair results) and aggravation (poor results) was observed in 2 patients each. In one of the two patients with poor results, there was postoperative hemorrhage and infection. In the second patient who had coexisting lumbar stenosis and a herniated disc, the JOA score was aggravated despite the rehabilitation treatment.

**Complications**

There were 6 complications from 5 patients. Cerebrospinal fluid leakage occurred in 4 patients; all had a dural tear that was repaired. Postoperative hemorrhage and infection developed in one patient, who thereafter underwent revision surgery twice but had poor results (Table 4).

**Factors affecting outcomes**

Based on univariate analysis, age, gender, duration of symptoms, involved spinal level and numbers, coexisting spinal disorders, associated trauma, intramedullary signal change, and dural adhesions were not related to the surgical outcome. The severity of the myelopathy and type of OLF were significantly associated with the surgical outcome (Table 5). In other words, in patients with symptomatic thoracic OLF, a high preoperative JOA score and a lateral type of OLF on axial CT scans were predictive of good outcomes. However, by binary logistic regression analysis,

the authors did not identify the high preoperative JOA score and a lateral type of OLF on axial CT scans and outcomes at the final follow up.

**DISCUSSION**

OLF is usually asymptomatic. The symptoms of OLF are secondary to stenosis of the spinal canal. The most common clinical picture consists of progressive thoracic myelopathy, resulting in spastic paraparesis, with or without sphincter dysfunction. Walking impairment is generally reported as the main complaint. OLF can also lead to loss of balance due to posterior column dysfunction<sup>15</sup>. Sensory, bladder and bowel involvement are not rare in the late stage<sup>13</sup>. OLF may present as acute myelopathy after minor trauma<sup>14</sup>.

In this study, although the lower thoracic spine is predominantly affected between T9 and T12 in approximately 80% of cases, OLF can occur in the upper and mid-thoracic levels<sup>12</sup>. It can also be multifocal<sup>1,15</sup>. Therefore, a thorough evaluation of the entire thoracic spine is mandatory when symptomatic OLF is suspected. The T2-weighted sagittal imaging by MRI is the modality of choice for screening of the longitudinal extent of OLF<sup>19</sup>. However, MRI is not sufficient for the diagnosis of OLF. MRI shows the typical appearance of a triangular or rectangular protrusion with a hypointense signal on T1 and T2-weighted sequences; this signal change is indistinguishable from that corresponding to a hypertrophic ligamentum flavum. Therefore, MRI combined with sagittal reconstruction of CT images is necessary to establish an accurate diagnosis and for preoperative planning to limit the extent of the decompressive procedure.

Histological examination of OLF typically shows mature lamellar bone associated with proliferating cartilage replacing the ligamentum flavum (endochondral ossification), which begins near the facet joint, at the junction between the joint capsule and the ligamentum flavum. The proliferation of cartilaginous tissue triggers the ossification. Fibronectin, bone morphogenetic protein and transforming growth factor-beta may also play a role in the genesis of OLF<sup>4,5,9,11</sup>. However, we did not perform the histological examination.

Mechanical stress involving constraints on the articular processes during rotation might be a critical factor. In our cases, the most common symptomatic level was T10 to T11 (64%)

**Table 5.** Prognostic factors for surgical outcome

Factor	Surgical outcome				p-value
	Excellent	Good	Fair	Poor	
Preop JOA					0.047
0-3	0	3	1	0	
4-6	5	1	0	0	
7-11	3	10	1	2	
Type					0.017
Lateral	7	11	0	2	
Diffuse	1	3	1	0	
Nodular	0	0	1	0	
Symptom duration					0.146
≤ 6 months	5	8	2	0	
7-12	2	1	0	1	
≥ 13 months	1	5	0	1	

JOA : Japanese Orthopedic Association

and T11 to T12 (21%), which supports this pathogenesis. This region appears to be particularly prone to degenerative processes due to the high tensile force present on the posterior column. Maigne et al.<sup>7</sup> showed a direct correlation between increased mobility of the spine and repetitive mild trauma to the ligamentum flavum with the frequency and size of the ossification in the thoracic spine. They reported that OLF occurred most frequently at the thoracolumbar junction and its appearance correlated with a unique orientation of the zygapophyseal joints that contributed to increased rotatory instability and micromotion<sup>7</sup>. Finally, OLF can be accompanied by certain metabolic diseases of genetic origin, such as hypophosphatemia<sup>8,20</sup>.

OLF is frequently associated with narrowing of the neural canal, ossification of the posterior longitudinal ligament or ossification of other ligaments. Conservative treatment is not effective in preventing disease progression and neurological deterioration. The standard treatment for OLF is posterior decompression because thoracic OLF is compressed from the dorsal toward the ventral side. Most commonly, laminectomy and removal of the enlarged ossified ligamentum flavum are advocated. This procedure should be performed carefully because OLF is frequently adhered to the dura mater. Other posterior decompressive techniques include open-door laminectomy, en-bloc laminectomy, fenestration, hemi-laminectomy, and keyhole foraminotomy<sup>17</sup>. Laminoplasty has also been recommended<sup>5</sup>. The overall recovery rate at the final follow up ranges from approximately 40 to 50%, which is lower than that for cervical OPLL-induced myelopathy (50-70%). We performed laminectomy procedures and ligamentum flavum removal of the limited spinal level in all patients. Twenty-two out of twenty-six patients had improvement of the JOA score (excellent and good results) postoperatively.

The presence of coexisting spinal disorders, such as OPLL, disc herniation, and canal stenosis at different spinal levels, makes the surgical decision making more complicated. The surgical outcome is generally good. However, the prognostic factors contributing to optimal postoperative neurological recovery are unclear. Miyakoshi<sup>10</sup> presented that no correlations were observed between the types of OLF and postoperative prognosis using multiple regression analysis of surgical outcomes. Liao<sup>6</sup> reported that coexisting spinal disorders were not correlated with recovery of independent ambulation. Also, Shiokawa found that no significance was observed between the prognosis and the presence of coexisting spinal lesions. In this study, 10 patients underwent additional procedures for coexisting lesions (cervical lesion in 2 patients, thoracic lesion in 2 patients and lumbar lesion in 6 patients) at the time of the laminectomy

for the OLF or at a previous date and there were no improvement (fair results) and aggravation (poor results) was observed in 2 patients. Using univariate and binary regression analysis, these conditions were not significant predictors for good outcomes.

The follow-up period ranged from 11 months to 99 months (average 27.3 months). The mean JOA score at the pre- and postoperative examinations were 6.65 and 8.17, respectively. A shorter duration of preoperative symptoms, a thoracic canal less affected by stenosis and the absence of proximal stenosis are correlated with a better postoperative neurological recovery<sup>2,3,6,10,17</sup>. Takei<sup>18</sup> has reported the negative effects of the following on patient outcome: preoperative lower-extremity function, duration of illness, multiple ossifications, level and progression of ossification, degree of thoracic kyphosis, and complications. Shiokawa<sup>17</sup> reported that the duration of preoperative symptoms would play an important role in surgery-related outcomes, with excellent results documented in patients in whom the duration of preoperative symptoms was shorter. Miyakoshi<sup>10</sup> found that the duration of preoperative symptoms and the neurological status were important predictors of postoperative surgical outcomes. They also found that patients with fecal and/or urinary incontinence, positive patellar and/or ankle clonus, and intramedullary high T2-weighted MR imaging signal changes were at high risk for a poor outcome after surgery.

In our study, the duration of symptoms did not reach statistical significance as a factor correlated with the surgical outcome ( $p = 0.54$ ). This might be due to the insidious onset of clinical symptoms and the high incidence of coexisting spinal disorders, which might have confused the patient's recognition of the initial presentation and progression of symptoms associated with thoracic OLF.

## CONCLUSION

Early diagnosis and sufficient surgical decompression could improve the functional outcome of patients with thoracic OLF. In our study, the preoperative neurological status and type of OLF was correlated with the postoperative functional outcome on univariate analysis. Decompressive surgery should be performed at an early stage of disease progression while neurological symptoms are mild and ambulatory function is not impaired in patients with symptomatic thoracic OLF.

• Acknowledgements  
This paper was partly supported by research sponsorship from AOSpine Korea.

References

1. Ben Hamouda K, Jemel H, Haouet S, Khaldi M : Thoracic myelopathy caused by ossification of the ligamentum flavum : a report of 18 cases. *J Neurosurg* 99 : 157-161, 2003
2. Chang UK, Choe WJ, Chung CK, Kim HJ : Surgical treatment for thoracic spinal stenosis. *Spinal Cord* 39 : 362-369, 2001
3. Cho YH, Moon SM, Roh SW, Joen SR, Rhim SC : Surgical outcome and prognostic factors of ossified ligamentum flavum of the thoracic spine. *J Korean Neurosurg Soc* 32 : 424-430, 2002
4. Hayashi K, Ishidou Y, Yonemori K, Nagamine T, Origuchi N, Maeda S, et al. : Expression and localization of bone morphogenetic proteins (BMPs) and BMP receptors in ossification of the ligamentum flavum. *Bone* 21 : 23-30, 1997
5. Hoshi K, Amizuka N, Sakou T, Kurokawa T, Ozawa H : Fibroblasts of spinal ligaments pathologically differentiate into chondrocytes induced by recombinant human bone morphogenetic protein-2 : morphological examinations for ossification of spinal ligaments. *Bone* 21 : 155-162, 1997
6. Liao CC, Chen TY, Jung SM, Chen LR : Surgical experience with symptomatic thoracic ossification of the ligamentum flavum. *J Neurosurg Spine* 2 : 34-39, 2005
7. Maigne JY, Ayrat X, Guérin-Surville H : Frequency and size of ossification in the caudal attachments of the legamentum flavum of the thoracic spine. Role of rotatory strains in their development. An anatomical study of 121 spines. *Surg Radiol Anat* 14 : 119-124, 1992
8. Matsui H, Katoh Y, Tsuji H : Untreated hypophosphatemic vitamin D-resistant rickets with symptomatic ossification of the ligamentum flavum. *J Spinal Disord* 4 : 110-113, 1991
9. Mimatsu K, Kishi S, Hashizume Y : Experimental chronic compression on the spinal cord of the rabbit by ectopic bone formation in the ligamentum flavum with bone morphogenetic protein. *Spinal Cord* 35 : 740-746, 1997
10. Miyakoshi N, Shimada Y, Suzuki T, Hongo M, Kasukawa Y, Okada K, et al. : Factors related to long-term outcome after decompressive surgery for ossification of the ligamentum flavum of the thoracic spine. *J Neurosurg* 99 : 251-256, 2003
11. Miyamoto S, Yonenobu K, Ono K : Elevated plasma fibronectin concentrations in patients with ossification of the posterior longitudinal ligament and ossification of the ligamentum flavum. *Spine (Phila Pa 1976)* 18 : 2267-2270, 1993
12. Mohindra S, Chhabra R, Mukherjee KK, Gupta SK, Vaiphei K, Khosla VK : Spinal compression due to ossified yellow ligament : a short series of 5 patients and literature review. *Surg Neurol* 65 : 377-384; discussion 384, 2006
13. Palumbo MA, Hilibrand AS, Hart RA, Bohlman HH : Surgical treatment of thoracic spinal stenosis : a 2- to 9-year follow-up. *Spine (Phila Pa 1976)* 26 : 558-566, 2001
14. Park BC, Min WK, Oh CW, Jeon IH, Kim SY, Kyung HS et al. : Surgical outcome of thoracic myelopathy secondary to ossification of ligamentum flavum. *Joint Bone Spine* 74 : 600-605, 2007
15. Pascal-Moussellard H, Cabre P, Smadja D, Catonné Y : Symptomatic ossification of the ligamentum flavum : a clinical series from the French Antilles. *Spine (Phila Pa 1976)* 30 : E400- E405, 2005
16. Sato T, Tanaka Y, Aizawa T, Koizumi Y, Kokubun S : [Surgical treatment for ossification of ligamentum flavum in the thoracic spine and its complications.] *Spine Spinal Cord* 11 : 505-510, 1998
17. Shiokawa K, Hanakita J, Suwa H, Saiki M, Oda M, Kajiwara M : Clinical analysis and prognostic study of ossified ligamentum flavum of the thoracic spine. *J Neurosurg* 94 : 221-226, 2001
18. Taeki Y : Posterior decompression surgery of thoracic myelopathy due to ossification of intraspinal canal ligaments. *J Bone Joint Surg Gr* 77 : 131-133, 1995
19. Trivedi P, Behari S, Paul L, Banerji D, Jain VK, Chhabra DK : Thoracic myelopathy secondary to ossified ligamentum flavum. *Acta Neurochir (Wien)* 143 : 775-782, 2001
20. Vera CL, Cure JK, Naso WB, Gelven PL, Worsham F, Roof BF, et al. : Paraplegia due to ossification of ligamenta flava in X-linked hypophosphatemia. A case report. *Spine (Phila Pa 1976)* 22 : 710-715, 1997