

## Autosomal-dominant Polycystic Kidney Disease in a Family of Scottish Fold Cats

Kyoung-won Seo, Sae-um Kim\*, Jin-ok Ahn, Ye-rin Coh, Sung-young Han\* and Hwa-young Youn<sup>1</sup>

College of Veterinary Medicine, Seoul National University, Daehak-dong, Gwanak-gu, Seoul, 151-742, Korea,  
\*Namyangju Animal Hospital, Pyeongnae-dong, Namyangju-si, Gyeonggi-do, 249-2, Korea

(Accepted: December 07, 2010)

**Abstract :** Autosomal-dominant polycystic kidney disease (AD-PKD) is common in Persian and Persian-related breeds, and is sporadically reported in Scottish Fold cats. A 5-year-old male Scottish Fold cat was diagnosed with polycystic kidney disease based on screening tests and abdominal ultrasonography and died 3.5 months after diagnosis. The cat had 14 kittens with three queens, including his female sibling, with an age range of 3 months to 8 years. Genetic testing to confirm the genetic transmission of AD-PKD which detects the mutated PKD1 gene was performed. Abdominal ultrasonography confirmed the presence of renal cysts. Nineteen cats were screened in the present study (13 males and 6 females), with an age range of 3 months to 8 years. The results of renal ultrasonography agreed with the genetic test results in the 19 cats in which both tests were performed and 8 cats were diagnosed as AD-PKD based on these tests. AD-PKD has not been investigated in cats in South Korea. Moreover, this is the first report of AD-PKD in a family unit of Scottish Fold cats.

**Key words :** Autosomal dominant polycystic kidney disease, feline, PCR/RFLP, Scottish Fold cats.

### Introduction

Autosomal-dominant polycystic kidney disease (AD-PKD) is the most prevalent inherited genetic disease in cats. It occurs most frequently in Persian (approximately 40-50% worldwide) and Persian-related cats (Exotic Shorthair and Himalayan) (1,2,3,6). The prevalence of AD-PKD in other breeds is less known. There have been sporadic reports of cases in Burmilla, domestic shorthairs, American Shorthairs, British Shorthairs, Ragdolls, and Scottish Folds (1,9). The fatal clinical manifestation is chronic renal failure (11), which usually occurs at a later age. As cysts enlarge, they compress surrounding renal parenchyma, and produce lesions of chronic interstitial nephritis. Thus, PKD1 is considered a late onset renal disease, while PKD is considered a progressive disease, and the prognosis is guarded (1,8).

The most reliable diagnostic tool for AD-PKD is renal ultrasonography. Its sensitivity is reported to be 75 per cent when performed at 16 weeks of age and 91 per cent when performed at 36 weeks of age (4), increasing to 100 per cent in older cats (1,2,6,10). Currently, polymerase chain reaction/restriction fragment length polymorphism (PCR/RFLP) assay is available to detect the mutated gene, PKD1, identified in AD-PKD cats (10). We describe AD-PKD in a family of Scottish Fold cats (4 generations, 19 individuals) in South Korea for the first time and reveal the pattern of genetic transmis-

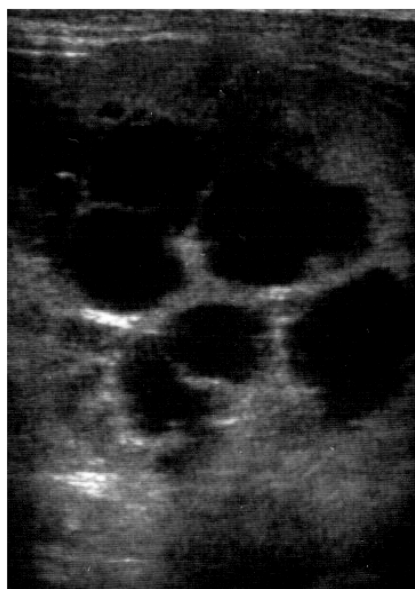
sion of PKD.

A 5-year-old male Scottish Fold cat presented with a history of polyuria and polydipsia of 2-month duration. Body temperature, and heart and respiratory rates were normal. Abdominal palpation revealed bilateral kidney enlargement. A complete blood count (CBC), serum biochemical analysis, urinalysis, and abdominal radiography, and ultrasonography were performed. The CBC and serum biochemical analysis were normal with the exception of azotemia (BUN 113.5 mg/dl, reference range 16-36 mg/dl; creatinine 5.0 mg/dl, reference range 0.8-2.4 mg/dl, VetTest<sup>®</sup> SNAP, IDEXX, USA). Urinalysis was unremarkable (specific gravity: 1.019, normal range 1.015-1.045); absence of glucose, bilirubin, blood, leukocytes and ketonic acid and the results of urine culture was negative. Abdominal radiography confirmed severe bilateral renomegaly, and the margins of both kidneys appeared irregular. Abdominal ultrasonography detected multiple cysts replacing most of the normal renal parenchyma in both kidneys (Fig 1). There were no cysts in the liver or in other abdominal organs. The cat was given a low-protein diet and intermittent fluid therapy. However, the disease progressed and the cat died 3.5 months later. Necropsy was not permitted.

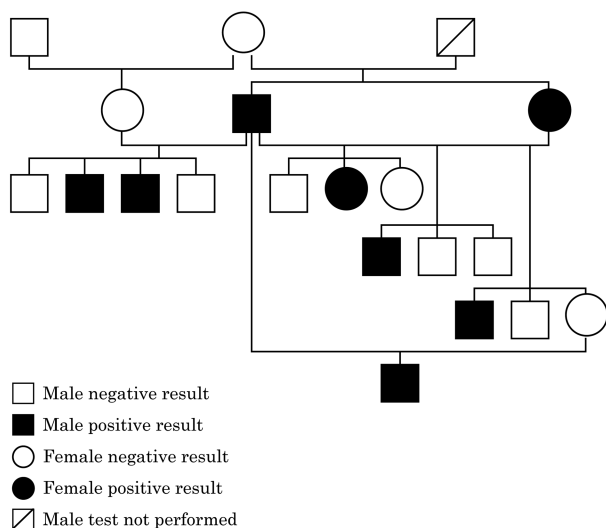
The cat had sired 14 kittens (11 male, 3 female) with three queens including a female sibling. The female sibling produced 9 offspring in 3 litters, 6 male and 3 female. The family tree is given in Fig 2. The breeder was advised about the test for genetic transmission of AD-PKD.

Ultrasonography of other cats in the cattery revealed that 6 males and 2 females had PKD. To confirm the inherited pat-

<sup>1</sup>Corresponding author.  
E-mail : hyyoun@snu.ac.kr




**Fig 1.** Ultrasonography of polycystic kidney of a 5-year-old male Scottish Fold cat showed multiple cysts in the renal parenchyma.



**Fig 2.** Pedigree tree of a 4-generation Scottish Fold cat family.

tern, a genetic test for the mutated PKD1 gene was performed on blood samples. Genomic DNA was extracted from ethylenediamine tetraacetic acid (EDTA) anticoagulated whole blood using a genomic DNA purification kit (Quagen, Hilden, Germany). The PKD1 exon 29 was partially amplified by PCR producing a 559 bp amplicon, according to the protocol reported previously (10). Restriction fragment length polymorphism (RFLP) analysis of amplification products followed. Briefly, approximately 5  $\mu$ l of amplification product was digested with 10 U of MlyI (Fermentas, Amherst, NY, USA) in a 10  $\mu$ l reaction containing 1 $\times$  Tango buffer incubated at 37°C for 4 h followed by inactivation of the enzyme at 65°C for 10 min. The digestion products were analysed on 2 per cent agarose gel electrophoresis, visualized by ethidium bromide (EtBr) stain-



**Fig 3.** RFLP typing for feline AD-PKD1 mutation revealed positive result. Left: 100 bp DNA ladder (Intron); right: heterozygous pattern showing 599 bp fragment of the wild-type allele and 316 plus 243 bp fragments of the mutated causative allele.

ing and photographed with a Gel-Doc system (Fig 3, Biorad, Hercules, CA). Among the 19 cats examined 8 (42.1%) were PKD-positive by both ultrasonography and genetic test.

Renal ultrasound examination is a non-invasive, rapid, sensitive, and highly specific method for detecting cats with AD-PKD.

PCR/RFLP can detect the AD-PKD mutation and thus can discriminate between inherited and non-inherited cysts. PCR/RFLP is used worldwide because it is inexpensive, rapid, and easy to interpret, though it can fail because of bad sampling, technical failure, and human error (5). Currently, genetic testing is the method of choice for diagnosis of AD-PKD1 in kittens under 4 months. Ultrasonography is used in adult cats with genetic testing useful for confirming the inherited PKD1 pattern (5). Synergic uses of both tests have been recommended in other studies to identify feline PKD (5,9). A recent study of 63 Persian and seven Exotic Shorthair cats undergoing both ultrasound and genetic examination revealed 83 per cent consistency, with 29 cats positive by ultrasound and 24 positive by genetic PCR/RFLP (5). Nineteen cats were screened in the present study (13 males and 6 females), with an age range of 3 months to 8 years. The results of renal ultrasonography agreed with the genetic test results in the 18 cats in which both tests were performed. There was a similar proportion of positive males (6/13, 46.2%) and females (2/6, 33.3%). The number of screened cats was too few to draw conclusions about prevalence, and no sex-related association has been suggested (1,7).

The pet cat population in South Korea has been growing rapidly in recent years. However, to the authors' knowledge, there has been no investigation of the prevalence of PKD in either Persian or Persian-related breeds, including Scottish Fold cats. Estimating the prevalence of the disease is essential before initiating a screening programme to document the efficiency of an eradication process. Currently, Scottish Fold cats are bred with British Shorthairs and American Shorthairs only, but Persians and Exotic Shorthairs have been crossed with Scottish Fold cats. In Scottish Fold cats, the incidence of PKD1 has been reported only sporadically, and there has been no previous investigation of its transmission in a family unit.

In conclusion, the paired use of ultrasound and genetic tests

proved reliable in detecting feline PKD. Recently, the cat population is growing in Korea including Scottish Fold cats. Therefore, to eradicate PKD in this breed, a screening programme is needed not only in Persian and Exotics which is already known for having this disease but in Scottish Fold cats. Also PKD should be considered as a possible cause of chronic renal failure in this breed.

### Acknowledgement

This study was supported by the Brain Korea 21 Program for Veterinary Science, and Research Institute of Veterinary Science, College of Veterinary Medicine, Seoul National University.

### References

1. Barrs VR, Gunew M, Foster SF, Beatty JA, Malik R. Prevalence of autosomal dominant polycystic kidney disease in Persian cats and related-breeds in Sydney and Brisbane. *Aust Vet J* 2001; 79: 257-259.
2. Barthez PY, Rivier P, Begon D. Prevalence of polycystic kidney disease in Persian and Persian related cats in France. *J Feline Med Surg* 2003; 5: 345-347.
3. Beck C, Lavelle RB. Feline polycystic kidney disease in Persian and other cats: a prospective study using ultrasonography. *Aust Vet J* 2001; 79: 181-184.
4. Biller DS, Dibartola SP, Eaton KA, Pflueger S, Wellman ML, Radin MJ. Inheritance of polycystic kidney disease in Persian cats. *J Hered* 1996; 87: 1-5.
5. Bonazzi M, Volta A, Gnudi G, Cozzi MC, Strillacci MG, Polli M, Longeri M, Manfredi S, Bertoni G. Comparison between ultrasound and genetic testing for the early diagnosis of polycystic kidney disease in Persian and Exotic Shorthair cats. *J Feline Med Surg* 2009; 11: 430-434.
6. Cannon MJ, Mackay AD, Barr FJ, Rudolf H, Bradley KJ, Gruffydd-jones TJ. Prevalence of polycystic kidney disease in Persian cats in the United Kingdom. *Vet Rec* 2001; 149: 409-411.
7. Domanjko-petric A, Cernec D, Cotman M. Polycystic kidney disease: a review and occurrence in Slovenia with comparison between ultrasound and genetic testing. *J Feline Med Surg* 2008; 10: 115-119.
8. Eaton KA, Biller DS, Dibartola SP, Radin MJ, Wellman ML. Autosomal dominant polycystic kidney disease in Persian and Persian-cross cats. *Vet Pathol* 1997; 34: 117-126.
9. Helps C, Tasker S, Harley R. Correlation of the feline PKD1 genetic mutation with cases of PKD diagnosed by pathological examination. *Exp Mol Pathol*. 2007; 83: 264-268.
10. Lyons LA, Biller DS, Erdman CA, Lipinski MJ, Young AE, Roe BA, Qin B, Granhn RA. Feline polycystic kidney disease mutation identified in PKD1. *J Am Soc Nephrol* 2004; 15: 2548-2555.
11. Volta A, Manfredi S, Gnudi G, Gelati A, Bertoni G. Polycystic kidney disease in a Chartreux cat. *J Feline Med Surg* 2010; 12: 138-140.

## 스코티쉬 폴드 고양이 가족에 발생한 상염색체 우성 다낭성 신병

서경원 · 김새움\* · 안진옥 · 고예린 · 한성영\* · 윤화영<sup>1</sup>

서울대학교 수의과대학, \*남양주 동물병원

**요약** : 상염색체 우성 다낭성 신병은 페르시안과 페르시안에서 유래된 품종에서 다발하는 질환으로, 스코티쉬 폴드 고양이에서도 간혹 보고된 바가 있다. 5살령의 수컷 스코티쉬 폴드 고양이가 기본적인 혈액 검사와 복부 초음파 등을 통해 다낭성 신병으로 진단 받은 후 3.5 개월 만에 폐사하였다. 이 고양이는 동배 암컷 고양이를 비롯한 3 마리의 암컷 고양이와 교배하여 14마리의 새끼고양이가 있었으며 연령대는 3개월령에서 8년령으로 다양하였다. 상염색체 우성 다낭성 신병인지를 확인하기 위해 변이된 PKD1 유전자에 대한 유전자 검사가 이루어졌다. 또한 복부 초음파를 통해 신장의 낭성 구조물을 확인하는 검사도 이루어졌다. 총 19마리 (수컷: 13마리, 암컷: 6 마리) 에 대한 검사가 이루어졌으며 연령대는 3개월에서 8년령 사이였다. 검사 결과, 19마리 모두에서 유전자 검사와 초음파 검사 결과가 일치하였고, 이 중 8마리가 상염색체 우성 다낭성 신병으로 진단되었다. 아직까지 한국에서는 고양이의 상염색체 우성 다낭성 신병은 보고 된바 없으며, 본 조사는 가족 단위의 스코티쉬 폴드 고양이에 발생한 상염색체 우성 다낭성 신병에 대한 첫 보고이다.

**주요어** : 상염색체 우성 다낭성 신병, 고양이, PCR/RFLP, 스코티쉬 폴드 고양이