

Case Report

Late Occurrence of Cervicothoracic Ossification of Posterior Longitudinal Ligaments in a Surgically Treated Thoracic OPLL Patient

Seung-Jae Hyun, M.D., Jong-Soo Kim, M.D., Seung-Chyul Hong, M.D.

Department of Neurosurgery, Samsung Medical Center, Sungkyunkwan University School of Medicine, Seoul, Korea

Ossification of the posterior longitudinal ligament (OPLL) in the thoracic spine is rare, even in the Far East. A 45-year-old female presented with a 4-month history of progressive motor weakness in the lower extremities, numbness below the midthoracic area, and spastic gait disturbance. Neuroradiological examinations revealed massive OPLLs at the T4-T6 levels with severe anterior compression of the spinal cord. Anterior decompressive corpectomies with bone grafts were performed from T4 to T6 using a trans-thoracic approach. After surgery, the patient made an uneventful recovery. However, eleven years after surgery, the patient developed recurrent lower extremity weakness and spastic gait disturbance. De novo OPLLs at the C6-T2 levels were responsible for the severe spinal cord compression on this occasion. After second surgery, paralysis in both legs was resolved. We present a rare case of late cervicothoracic OPLL in a patient surgically treated for thoracic OPLL.

KEY WORDS : Cervicothoracic spine · Thoracic spine · Ossification of the posterior longitudinal ligament · Late occurrence · Anterior decompression.

INTRODUCTION

Symptomatic ossification of the posterior longitudinal ligaments (OPLLs) usually occurs in the cervical vertebrae and is one of the main causes of cervical myelopathy³⁾. Thoracic myelopathy caused by OPLL is rare, as compared with cervical myelopathy, but the incidence of concurrent thoracic OPLL in patients with cervical OPLL has not been well established because of the rarity of the condition, even in the Far East area⁴⁾. In terms of surgery for cervical OPLL, complete recognition of OPLL and ossification of the ligamentum flavum (OLF) in the cervical and thoracic spine is critical for planning cervical spine procedures¹⁾.

We present an unusual case of extensive cervicothoracic OPLL following an anterior decompression operation for thoracic OPLL.

CASE REPORT

A 45-year-old female presented with a 4-month history of progressive motor weakness in the lower extremities, numbness below the midthoracic area, and spastic gait disturbance. A neurological examination revealed spasticity in lower limbs with brisk deep tendon reflexes and grade 4/5 power in lower extremities, particularly in hip flexors. There was also a subjective decrease in pinprick sensation below the 4th thoracic dermatome and urinary incontinence. She was evaluated using the Japanese Orthopedic Association (JOA) scoring system⁶⁾, and scored 9 out of a maximum of 17 points.

Computerized tomography (CT) scans showed massive OPLLs at the T4-T6 levels (Fig. 1A), and small OPLLs at the C7-T1 levels. Magnetic resonance imaging (MRI) of the cervical and thoracic spine demonstrated ventral bony masses at the same levels with severe anterior compression of the spinal cord between T4 and T6 (Fig. 1B). We diagnosed this as myelopathy resulting from thoracic OPLL.

First operation and postoperative course

Anterior decompressive corpectomies under intraopera-

• Received : April 24, 2009 • Revised : May 23, 2009
 • Accepted : November 30, 2009
 • Address for reprints : Jong-Soo Kim, M.D.
 Department of Neurosurgery, Samsung Medical Center,
 Sungkyunkwan University School of Medicine, 50 Irwon-dong,
 Gangnam-gu, Seoul 135-710, Korea
 Tel : +82-2-3410-3495, Fax : +82-2-3410-0048
 E-mail : jongskim@skku.edu

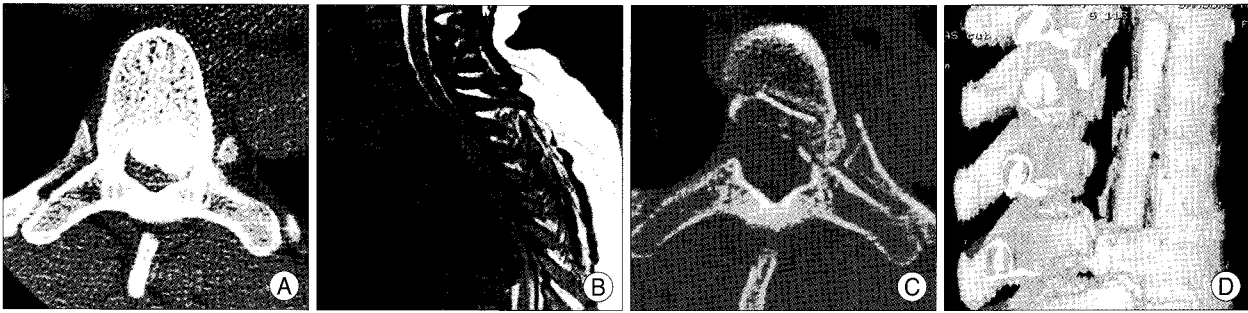


Fig. 1. A : Preoperative axial computerized tomographic (CT) scan showing massive ossification of the posterior longitudinal ligament (OPLL) in the 6th thoracic spine. B : Preoperative magnetic resonance image of the cervicothoracic spine demonstrating severe spinal cord compression at the T4-T6 levels. Other small OPLLs are observed at the C7-T1 levels. C and D : Postoperative axial CT scan and 3-D CT reconstruction image showing sufficient decompression of the thoracic spinal cord.

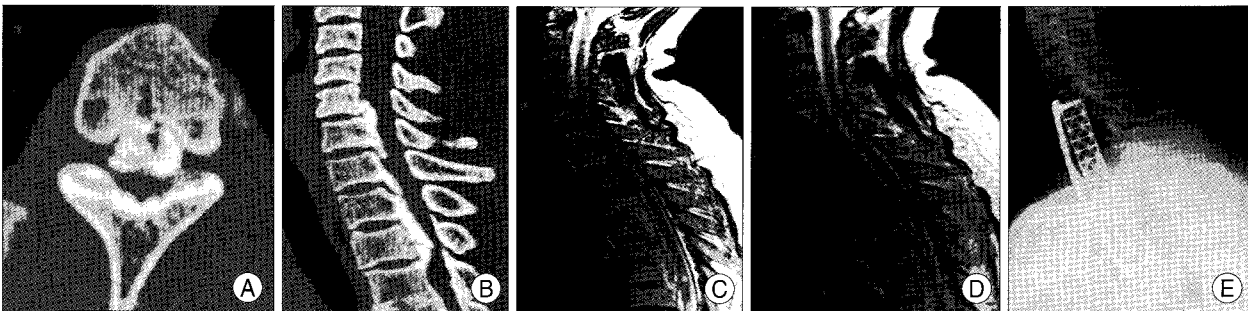


Fig. 2. A and B : Preoperative axial computerized tomographic (CT) scan and a sagittal reconstruction image showing the de novo growth of OPLLs from C6 to T2. C : Preoperative magnetic resonance (MR) image of the cervicothoracic spine demonstrating OPLLs at the same levels with severe spinal cord compression. D : Postoperative MR image showing sufficient decompression of the cervicothoracic spinal cord. E : Postoperative lateral radiograph of the cervicothoracic spine showing the cervicothoracic reconstruction, which was conducted using a curved mesh cage, and a plate and screw system.

tive monitoring using somatosensory evoked potentials (SEPs) were performed from T4 to T6 using a trans-thoracic approach with bone grafting using a piece of ileum. After surgery, the patient made an uneventful recovery, and experienced strength improvement. Postoperative CT showed sufficient decompression of the thoracic spinal cord (Fig. 1C, D). Her clinical symptoms slightly improved and her JOA score increased from 9 to 15.

However, eleven years after surgery the patient developed recurrent progressive lower extremity weakness, spastic gait disturbance, and urinary incontinence. MRI and CT scans demonstrated massive OPLLs at the C6-T2 levels with severe spinal cord compression (Fig. 2A, B).

Second operation and postoperative course

Under motor evoked potential and SEP monitoring, the patient underwent additional anterior corpectomies from C6 to T2 via a trans-sternal approach with anterior interbody fusion from C5 to T3 using a titanium mesh cage and a plate and screw system with bone grafting using a femur head allograft (Fig. 2C, D, and E). Immediately after surgery, paralysis resolved in both legs, although numbness and hypesthesia remained in both legs. She was satisfied with her surgical results and her JOA score recovered to 15 points at 6 months postoperatively.

DISCUSSION

Ossification of the posterior longitudinal ligament in the thoracic spine is rare, even in the Far East area^{4,8}, and is sometimes discovered during inspections of the whole spine in patients with cervical OPLL. Some patients report only myelopathy without an accompanying cervical disorder. However, myelopathy due to thoracic OPLL may rapidly become complete after symptom onset. On the other hand, other patients with thoracic OPLL report only continuous back pain during consultation. Ossifications of spinal ligaments, such as, the OPLL and OLF in the thoracic spine, are usually asymptomatic when lesions are small and thin and there is no cord compression. However, after myelopathy in the thoracic and cervicothoracic spine appears due to OPLL, OLF, or a combination of the two, conservative management is no longer an option. Several reports have suggested that surgical management is the most effective treatment for thoracic myelopathy¹⁶. Thoracic surgical approaches may be classified into anterior and posterior techniques^{2,3,7}. Anterior procedures include the trans-thoracic approach⁷, median sternotomy⁷, the trans-sternal approach¹³, and anterior decompression through the posterior approach⁹, while posterior techniques include laminectomy¹⁵.

Anterior lesions, such as, OPLLs in the upper thoracic spine, may be decompressed using either an anterior or posterior procedure. However, some investigators have suggested that laminectomy is generally ineffective for the management of thoracic myelopathy and that it occasionally precipitates clinical worsening, especially in the presence of a predominantly anterior OPLL pathology. Stillerman and colleague observed that laminectomy when used to treat thoracic disc herniations led to poor results, and concluded that it is unsuitable for anterior thoracic lesions¹².

Therefore, anterior procedures were used to address upper thoracic OPLL. In the upper thoracic spine, median sternotomy and trans-sternal approaches are employed, but in cases of OPLL extending from the upper cervical spine to the thoracic spine, posterior procedures are more suitable than anterior alternatives⁴.

In the present case, cervicothoracic OPLL developed 11 years after thoracic OPLL surgery. In long-term follow-up studies on cervical OPLL, de novo growth of thoracic OLF was frequently found in patients who experienced a delayed neurologic deterioration^{5,10}. Some earlier investigators reported the late recurrence and progression of thoracic OLF^{11,14}. They concluded that mechanical stress was believed to play an important role in the progression of thoracic OLF and spinal hypermobility might lead to the ossification of the ligament. However, the incidence of ossified thoracic ligaments, including OPLL and OLF, combined with cervical OPLL has not been reported.

CONCLUSION

We present a rare case of late cervicothoracic OPLL development in a surgically treated thoracic OPLL patient. The de novo development of cervicothoracic OPLL is rare and treatments are surgically demanding.

• Acknowledgements

The submitted manuscript does not contain information about medical devices or drugs.

No funds were received in support of this work. No benefits in any

form have been or will be received from a commercial party related directly or indirectly to the subject of this manuscript.

References

1. Bohlman HH, Zdeblick TA : Anterior excision of herniated thoracic discs. *J Bone Joint Surg* 70 : 1038-1047, 1988
2. Dohn DF : Thoracic spinal cord decompression : Alternative surgical approaches and basis of choice. *Clin Neurosurg* 27 : 611-623, 1980
3. Epstein N : Diagnosis and surgical management of cervical ossification of the posterior longitudinal ligament. *Spine J* 2 : 436-449, 2002
4. Hanai K, Ogikubo O, Miyashita T : Anterior decompression for myelopathy resulting from thoracic ossification of the posterior longitudinal ligament. *Spine* 15 : 1070-1076, 2002
5. Inamasu J, Guiot BH, Sachs DC : Ossification of the posterior longitudinal ligament : an update on its biology, epidemiology, and natural history. *Neurosurgery* 58 : 1027-1039; discussion 1027-1039, 2006
6. Japanese Orthopedic Association : Scoring system for cervical myelopathy. *J Jpn Orthop Assoc* 68 : 490-503, 1994
7. Kojima T, Waga S, Kubo Y, Matsubara T : Surgical treatment of ossification of the posterior longitudinal ligament in the thoracic spine. *Neurosurgery* 34 : 854-858; discussion 858, 1994
8. Lim CS, Cho TH, Park JY, Park YK, Suh JK, Lee HK : Thoracic myelopathy caused by multiple ossified ligamentum flavum combined with ossification of the posterior longitudinal ligament : Case Report. *J Korean Neurosurg Soc* 25 : 617-621, 1996
9. Micheli LJ, Hood RW : Anterior exposure of the cervicothoracic spine using a combined cervical and thoracic approach. *J Bone Joint Surg* 65 : 992-997, 1983
10. Ogawa Y, Toyama Y, Chiba K, Matsumoto M, Nakamura M, Takaishi H, et al. : Long-term results of expansive open-door laminoplasty for ossification of the posterior longitudinal ligament of the cervical spine. *J Neurosurg Spine* 1 : 168-174, 2004
11. Park JY, Chin DK, Kim KS, Cho YE : Thoracic ligament ossification in patients with cervical ossification of the posterior longitudinal ligaments: tandem ossification in the cervical and thoracic spine. *Spine* 33 : E407-E410, 2008
12. Stillerman CB, Weiss MH : Management of thoracic disc disease. *Clin Neurosurg* 38 : 325-352, 1992
13. Sundaresan N, Shah J, Feghali JG : A transsternal approach to the upper thoracic vertebrae. *Am J Surg* 148 : 473-477, 1984
14. Vasudevan A, Knuckey NW : Ossification of the ligamentum flavum. *J Clin Neurosci* 9 : 311-313, 2002
15. Yamamoto I, Matsumae M, Ikeda A, Shibuya N, Sato O, Nakamura K : Thoracic spinal stenosis : Experience with seven cases. *J Neurosurg* 68 : 37-40, 1988
16. Yonenobu K, Ebara S, Fujiwara K, Yamashita K, Ono K, Yamamoto T, et al. : Thoracic myelopathy secondary to ossification of the spinal ligament. *J Neurosurg* 66 : 511-518, 1987