

## Case Report

# Lumbar Disc Herniation in Tae Kwon Do Athletic Child

Sung Hoon Kim, M.D., Ph.D.,<sup>2</sup> Hyeun Sung Kim, M.D., Ph.D.,<sup>3</sup> Seok Won Kim, M.D., Ph.D.<sup>1</sup>

Department of Neurosurgery,<sup>1</sup> College of Medicine, Chosun University, Gwangju, Korea

Department of Rehabilitation,<sup>2</sup> Wonju College of Medicine, Yonsei University, Wonju, Korea

Department of Neurosurgery,<sup>3</sup> Heori Sarang Hospital, Daejeon, Korea

Lumbar disc herniation is extremely uncommon in children below 10 years of age. A 7-year-old boy is reported who presented with low back pain and left leg radiating pain. The pain started seven days prior to presentation and was attributed to performing the jumping kick without any previous warm-up. Magnetic resonance imaging revealed a posterolateral disc herniation at the L3-4 level and multiple degenerative changes. The patient received conservative treatment including limitation of sports activities, anti-inflammatory and muscle relaxant medications as well as physical therapy. After three months of the aggressive treatment the child was symptom free. We present here a lumbar disc herniation in one of the youngest patient.

**KEY WORDS :** Lumbar disc herniation · Child · Tae Kwon Do.

## INTRODUCTION

Lumbar disc herniations are rare in children and adolescents. Although the true incidence is not known, the incidence of lumbar disc herniation in children and adolescents has been reported to be less than 2.9%<sup>2)</sup>. Moreover, there have been only six cases of lumbar disc herniation in children younger than 10 years of age reported in the English literature<sup>1,10-14)</sup>. The clinical presentation and etiology of lumbar disc herniation in children may be different from adults. Traumatic or sports related injury constitutes the main causes of disc herniation; this is different from the adult where degenerative changes are the dominant etiology. Here, a 7-year-old Tae Kwon Do (Korean martial art) athletic child with a lumbar disc herniation is reported. The clinical features, differential diagnosis, and the importance of conservative treatment in children are discussed with a review of the literature.

## CASE REPORT

A 7-year-old boy, with blue belt in Tae Kwon Do, present-

ed with severe back pain and leg pain radiating to the left buttock and medial thigh. The pain started seven days prior to presentation and it was attributed to the jumping kick without warm-up; he was a trainee of Tae Kwon Do for two years before hospital admission. The pain was aggravated when the child tried to stand up and after mild exertion. On physical examination, the child showed a flattened lumbar lordosis. During lumbar flexion, he could not bend and was not able to touch his knees with the tip of his fingers due to back and left buttock pain. The left lateral flexion was more restricted than on the right side due to the left buttock pain. There was apparent muscular spasm and the straight leg raising test (SLRT) was positive when the left leg was lifted 30 degrees from the bed (free/30°). The motor strength was intact but the patient complained of marked hypesthesia on the medial thigh of the left leg. The Patrick (Faber) test was unremarkable. Simple radiographs revealed a reduced lumbar lordotic curve (Fig. 1). Magnetic resonance imaging (MRI) of the lumbar spine showed a left posterolateral L3-L4 disc herniation with severe degenerative changes at the L2-L3, L3-L4 and L4-L5 levels. Because of our limited experience with lumbar disc herniation in this age group as well as the parents' wishes, the patient was treated conservatively with anti-inflammatory medication, muscle relaxants, and bed rest initially. Two weeks later, the child could touch his knees with the tip of his fingers and there was a marked reduction of the muscular tenderness. The left SLRT was positive at 45

• Received : February 17, 2010 • Revised : August 26, 2010  
• Accepted : December 21, 2010  
• Address for reprints : Seok Won Kim, M.D.  
Department of Neurosurgery, School of Medicine, Chosun University,  
588 Seoseok-dong, Dong-gu, Gwangju 501-717, Korea  
Tel : +82-62-220-3126, Fax : +82-62-227-4575  
E-mail : ns64902@hanmail.net

degrees. The patient was transferred to the rehabilitation department for more aggressive therapy. Intermittent lumbar traction and side posture lumbar spinal manipulation therapy were added to the regimen two times per week. At the end of two months, the child was able to touch his ankles with the tip of his fingers. The left SLRT was positive at 70 degrees. Suspension manual therapy (SMT) and exercises two times per week for the next four weeks were continued. At the end of three months, the patient was nearly recovered and could start slight running. At this time, the left SLR showed no restriction. At the six months follow up, he was pain free with no restriction of the left leg. However, discontinuation of Tae Kwon Do was recommended due to the burden to his lumbar spine.

## DISCUSSION

The incidence of lumbar disc herniation in adolescents and children is very low; it accounts for 0.5% to 3.8% of cases with herniated discs in a large series<sup>9,14</sup>. Moreover, the occurrence of lumbar disc herniation in patients less than 10 years of age is extremely rare. There have been only six case reports in the English literature of patients younger than 10 years of age (Table 1). The clinical presentation of lumbar disc herniation is not always the same for young children and adults. Children with lumbar disc herniation may have no apparent radiating leg pain or signs of neurological deficits<sup>9</sup>. This may contribute to the delay of the diagnosis in children. The rate of trauma is increased among adolescents and children. Sports related activity and obesity have also been etiologic factors for lumbar disc herniation in adolescents and children<sup>5</sup>. In the present case, the precipitating factor was the flying hooking kick without warm-up. This kick includes jumping from a standing position, 90 degrees rotation of the trunk in the air and execution of the kick at the highest point of the jump. This causes rotation and flexion of the lumbar spine. The annulus fibrosis of the lumbar spine is most vulnerable during rotation and flexion. The other contributing factor might have been the landing from the jump, which results in compressive forces acting on the intervertebral disc. In this case, the combination of these forces probably caused the lumbar

disc herniation and a history of repetitive trauma was likely the cause of the degenerative changes at multiple levels of the spine. The important disorders to rule out are apophyseal ring fractures, infections and tumors of the spine causing a

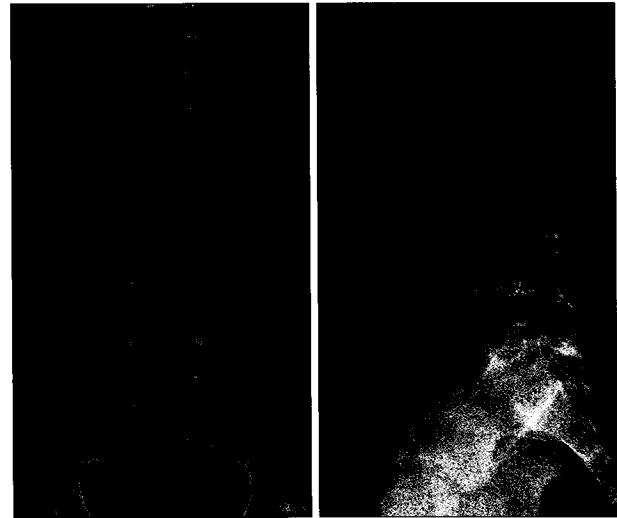


Fig. 1. Simple radiographs showed the decreased lumbar lordosis as a result of muscular spasm and the antalgic posture of the patient.

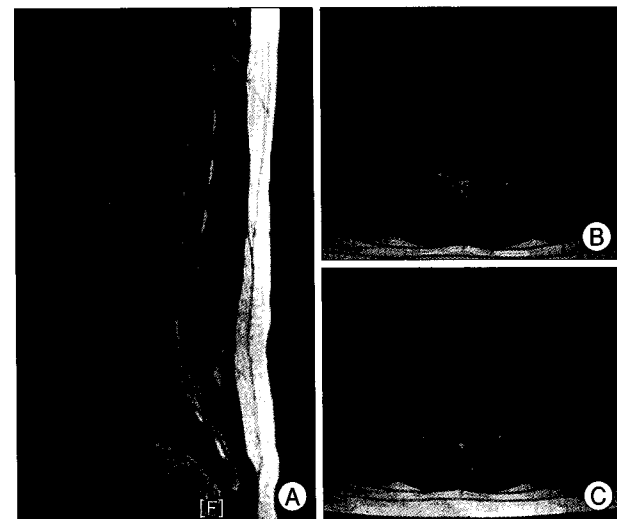


Fig. 2. Magnetic resonance images of the patient. A : T2 sagittal magnetic resonance image reveals severe degenerative change at L2-L3, L3-L4, and L4-L5 levels and disc protrusion at L3-L4 level. B and C : T1 and T2 axial magnetic resonance images show left posterolateral disc protrusion at L3-L4 level.

Table 1. Previously reported cases of lumbar disc herniation in children younger than 9 years old

| Reference number | Age/Sex | Trauma or sports injury         | Level | Operation | Follow up | Result |
|------------------|---------|---------------------------------|-------|-----------|-----------|--------|
| 1                | 1/M     | Fall from the standing position | L5-S1 | Yes       | 3 months  | Good   |
| 10               | 3.8/M   | Arising from seat               | L4-L5 | Yes       | 2 weeks   | Good   |
| 11               | 9/F     | No                              | L4-L5 | Yes       | 6 years   | Good   |
| 12               | 9/M     | Sports                          | L4-L5 | Yes       | 1 year    | Good   |
| 13               | 6/M     | Car accident                    | L5-S1 | Yes       | 3 months  | Good   |
| 14               | 2.5/M   | Fall from cradle                | L4-L5 | Yes       | 7 years   | Good   |
| Present case     | 7/M     | Sports                          | L3-L4 | No        | 6 months  | Good   |

radiculopathy. The apophyseal ring fracture does not undergo complete osseous union with the vertebral body until 18 years of age. Therefore, the junction is weaker than in adults. This weakness of the ring fracture might have been associated with lumbar disc herniation in young patients<sup>15)</sup>. Other causes of radiculopathy in children include infections and intraspinal tumors. Although no disease entity is absolutely specific to any specific age group, some generalizations can be made to help determine the most likely diagnosis. Discitis and vertebral osteomyelitis are more common in children under 10 years of age. The neoplastic conditions in this age group include: eosinophilic granuloma, leukemia, neuroblastoma, and astrocytoma<sup>7)</sup>. In this case, apophyseal ring fracture and discitis were ruled out by laboratory studies, radiographs, and MRI. MRI can also provide a comprehensive examination of the entire lumbar spine, including assessment of the conus medullaris and cauda equina. Bulos<sup>3)</sup> reported failure of conservative treatment, bed rest, in seven out of eight teenager patients. Ishihara et al.<sup>9)</sup> and Kurihara et al.<sup>11)</sup> also advised against conservative treatment for lumbar disc herniation in young patients, and advocated surgical treatment for prompt return to the activities of daily living. Moreover, all previously reported cases of lumbar disc herniation in children nine years of age or less showed good results with surgical treatment. However, conservative treatment should be recommended as the initial approach to lumbar disc herniation with no significant neurological deficits. Namely, the neurological status of the patient is an important factor to consider in deciding on the most appropriate treatment. Surgery is not recommended for during the first 6-12 weeks due to the possibility of favorable outcome. Many investigators have reported success in the treatment of adolescent lumbar disc herniation using: bed rest, heat, analgesics, corsets, spinal manipulation and other physical modalities<sup>4,8)</sup>. Conservative treatment is also a reasonable treatment option in young children that present with no significant neurological deficits; it can reduce the frequency of invasive procedures and the associated risks while leading to a spontaneous and complete recovery.

## CONCLUSION

The possibility of lumbar disc herniation and degenerative changes related to sports injuries should be kept in mind in even a young child. Conservative treatment is a reasonable treatment option in young children with no significant neurological deficits.

## References

1. Benifla M, Melamed I, Barrely R, Aloushin A, Shelef I : Unilateral partial hemilaminectomy for disc removal in a 1-year-old child. *J Neurosurg Pediatr* 2 : 133-135, 2008
2. Bradford DS, Garcia A : Lumbar intervertebral disk herniations in children and adolescents. *Orthop Clin North Am* 2 : 583-592, 1971
3. Bulos S : Herniated intervertebral lumbar disc in the teenager. *J bone J surgery* 55 : 273-278, 1973
4. Bunnell WP : Back pain in children. *Orthop Clin North Am* 13 : 587-604, 1982
5. DeOrio JK, Bianco AJ Jr : Lumbar disc excision in children and adolescents. *J Bone Joint Surg Am* 64 : 991-996, 1982
6. Ghabrial YA, Tarrant MJ : Adolescent lumbar disc prolapsed. *Acta Orthop Scand* 60 : 174-176, 1989
7. Ginsburg GM, Bassett GS : Back pain in children and adolescents : Evaluation and differential diagnosis. *J Am Acad Orthop Surg* 5 : 67-78, 1997
8. Hession EF, and Donald GD : Treatment of multiple lumbar disc herniation in an adolescent athlete utilizing flexion distraction and rotational manipulation. *JMPT* 16 : 185-192, 1993
9. Ishihara H, Matsui H, Hirano N, Tsuji H : Lumbar intervertebral disc herniation in children less than 16 years of age. Long-term follow-up study of surgically managed cases. *Spine (Phila Pa 1976)* 22 : 2044-2049, 1997
10. King AB : Surgical removal of a ruptured intervertebral disc in early childhood. *J Pediatr* 55 : 57-62, 1959
11. Kurihara A, Kataoka O : Lumbar disc herniation in children and adolescents. A review of 70 operated cases and their minimum 5-year follow-up studies. *Spine (Phila Pa 1976)* 5 : 443-451, 1980
12. MacGee EE : Protruded lumbar disc in a 9-year-old boy. *J Pediatr* 73 : 418-419, 1968
13. Martínez-Lage JF, Fernández Cornejo V, López F, Poza M : Lumbar disc herniation in early childhood : case report and literature review. *Childs Nerv Syst* 19 : 258-260, 2003
14. Revuelta R, De Juambelz PP, Fernandez B, Flores JA : Lumbar disc herniation in a 27-month-old child. Case report. *J Neurosurg (1 Suppl)* 92 : 98-100, 2000
15. Tibble AC, Cote p, Cassidy JD, Donat J : Adolescent apophyseal ring fracture simulating lumbar disc herniation : a case report. *JCCA* 36 : 11-16, 1992