

## 뇌하수체저하증 소아에서 발생한 비알코올성 지방간질환

서울대학교 의과대학 소아과학교실, \*인제대학교 일산백병원 소아과학교실  
윤정민 · 고재성 · 서정기 · 신충호 · 양세원 · 문진수\* · 양혜란 · 장주영

### Nonalcoholic Fatty Liver Disease in Children with Hypopituitarism

Jung Min Yoon, M.D., Jae Sung Ko, M.D., Jeong Kee Seo, M.D.,  
Choong Ho Shin, M.D., Sei Won Yang, M.D., Jin Soo Moon, M.D.\*,  
Hye Ran Yang, M.D. and Ju Young Chang, M.D.

Department of Pediatrics, Seoul National University College of Medicine, Seoul,  
\*Department of Pediatrics, Ilsan Paik Hospital, Inje University, Goyang, Korea

**Purpose:** It has been reported that children with hypopituitarism have features of metabolic syndrome, including obesity, impaired glucose tolerance, and dyslipidemia. The aim of this study was to investigate the clinical features and liver histology of pediatric non-alcoholic fatty liver disease (NAFLD) associated with hypopituitarism.

**Methods:** We reviewed the clinical data of 11 children diagnosed with NAFLD among patients with hypopituitarism.

**Results:** The mean age at the time of diagnosis of hypopituitarism was  $10.4 \pm 3.2$  years, and the mean age at the time of diagnosis of NAFLD was  $13.1 \pm 2.7$  years. A craniopharyngioma was the most common cause of pituitary dysfunction. At the time of diagnosis of NAFLD, 9 patients (82%) had a body mass index greater than the 85th percentile, 5 patients (45%) had elevated fasting blood glucose levels, and 9 patients (82%) had hypertriglyceridemia. The mean height SD score was significantly lower at the time of diagnosis of NAFLD than at the time of diagnosis of hypopituitarism. Of the six patients who were biopsied, one had cirrhosis, two had non-alcoholic steatohepatitis (NASH) with bridging fibrosis, two had NASH with mild portal fibrosis, and one had simple steatosis.

**Conclusion:** Children with hypopituitarism are at risk of short stature, obesity, dyslipidemia, and NAFLD. The early diagnosis of NAFLD is important in children with hypopituitarism because advanced fibrosis is common. (*Korean J Pediatr Gastroenterol Nutr* 2010; 13: 51~57)

**Key Words:** Child, Fatty liver, Hypopituitarism, Obesity

Received : February 1, 2010, Accepted : March 3, 2010

Responsible author : Jae Sung Ko, M.D., Department of Pediatrics, Seoul National University Hospital, 28, Yongon-dong, Jongro-gu, Seoul 110-744, Korea

Tel: +82-2-20722197, Fax: +82-2-7433455, E-mail: kojs@snu.ac.kr

## INTRODUCTION

With the increasing prevalence of pediatric obesity, nonalcoholic fatty liver disease (NAFLD) has become a common cause of chronic liver disease in the preadolescent and adolescent age groups<sup>1</sup>. The spectrum of NAFLD extends from simple steatosis to nonalcoholic steatohepatitis (NASH) and cirrhosis. NASH is defined as a fatty liver disease that causes liver inflammation and varying degrees of hepatic fibrosis. Simple steatosis has a relatively benign course, whereas NASH can progress to cirrhosis<sup>2</sup>. NAFLD is associated with abdominal obesity, insulin resistance and features of metabolic syndrome<sup>3</sup>.

Children and adolescents with hypopituitarism have features of metabolic syndrome, including obesity, insulin resistance and dyslipidemia<sup>4</sup>. Adults with hypothalamic and pituitary dysfunction are at risk of developing NAFLD with cirrhosis, which increases the risk of liver-related death<sup>5,6</sup>. A few case reports have described the development of NASH in children with panhypopituitarism<sup>7~11</sup>. We investigated the clinical features and liver histology of pediatric NAFLD associated with hypopituitarism.

## MATERIALS AND METHODS

### 1. Patients

Children included in this study were diagnosed as having NAFLD among patients with hypopituitarism at the Seoul National University Children's Hospital between January 2000 and July 2009. All subjects were diagnosed with NAFLD after exclusion of other causes of chronic hepatitis, including hepatitis A, B, and C viruses, autoimmune hepatitis, Wilson's disease, drug toxicity, total parenteral nutrition and chronic alcohol intake. Diagnosis of NAFLD was based on evidence of a fatty liver from a percutaneous liver biopsy or abdominal computerized tomography (CT). Fatty liver

was diagnosed from unenhanced CT images when the liver minus spleen attenuation difference was less than or equal to  $-10$  H. Percutaneous liver biopsy was performed in 6 patients. Approval for this study was obtained from the Ethical Committee of the Seoul National University Hospital, and all patients or responsible guardians provided written informed consent.

### 2. Demographics and laboratory assessment

Height, weight, serum concentrations of aspartate aminotransferase (AST), alanine aminotransferase (ALT) and glucose and lipid profiles were measured. Body mass index (BMI) was calculated as weight (kg) divided by the height (m) squared. Obesity was defined as a BMI  $>95^{\text{th}}$  percentile, adjusted for age and sex; overweight was defined as a BMI between the  $85^{\text{th}}$  and  $95^{\text{th}}$  percentiles.

Fasting hypertriglyceridemia was defined as a serum triglyceride level  $>110$  mg/dL. Fasting hyperinsulinemia was defined as a serum insulin level  $>20$   $\mu$ IU/mL.

In childhood, GH deficiency was diagnosed if the GH peak was less than  $5$   $\mu$ g/L on two provocative tests using L-dopa, clonidine, glucagon or insulin. We performed GH stimulation test 1 year after completion of tumor therapy. If parents agreed to receive the GH, we started GH treatment in a dose of  $15$  IU/m<sup>2</sup> per week. We reassessed GH secretion using insulin in adolescents who attained the final height. If peak GH concentration was less than  $3$   $\mu$ g/L, childhood-onset adult GH deficiency was diagnosed and GH was administered in a dose of  $0.006 \sim 0.012$  mg/kg per day.

Secondary hypoadrenalism was diagnosed if peak cortisol less than  $18$   $\mu$ g/dL after insulin-induced hypoglycemia or blunted ACTH response after corticotrophin-releasing hormone administration. TSH deficiency was defined by low free T4 level without appropriate elevation of TSH after thyrotropin-releasing hormone administration. Hypogonadotropic hypogonadism was defined by low sex steroid level without appropriate LH/FSH elevation after gonadotropin releasing hormone administration after the age of 10 years (female) or 12 years (male).

Liver biopsy specimens were evaluated according to the classification of Brunt et al<sup>12</sup>.

### 3. Statistical analysis

Continuous data are presented as the mean±SD. Paired t-test was used for comparison of height SD scores. Statistical significance was defined as  $p < 0.05$ . The data were analyzed using the SPSS 12.0 software program (SPSS, Chicago, IL, USA).

## RESULTS

### 1. Subjects

Of the 11 children, seven were male. The mean age at the time of diagnosis of hypopituitarism was 10.4±3.2 years and the mean age at the time of diagnosis of NAFLD was 13.1±2.7 years.

Craniopharyngioma was the most common cause of pituitary dysfunction, affecting seven patients (64%). Two patients had germ cell tumors, one had a medulloblastoma and one had idiopathic hypopituitarism. All patients with tumors underwent surgery, three of whom received additional radiotherapy and chemotherapy. All patients were diagnosed with hypoadrenalism and hypothyroidism and received Levo-thyroxine and hydrocortisone with a

dose of less than 12 mg/m<sup>2</sup>. Desmopressin was administered to eight patients. All patients presented with childhood-onset GH deficiency. Five children were treated with GH in their childhood. GH was not administered to six children (residual tumor mass in 2 children, parental refusal in 2, maintenance of linear growth in 1, attainment of the final adult height in 1).

### 2. Metabolic indexes

At the time of diagnosis of hypopituitarism, five patients (41%) had a BMI greater than the 85<sup>th</sup> percentile. At the time of diagnosis of NAFLD, nine patients (82%) had a BMI greater than the 85<sup>th</sup> percentile. Six patients were overweight and three were obese. The mean height SD score was significantly lower at the time of diagnosis of NAFLD ( $-1.47 \pm 1.81$ ) than at the time of diagnosis of hypopituitarism ( $-0.89 \pm 1.16$ ). NAFLD was diagnosed 2.7±2.7 years after the diagnosis of hypopituitarism (Table 1). At the time of diagnosis of hypopituitarism, liver enzyme levels were available for nine patients, five of whom had levels within the normal range. All patients except one had developed elevated liver enzymes by the time of diagnosis of NAFLD (Table 2).

Fasting blood glucose level at the time of diagnosis of hypopituitarism was elevated in one patient. At the time

**Table 1.** Clinical Characteristics and Anthropometry

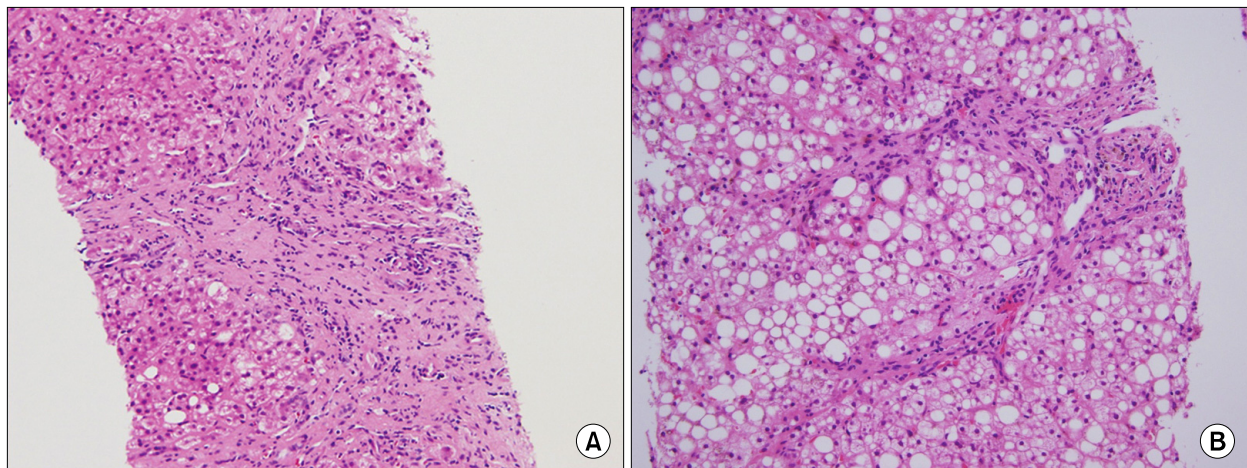
Patient No.	Sex	Cause	Age at diagnosis of hypopituitarism	Years between diagnoses	Height SD score	BMI 1 (kg/m <sup>2</sup> )	BMI 2 (kg/m <sup>2</sup> )
1	M	Medulloblastoma	7	9	-3.98	17	25.5
2	M	Craniopharyngioma	13	1	-0.63	21.6	25.3
3	F	Germ cell tumor	12	3	-2.38	18	20
4	M	Craniopharyngioma	8	3	-1.05	15	23
5	M	Craniopharyngioma	11	0	-3.11	20	22
6	M	Craniopharyngioma	5	4	-0.6	18	20.4
7	M	Craniopharyngioma	15	1	0.52	25.8	26
8	M	Idiopathic	11	5	-5.08	25.8	30.5
9	F	Germ cell tumor	14	0.4	0.18	19.7	21.7
10	F	Craniopharyngioma	11	0.3	-0.73	24.2	26.2
11	F	Craniopharyngioma	7	3	-0.15	19	26.5
Mean±SD			10.4±3.2	2.7±2.7	-1.47±1.81	20.4±3.6	24.3±3.2

SD: standard deviation, BMI: body mass index, M: male, F: female. Height SDscores were measured at the time of diagnosis of NAFLD. BMI 1 and BMI 2 were measured at the time of diagnosis of hypopituitarism and NAFLD, respectively.

**Table 2.** Laboratory Data and Liver Histologic Findings at the Time of Diagnosis of NAFLD

Patient No.	Alanine aminotransferase (IU/L)	Triglyceride (mg/dL)	Glucose (mg/dL)	Insulin ( $\mu$ U/mL)	Steatosis on liver biopsy	Fibrosis on liver biopsy
1	175	662	124	22.5	Moderate	Bridging
2	186	267	89	19.2	Moderate	Mild
3	261	164	118	62.4	Mild	Bridging
4	81	404	99	17.7	Mild	Mild
5	70	85	80	12.3	Mild	No
6	177	129	90	10.7		
7	143	370	124	24		
8	68	232	155	ND	Mild	Cirrhosis
9	109	90	106	18		
10	55	294	116	27.7		
11	18	251	88	12.7		

ND: not done.



**Fig. 1.** Liver histologic findings show micro-nodular cirrhotic changes (A) and bridging fibrosis (B) (H&E,  $\times 200$ ).

of diagnosis of NAFLD, fasting blood glucose level was elevated in five patients (45%), of whom two had diabetes mellitus and three had glucose intolerance (fasting glucose  $> 110$  mg/dL). At the time of diagnosis of NAFLD, fasting triglyceride levels were elevated in nine patients (82%). At the time of diagnosis of NAFLD, acanthosis nigricans was observed in three patients and fasting insulin levels were elevated in four patients (Table 2).

### 3. Histology of NAFLD

Six patients were diagnosed with NAFLD from liver

biopsy results. One patient was cirrhotic (Fig. 1A), two had NASH with bridging fibrosis (Fig. 1B), two had NASH with mild portal fibrosis and one had simple steatosis. Two with bridging fibrosis had short statures (height SD score less than  $-2.0$ ) and fasting hyperinsulinemia; one had diabetes. One cirrhotic patient had idiopathic hypopituitarism, which was diagnosed at age 11. He had severe growth retardation, early-onset severe obesity and diabetes mellitus. He is now in a vegetative state because of intracerebral hemorrhage. Three patients with no fibrosis or mild fibrosis had normal fasting insulin levels.

**Table 3.** Effects of GH Replacement in Adolescents with Adult GH Deficiency

	Body mass index (kg/m <sup>2</sup> )	Aspartate aminotransferase (IU/L)	Alanine aminotransferase (IU/L)
Pre-GH	25.1±2.9	113.3±72.1	139.6±101.8
Post-GH	25.5±4.8	45.6±21.1	53.4±35.3

GH: growth hormone.

#### 4. GH replacement therapy

The childhood-onset adult GH deficiency was detected in seven adolescents who attained the final adult height. GH replacement therapy was administered to these adolescents. Serum AST level in adolescents with childhood-onset adult GH deficiency decreased from 113.3±72.1 IU/L to 45.6±21.1 IU/L after GH therapy ( $p < 0.05$ ). Serum ALT level decreased significantly from 139.6±101.8 IU/L to 53.4±35.3 IU/L after GH therapy. There was no significant change in mean BMI (25.1±2.9 vs. 25.5±4.8) after GH therapy (Table 3).

## DISCUSSION

An extreme degree of obesity may develop in association with a hypothalamic tumor. Hypothalamic damage resulting from a tumor, surgery, or radiation is the primary cause of obesity in survivors of childhood brain tumors<sup>13</sup>. In this study, craniopharyngioma was the most common cause of NAFLD associated with hypopituitarism. Of all childhood brain tumors, craniopharyngioma is associated with the highest risk of obesity. Approximately 50% of children who are surgically treated for craniopharyngioma are obese at follow-up<sup>14</sup>.

Adults with GH deficiency, with or without hypopituitarism, have features of metabolic syndrome, including excess abdominal adiposity, insulin resistance and dyslipidemia<sup>15,16</sup>. Kaji et al. reported that NAFLD was the third most common complication after hypercholesterolemia and hypertriglyceridemia in adults with GH deficiency<sup>17</sup>. Children who develop hypopituitarism after

craniopharyngioma surgery also have features of metabolic syndrome, including high abdominal fat and hypertriglyceridemia<sup>4</sup>. In this study, nine (82%) of 11 children were overweight or obese at the time of diagnosis of NAFLD. Hypertriglyceridemia and fasting hyperinsulinemia were detected in nine (82%) and four (36%) children, respectively. The mean interval between diagnosis of hypopituitarism and development of NAFLD was 2.7 years, which is shorter than the 6.4-year interval reported by Adams et al. for a group that included adults. They described 21 patients with hypothalamic or pituitary dysfunction that was accompanied by excessive weight gain, impaired glucose tolerance, dyslipidemia and NAFLD. Biopsies were taken from 10 patients, of whom six had cirrhosis<sup>5</sup>. Previously we reported that the prevalence of advanced fibrosis was 8.8% in children with NAFLD associated with simple obesity<sup>18</sup>. So we believed that the liver disease was more severe in children with NAFLD associated with hypopituitarism; 50% of the patients biopsied had advanced fibrosis in this study.

In this study, children with bridging fibrosis or cirrhosis had short statures and fasting hyperinsulinemia. This suggests that GH deficiency and insulin resistance may play an important role in the progression of NASH. The hepatic effects of hypothalamic and pituitary diseases seem to be primarily mediated by GH deficiency. The metabolic effects and subsequent development of obesity that occur in GH-deficient individuals result in the development of NASH<sup>19</sup>. Patients with NASH demonstrate similarities to those with adult GH deficiency and patients with NAFLD have lower GH levels compared with controls<sup>20</sup>. Adult patients with anterior pituitary dysfunction and GH deficiency have hepatic steatosis more frequently than those with anterior pituitary deficiency without GH deficiency, which indicates that GH deficiency is a risk factor for NAFLD<sup>21</sup>. GH replacement reduces total body fat and normalizes insulin sensitivity in GH-deficient adults<sup>16</sup>.

Fukuda et al. demonstrated that 29% of adults who had been diagnosed with childhood-onset GH deficiency

developed NAFLD within 21 years of discontinuation of GH therapy. They suggested that lifelong GH replacement might be important for improving the overall metabolic profile<sup>22</sup>. There is a case report of an adult with hypopituitarism who suffered from NAFLD, which improved with GH treatment<sup>9</sup>. Administration of GH replacement therapy to an adult patient with hypopituitarism reversed steatosis, inflammation and fibrosis in the liver according to histology<sup>23</sup>. This improvement was associated with a marked reduction in oxidative stress in the liver, suggesting that GH plays an essential role in metabolic and redox regulation in the liver, which is consistent with previous findings showing that GH replacement therapy reduced free radical levels<sup>24</sup>.

In the present study, GH therapy improved liver dysfunction, but had no salutary effect on BMI. This finding suggests that GH may affect metabolic profiles directly rather than indirectly via weight reduction. However, liver histology between pre- and post-GH treatment was not compared. Further studies are necessary to determine whether GH replacement will ameliorate the degree of fibrosis or steatosis.

Hypothyroidism induces dyslipidemia and obesity, and can lead to the development of NASH<sup>25</sup>. All of our patients received thyroid hormones after the diagnosis of hypopituitarism and had normal thyroid function tests. The development of NAFLD is less likely associated with hypothyroidism in this study.

In conclusion, children with hypopituitarism are at risk of short stature, obesity, dyslipidemia and NAFLD. Early diagnosis of NAFLD is important in children with hypopituitarism because advanced fibrosis is common. The role of GH in the development of NAFLD in patients with hypopituitarism remains to be investigated.

## 요 약

**목 적:** 뇌하수체저하증 환아들은 비만, 당불내성, 고지질혈증을 포함한 대사증후군의 양상을 보인다. 이 연구의 목적은 뇌하수체저하증과 연관된 소아 지방간질

환의 임상 양상과 간조직 소견을 알아보는 것이다.

**방 법:** 뇌하수체저하증 환자 중에서 비알코올성 지방간질환으로 진단된 소아 11명의 임상자료를 조사하였다.

**결 과:** 뇌하수체저하증 진단 시 연령은  $10.4 \pm 3.2$ 세였다. 지방간질환 진단 시 연령은  $13.1 \pm 2.7$ 세였다. 두개인 두종이 뇌하수체저하증의 기저질환 중 가장 흔하였다. 지방간질환 진단 당시 체질량지수 85백분위수 이상이 9명(82%), 금식 시 고혈당이 5명(45%), 고지질혈증이 9명(82%)에서 발견되었다. 신장의 표준편차 점수의 평균은 뇌하수체저하증 진단 시보다 지방간질환 진단시에 유의하게 낮았다. 간생검을 실시한 6명 중에서 1명은 간경변, 2명은 연결 섬유화가 동반된 지방간염, 2명은 경도의 간문맥 섬유화가 동반된 지방간염, 1명은 단순 지방간으로 진단되었다.

**결 론:** 뇌하수체저하증을 가진 소아는 저신장, 비만, 고지질혈증, 비알코올성 지방간질환이 발생할 위험이 높다. 간조직의 진행된 섬유화가 흔하기 때문에 뇌하수체저하증 환아에서 지방간질환의 조기 진단이 중요하다.

## REFERENCES

- 1) Patton HM, Sirlin C, Behling C, Middleton M, Schwimmer JB, Lavine JE. Pediatric nonalcoholic fatty liver disease: a critical appraisal of current data and implications for future research. *J Pediatr Gastroenterol Nutr* 2006;43:413-27.
- 2) Hubscher SG. Histological assessment of non-alcoholic fatty liver disease. *Histopathology* 2006;49:450-65.
- 3) Manco M, Marcellini M, Devito R, Comparcola D, Sartorelli MR, Nobili V. Metabolic syndrome and liver histology in paediatric non-alcoholic steatohepatitis. *Int J Obes (Lond)* 2008;32:381-7.
- 4) Srinivasan S, Ogle GD, Garnett SP, Briody JN, Lee JW, Cowell CT. Features of the metabolic syndrome after childhood craniopharyngioma. *J Clin Endocrinol Metab* 2004;89:81-6.
- 5) Adams LA, Feldstein A, Lindor KD, Angulo P. Nonalcoholic fatty liver disease among patients with hypothalamic and pituitary dysfunction. *Hepatology* 2004;39:909-14.
- 6) 이한효, 변영혜, 신원용, 김성환, 송문희, 조윤주 등. 뇌하수체저하증과 동반된 원인 미상의 간경변증 1예. *대*

- 한내과학회지 2007;72:116-20.
- 7) Altuntas B, Ozcakar B, Bideci A, Cinaz P. Cirrhotic outcome in patients with craniopharyngioma. *J Pediatr Endocrinol Metab* 2002;15:1057-8.
  - 8) Basenau D, Stehphani U, Fischer G. Development of complete liver cirrhosis in hyperphagia-induced fatty liver. *Klin Padiatr* 1994;206:62-4.
  - 9) Takano S, Kanzaki S, Sato M, Kubo T, Seino Y. Effect of growth hormone on fatty liver in panhypopituitarism. *Arch Dis Child* 1997;76:537-8.
  - 10) Nakajima K, Hashimoto E, Kaneda H, Tokushige K, Shiratori K, Hizuka N, et al. Pediatric nonalcoholic steatohepatitis associated with hypopituitarism. *J Gastroenterol* 2005;40:312-5.
  - 11) 박지용, 고재성, 서정기, 이 란, 신중호, 강경훈 등. 청소년기에 간경화증으로 진행된 비알콜성 지방간질환 1 예. *대한소아소화기영양학회지* 2008;11:204-9.
  - 12) Brunt EM, Janney CG, Di Bisceglie AM, Neuschwander-Tetri BA, Bacon BR. Nonalcoholic steatohepatitis: a proposal for grading and staging the histological lesions. *Am J Gastroenterol* 1999;94:2467-74.
  - 13) Lustig RH, Post SR, Srivannaboon K, Rose SR, Danish RK, Burghen GA, et al. Risk factors for the development of obesity in children surviving brain tumors. *J Clin Endocrinol Metab* 2003;88:611-6.
  - 14) Muller HL, Bueb K, Bartels U, Roth C, Harz K, Graf N, et al. Obesity after childhood craniopharyngioma--German multicenter study on pre-operative risk factors and quality of life. *Klin Padiatr* 2001;213:244-9.
  - 15) Johansson JO, Fowelin J, Landin K, Lager I, Bengtsson BA. Growth hormone-deficient adults are insulin-resistant. *Metabolism* 1995;44:1126-9.
  - 16) Hwu CM, Kwok CF, Lai TY, Shih KC, Lee TS, Hsiao LC, et al. Growth hormone (GH) replacement reduces total body fat and normalizes insulin sensitivity in GH-deficient adults: a report of one-year clinical experience. *J Clin Endocrinol Metab* 1997;82:3285-92.
  - 17) Kaji H, Sakurai T, Iguchi G, Murata M, Kishimoto M, Yoshioka S, et al. Adult growth hormone deficiency in Japan: results of investigation by questionnaire. *Endocr J* 2002;49:597-604.
  - 18) Ko JS, Yoon JM, Yang HR, Myung JK, Kim HR, Kang GH, et al. Clinical and histological features of non-alcoholic fatty liver disease in children. *Dig Dis Sci* 2009;54:2225-30.
  - 19) Loria P, Carulli L, Bertolotti M, Lonardo A. Endocrine and liver interaction: the role of endocrine pathways in NASH. *Nat Rev Gastroenterol Hepatol* 2009;6:236-47.
  - 20) Lonardo A, Loria P, Leonardi F, Ganazzi D, Carulli N. Growth hormone plasma levels in nonalcoholic fatty liver disease. *Am J Gastroenterol* 2002;97:1071-2.
  - 21) Ichikawa T, Hamasaki K, Ishikawa H, Ejima E, Eguchi K, Nakao K. Non-alcoholic steatohepatitis and hepatic steatosis in patients with adult onset growth hormone deficiency. *Gut* 2003;52:914.
  - 22) Fukuda I, Hizuka N, Yasumoto K, Morita J, Kurimoto M, Takano K. Metabolic co-morbidities revealed in patients with childhood-onset adult GH deficiency after cessation of GH replacement therapy for short stature. *Endocr J* 2008;55:977-84.
  - 23) Takahashi Y, Iida K, Takahashi K, Yoshioka S, Fukuoka H, Takeno R, et al. Growth hormone reverses nonalcoholic steatohepatitis in a patient with adult growth hormone deficiency. *Gastroenterology* 2007;132:938-43.
  - 24) Evans LM, Davies JS, Anderson RA, Ellis GR, Jackson SK, Lewis MJ, et al. The effect of GH replacement therapy on endothelial function and oxidative stress in adult growth hormone deficiency. *Eur J Endocrinol* 2000;142:254-62.
  - 25) Liangpunsakul S, Chalasani N. Is hypothyroidism a risk factor for non-alcoholic steatohepatitis? *J Clin Gastroenterol* 2003;37:340-3.