

COMBINATION THERAPY USING GLOSSOPEXY AND RADIOFREQUENCY THERAPY IN PIERRE ROBIN SEQUENCE

Yu-Jin Oh, Horatiu Rotaru¹, Young-Wook Park, Kwang-Jun Kwon, Seong-Gon Kim, Min-Keun Kim

Department of Oral and Maxillofacial Surgery, College of Dentistry, Gangneung-Wonju National University, Gangneung, Korea

¹Department of Oral and Maxillofacial Surgery, Iuliu Hatieganu University of Medicine and Pharmacy, Cluj-Napoca, Romania

Abstract

Pierre Robin sequence (PRS) describes the clinical triad of micro- and/or retrognathia, glossoptosis and cleft soft palate. Glossopexy has been demonstrated to be an effective treatment in selected cases of obstruction caused by glossoptosis (generally 6 to 10 months of glossopexy period). If radiofrequency therapy (RF) can reduce tongue volume in PRS, it will be helpful in early releasing of the glossopexy. Two-day-old patient showed a PRS triad. Intermittent cyanosis, respiratory difficulty and feeding problems were also observed. The respiration was not improved and prolonged intubation increased the possibility of respiratory complications like pneumonia. The surgical intervention- glossopexy and RF was done 20 days after birth. We applied RF combined with conventional glossopexy and could get successful results while reducing the overall treatment time to 6 weeks. The follow-up until 12 months after birth was uneventful. Considering that early recovery is highly beneficial to PRS patients by reducing risks associated with glossopexy and low energy RF application is very simple and low risk to patient, our combination therapy should be considered for the treatment of airway problem related to PRS.

Key words: Pierre Robin sequence, Glossopexy, Radiofrequency therapy, Combination therapy

I . Introduction

Pierre Robin sequence (PRS) describes the clinical triad of micro- and/or retrognathia, glossoptosis and cleft soft palate.¹⁾ Glossopexy has been demonstrated to be an effective treatment in selected cases of obstruction caused by glossoptosis.²⁾ The exact timing of tongue release has not been defined, but generally 6 to 10 months of glossopexy period has been recommended.^{2,3)} During glossopexy, tongue movement is restricted. Therefore, subsequent speech and feeding problems may be raised.

The radiofrequency therapy (RF) has been applied to reduce the volume and the power of the skeletal muscles.^{4,5)} RF has been used for reducing tongue volume in the sleep apnea.⁴⁾ The complications related to RF have been minimal. If RF can reduce tongue volume in PRS, it will be helpful in early

releasing of the glossopexy. We present a new clinical trial using glossopexy and RF in PRS. Using this technique, we could reduce the duration of glossopexy.

II . Case report

Two-day-old patient showed a PRS triad: micrognathia, glossoptosis, and cleft palate. Intermittent cyanosis, respiratory difficulty and feeding problems were also observed. The patient received the endotracheal intubation and was observed for 18 days. The respiration was not improved and prolonged intubation increased the possibility of respiratory complications like pneumonia. Therefore, the surgical intervention was unavoidable in this case. The surgical intervention- glossopexy (Fig 1A) and RF was done 20 days after birth (Fig 1B, 1C). After perform-

ing glossopepy as previously described,²⁾ RF was applied to the tongue base and the genioglossus muscle (Fig 1B, 1C). The radiofrequency generator was NeuroTherm™JK4A (RDG Medical, Croydon, UK). The diameter of the electrode was 1.1 mm and it transmitted alternating current. The maximum temperature at the tip of the electrode was set at 70°C. The duration of each application of current was 120 second.

The wire suture for glossopepy was spontaneously released 4 weeks after the treatment. The patient could breathe in lateral position, but the oxygen sat-

uration was dropped in supine position. The glossopepy was applied again (Fig. 2A). Two weeks later, the wire suture was removed and the oxygen saturation of the patient was not influenced by the patient's head position. The airway was also successfully maintained without wire fixation (Fig. 2B). Ten months after birth, the patient readmitted for the treatment of pneumonia. The airway was completely maintained at 10 months after birth (Fig. 2C). After then, the follow-up until 12 months after birth was uneventful.

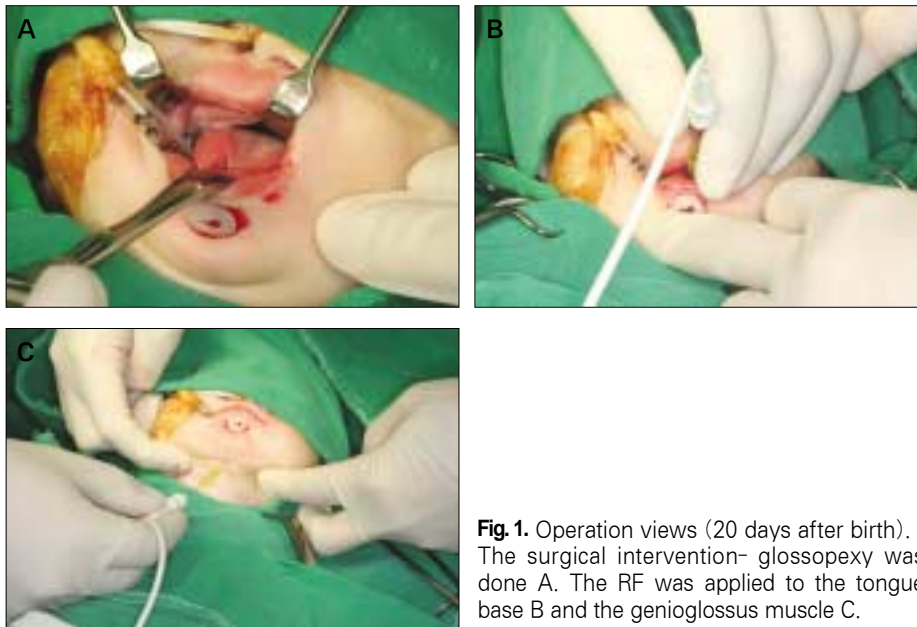

Fig. 1. Operation views (20 days after birth). The surgical intervention- glossopepy was done A. The RF was applied to the tongue base B and the genioglossus muscle C.

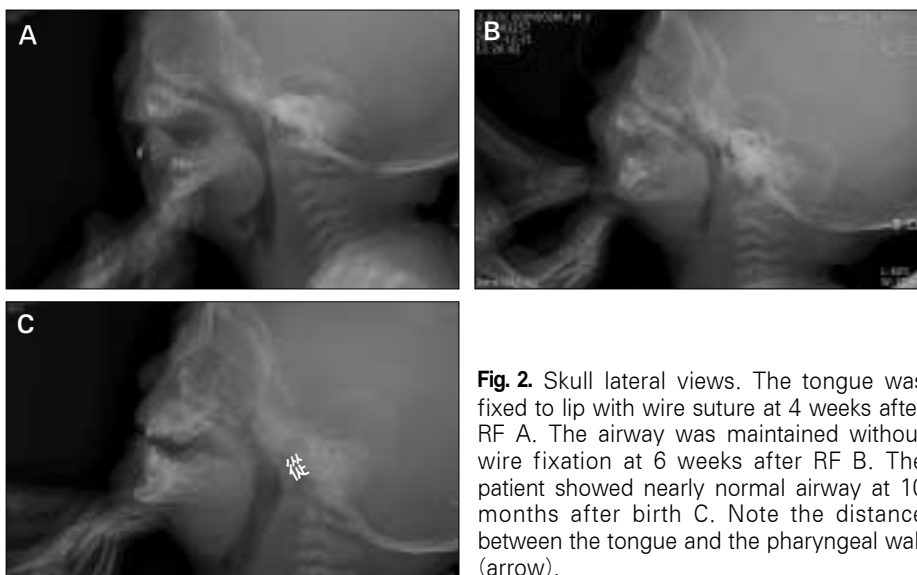


Fig. 2. Skull lateral views. The tongue was fixed to lip with wire suture at 4 weeks after RF A. The airway was maintained without wire fixation at 6 weeks after RF B. The patient showed nearly normal airway at 10 months after birth C. Note the distance between the tongue and the pharyngeal wall (arrow).

III. Discussion

One of the major problems in PRS is life-threatening airway obstruction.¹⁾ Early recovery from the airway obstruction is important in reducing patient's discomfort and minimizing further feeding and speech problem. We applied RF combined with conventional glossopepy and could get successful results while reducing the overall treatment time to 6 weeks.

Approaches advocated for treatment of airway obstruction in neonates with PRS include prone positioning,⁶⁾ glossopepy,^{2,3)} distraction osteogenesis,⁷⁾ and tracheotomy.⁸⁾ After glossopepy, catch-up growth of the mandible is shown in the form of weight velocity.⁹⁾ Though the effect of glossopepy on speech sound production has been reported as temporary,³⁾ maintaining the glossopepy up to 6-10 months may cause many problems such as feeding difficulties, adhesion dehiscence, and so on.⁹⁾ If the fixation is spontaneously released like our case and it is happened during staying home without notification, the patient's life will be in danger. Any removable device also has similar potential risk. The complications related to the glossopepy are also related to the prolonged retention of fixation. Therefore, reducing the overall fixation time and allowing self-respiration as soon as possible are highly important to save PRS patient.

RF has been used to obstructive sleep apnea,⁴⁾ masseteric hypertrophy,¹⁰⁾ and post-traumatic open bite.⁵⁾ RF can reduce the volume of the skeletal muscle in the applied area.^{4,10)} In order to widen the airway space, we applied RF on the tongue base. We also applied RF on the genioglossus muscle for reducing the anterior-posterior dimension of the muscle expecting anterior positioning of tongue during the scar contracture. The amount of the reduced volume is dependent on the applied energy and the number of the applications. In case of masseteric hypertrophy, RF is applied 21 times in each masseter muscle.¹⁰⁾ But too many applications may increase the incidence of abscess in the applied area.^{10,11)} For RF application to the infant, the applied energy should be limited. According to previous publication, the effect of RF appeared 4 to 6 weeks after.¹⁰⁾ In our presented case, the wire suture was successfully

removed 6 weeks after the treatment (Fig. 2B). The volumetric change after RF has been known to be stable.^{4,10)}

The RF may induce any potential complication in the infant. Until now, the complication related to RF has been infrequently reported.^{10,11)} Mostly, the complication has been observed in the patient with hepatoma and it has been liver abscess.¹¹⁾ Pneumonia has been presented after RF in the lung cancer.¹²⁾ For reducing tumor, excessive RF energy should be applied to the lesion. However, the size of RF lesion in our application was limited to 1.8 mm. As it was controlled by temperature sensor, the lesion size was not increased during RF application. The measurement of the impedance prevented wrong localization of the tip. Most abscess formation related to RF can be detected in early period after application in the applied site.^{10,11,12)} The pneumonia in our case might be induced by long-term intubation.¹³⁾ Therefore, any treatment which can reduce the intubation period must be done to reduce respiratory complications. The injection of botulinum toxin also has been proved its effect in reducing the muscular volume. However, its usage in the infant has been restricted for the potential risk to the respiratory muscle.¹⁴⁾ Therefore, well controlled RF application was safe method for the infant to reduce the muscular volume.

Considering that early recovery is highly beneficial to PRS patients by reducing risks associated with glossopepy and low energy RF application is very simple and low risk to patient, our combination therapy should be considered for the treatment of airway problem related to PRS.

References

1. Robin P : Glossoptosis due to atresia and hypotrophy of the mandible. *Am J Dis Child* 48 : 541, 1934.
2. Argamaso RV : Glossopepy for upper airway obstruction in Robin sequence. *Cleft Palate Craniofac J* 29 : 232, 1992.
3. LeBlanc SM : Golding-Kushner KJ : Effect of glossopepy on speech sound production in Robin sequence. *Cleft Palate Craniofac J* 29 : 239, 1992.
4. Welt S, Maurer JT, Hörmann K *et al* : Radiofrequency surgery of the tongue base in the treatment of snoring—a pilot study. *Sleep Breath* 11 : 39, 2007.
5. Choi SS, Rotaru H, Kim SG : Treatment of post-traumatic open bite by radiofrequency. *Br J Oral Maxillofac Surg* 45 : 311, 2007.
6. Sher AE : Mechanisms of airway obstruction in Robin

- sequence : implications for treatment. *Cleft Palate Craniofac J* 29 : 224, 1992.
7. Denny AD : Distraction osteogenesis in Pierre Robin neonates with airway obstruction. *Clin Plast Surg* 31 : 221, 2004.
 8. Myer CM, Reed JM, Cotton RT *et al* : Airway management in Pierre Robin sequence. *Otolaryngol Head Neck Surg* 118 : 630, 1998.
 9. Cozzi F, Totonelli G, Frediani S *et al* : The effect of glossopexy on weight velocity in infants with Pierre Robin syndrome. *J Pediatr Surg* 43 : 296, 2008.
 10. Park YJ, Jo YW, Bang SI *et al* : Radiofrequency volume reduction of gastrocnemius muscle hypertrophy for cosmetic purposes. *Aesthetic Plast Surg* 31 : 53, 2007.
 11. Akahane M, Koga H, Kato N *et al* : Complications of percutaneous radiofrequency ablation for hepato-cellular carcinoma : imaging spectrum and management. *Radiographics* 25 Suppl 1 : S57, 2005.
 12. Nomura M, Yamakado K, Nomoto Y *et al* : Complications after lung radiofrequency ablation: risk factors for lung inflammation. *Br J Radiol* 81 : 244, 2008.
 13. Holzapfel L, Chevret S, Madinier G *et al* : Influence of long-term oro- or nasotracheal intubation on nosocomial maxillary sinusitis and pneumonia: results of a prospective, randomized, clinical trial. *Crit Care Med* 21 : 1132, 1993.
 14. Partikian A, Mitchell WG : Iatrogenic botulism in a child with spastic quadriplegia. *J Child Neurol* 22 : 1235, 2007.

저자 연락처

우편번호 210-702
강원도 강릉시 지변동
강릉원주대학교 치과대학 구강악안면외과학교실
김성곤

원고 접수일 2010년 02월 09일
게재 확정일 2010년 03월 02일

Reprint Requests

Seong-Gon Kim

Department of Oral and Maxillofacial Surgery, College of Dentistry, Gangneung-Wonju National University
Jibeondong, Gangneung, Gangwon, 210-702, Korea
Tel: +82-33-640-2468 Fax: +82-33-640-3113
E-mail: epker@chollian.net

Paper received 09 February 2010
Paper accepted 02 March 2010