

## Clinical Article

# Transventricular Biopsy of Brain Tumor without Hydrocephalus Using Neuroendoscopy with Navigation

Ji Hye Song, M.D., Doo-Sik Kong, M.D., Ph.D., Ho Jun Seol, M.D., Ph.D., Hyung Jin Shin, M.D., Ph.D.

Department of Neurosurgery, Samsung Medical Center, Sungkyunkwan University School of Medicine, Seoul, Korea

**Objective** : It is usually difficult to perform the neuroendoscopic procedure in patients without hydrocephalus due to difficulties with ventricular cannulation. The purpose of this study was to find out the value of navigation guided neuroendoscopic biopsy in patients with peri- or intraventricular tumors without hydrocephalus.

**Methods** : Six patients with brain tumors without hydrocephalus underwent navigation-guided neuroendoscopic biopsy. The procedure was indicated for verification of the histological diagnosis of the neoplasm, which was planned to be treated by chemotherapy and/or radiotherapy as the first line treatment, or establishment of the pathological diagnosis for further choice of the most appropriate treatment strategy.

**Results** : Under the guidance of navigation, targeted lesion was successfully approached in all patients. Navigational tracking was especially helpful in entering small ventricles and in approaching the third ventricle through narrow foramen Monro. The histopathologic diagnosis was established in all of 6 patients : 2 germinomas, 2 astrocytomas, 1 dysembryoplastic neuroepithelial tumor and 1 pineocytoma. The tumor biopsy sites were pineal gland (n = 2), suprasellar area (n = 2), subcallosal area (n = 1) and thalamus (n = 1). There were no operative complications related to the endoscopic procedure.

**Conclusion** : Endoscopic biopsy or resection of peri- or intraventricular tumors in patients without hydrocephalus is feasible. Image-guided neuroendoscopic procedure improved the accuracy of the endoscopic approach and minimized brain trauma. The absence of ventriculomegaly in patients with brain tumor may not be served as a contraindication to endoscopic tumor biopsy.

**KEY WORDS** : Neuroendoscopy · Navigation · Without hydrocephalus.

## INTRODUCTION

As early as 1963, Guiot et al.<sup>12)</sup> reported the use of ventriculoscopia in a patient with a colloid cyst. In 1973, Fukushima et al.<sup>8)</sup> provided the first modern description of an endoscopic biopsy with the introduction of the ventriculo-fiberscope. The evolutions of endoscopic techniques and improvement in adequacy of diagnosis have allowed us to dramatically change the prognosis and therapeutic regimen in pineal region tumors. Recently, neuroendoscopy has become the preferred technique to achieve minimally invasive management of these lesions<sup>17)</sup>.

The usefulness of endoscopic tumor management is based

on the principle that the intraventricular cerebrospinal fluid (CSF) serves as an excellent natural medium for image and light transmission. Patients with hydrocephalus and appropriate intraventricular tumors thus serve as ideal candidates for endoscopic management. However, it is usually difficult to perform the neuroendoscopic procedure in the patients without hydrocephalus because of presumed difficulties with ventricular cannulation. However, recent development in neuroendoscopy coupled with frameless navigational system, ventricular dilatation is no longer an indispensable prerequisite. The purpose of this study was to investigate the value of navigation guided neuroendoscopic biopsy in patients with peri- or intraventricular tumors without hydrocephalus.

## MATERIALS AND METHODS

### Patient selection

From 2001 to 2008, 53 patients (mean age, 12.49 years) with tumors located in the peri- or intraventricular areas underwent neuroendoscopic biopsy, with or without simul-

• Received : March 24, 2010 • Revised : April 27, 2010

• Accepted : May 23, 2010

• Address for reprints : Hyung Jin Shin, M.D., Ph.D.

Department of Neurosurgery, Samsung Medical Center,  
Sungkyunkwan University School of Medicine, 50 Irwon-dong,  
Gangnam-gu, Seoul 135-710, Korea

Tel : +82-2-3410-3492, Fax : +82-2-3410-0048

E-mail : shinjh@skku.edu

taneous third ventriculostomy. From this patient population, 6 patients (11.1%) did not reveal symptoms of hydrocephalus or radiographic ventriculomegaly at presentation. These patients ranged in age from 8 to 47 years (mean, 19.7 yr). There were 5 males and one female. Patients underwent imaging for a variety of reasons, including a history of headache ( $n = 3$ ), visual symptoms ( $n = 1$ ), polydipsia and polyuria ( $n = 1$ ), and precocious puberty ( $n = 1$ ). The procedure was indicated for verification of the histological diagnosis of the neoplasm, which was planned to be treated by chemotherapy and/or radiotherapy as the first line treatment, or establishment of the pathological diagnosis for further choice of the most appropriate treatment strategy.

To ensure against any subjective bias or misinterpretation in defining hydrocephalus, the ventricular size was measured on preoperative magnetic resonance imaging (MRI) scans for all patients in the study group by an independent observer. A two-dimensional measurement, the frontal and occipital horn ratio (FOR) was used as an objective measure. This index is known to have a high interobserver reliability, to be unaffected by the patient's age, and to have a high correlation with volumetric measurements. A value of 0.37 (standard deviation, 0.026) was used as the normative mean.

The mean FOR of the 6 patients selected for analysis was  $0.278 \pm 0.026$  (standard deviation; range 0.252-0.304). Compared with the reported normative mean of  $0.37 \pm 0.026$  (standard deviation; range, 0.31-0.44; sample size, 44), the study group had a lower FOR ( $p < 0.0001$ , two-sample t-test). Further, no patient had an FOR value more than the normal value of 0.37. Thus, all the six patients met the inclusion criteria of this analysis.

### Surgical procedures

All procedures were performed with the patient under general anesthesia in a supine position<sup>6</sup>. The preferred entry site is made at the time of surgery with navigational guidance. The head should always be elevated above a horizontal plane in an effort to minimize CSF egress from the endoscope.

In all procedures, the navigational system guided the surgeons precisely to the target. Navigational tracking was helpful in entering small ventricles and in approaching the posterior third ventricle through narrow foramen of Monro. An anterior entry site with reference to the coronal suture was used for lesions situated in the posterior third ventricle or pineal region. With respect to laterality, most entries were placed on the nondominant side.

When navigation was used for trajectory planning, the sheath was registered using a frameless navigational system (BrainLAB, Feldkirchen, Germany). A 0-degree rigid lens endoscope (Karl Storz, Tuttlingen, Germany) was used for

all procedures. All biopsies were obtained with a rigid endoscope (outer diameter 2.9 mm) using a free-hand technique and a 1 mm micro forceps through a 5.6 mm working channel with a high resolution (HD) camera.

After the cannulation of the anterior horn of the right lateral ventricle, an intraventricular catheter was inserted. As soon as CSF return confirmed an intraventricular position, gradual insufflations of the ventricular system with lactated Ringer's solution were performed. After controlled insufflations, the access catheter was substituted with the endoscopic sheath.

During the procedure, we measured intraventricular pressure and obtained CSF for cytological and biochemical analysis, and connected an intraventricular catheter to a reservoir of Ringer's lactate solution for intraventricular inflation<sup>6</sup>. After identification of the tumor and visual inspection of its growth patterns, sampling of the tumor mass then was performed by selecting a relatively avascular portion of the tumor and careful coagulation of the surface of the neoplasm was performed, and the neoplasm was sampled with grasping forceps. Complete hemostasis was attained either by coagulation or continuous local irrigation over several minutes if bleeding was detected.

Preliminary histological diagnosis was established with frozen sections. Intraventricular inflation of the Ringer's lactate solution was continued up to the final stages of the procedure to prevent ventricular collapse or income of air. Then, endoscopic third ventriculostomy (ETV) was performed with coagulation, if needed<sup>6</sup>. The openings of the dura were covered by gel foam and soft tissues were sutured in layers. Externalized ventricular drains were monitored with pressure transduction and were discontinued when pressure recordings confirmed normalization.

### Post operative management

Immediate postoperative CT scans were obtained in all patients immediately after operation. Antibiotics were administered for postoperative 3-7 days.

### Statistical analysis

The Fisher's exact test was used to compare the success in achieving the surgical objective between patients without hydrocephalus and those with ventriculomegaly. The two sample t-test was used to compare the FOR between the two groups of patients.

### Illustrative cases

#### Case 1

This 19-year-old male patient had a 2-month history of

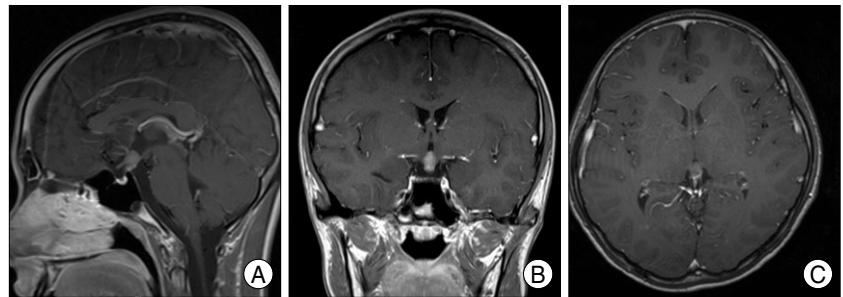
polyuria, polydipsia and 15 kg of weight loss for last 2 months. A contrast-enhanced MRI scan showed a heterogeneous mass situated in the suprasellar and pineal compartments without associated hydrocephalus (Fig. 1). His initial serum sodium level was 142 mmol/L. Endocrine evaluation revealed a serum prolactin level of 64.34 ng/mL, indicated panhypopituitarism and CSF cytology represented a few atypical cells. Serum and CSF biochemical assessment was notable for a CSF human chorionic gonadotropin level of 73.6 mIU/mL. It was the modest elevation in human chorionic gonadotropin (hCG), above reference range and highly suggestive of a germ cell tumor, thus could not be differentiated whether the tumor represented an hCG-secreting germinoma with syncytiotrophoblastic cells or a nongerminomatous germ cell tumor. Endoscopic tissue sampling was offered for definitive tumor classification. A right frontal endoscopic biopsy was performed using navigational guidance. Histological samples were interpreted as pure germinoma. The patient was treated for her primary germ cell tumor by subsequent chemotherapy and radiotherapy. He remains without evidence of disease recurrence 6 months after radiotherapy.

### Case 2

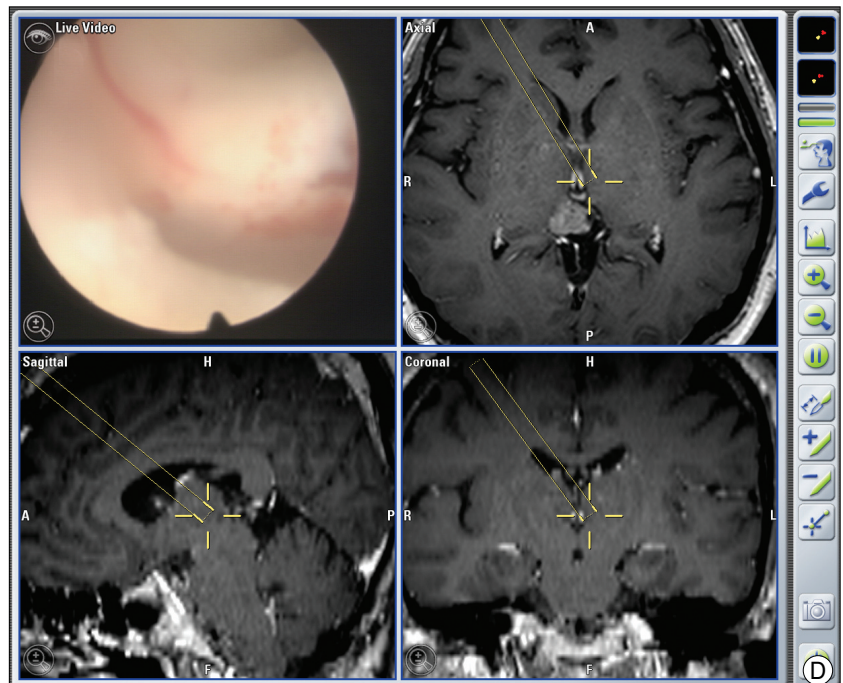
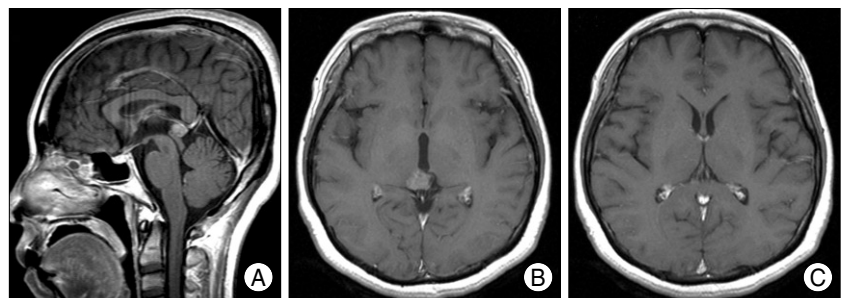
This 47-year-old female patient who presented with frequent headaches underwent an endoscopic tumor removal of pineal gland (Fig. 2). Serum and CSF biochemical evaluation for hCG and  $\alpha$ -fetoprotein were normal. A contrast-enhanced magnetic resonance image (MRI) scan showed a heterogeneous mass situated in the pineal gland without associated hydrocephalus. A right frontal endoscopic biopsy was conducted using navigational guidance to optimize a trajectory for cranial burr hole. The tumor biopsy was performed without difficulty. The histological sample was interpreted as a pineocytoma.

### RESULTS

Under the guidance of navigation, targeted lesions were successfully approached in all patients and the intended goal was accomplished. Navigational tracking was helpful



**Fig. 1.** MRI scans with contrast indicate the suprasellar mass in the (A) sagittal, (B) coronal, (C) and axial planes. A contrast-enhancing mass approximately 9 mm in maximal dimension is seen without any evidence of CSF obstruction or resultant ventriculomegaly.



**Fig. 2.** T1-weighted sagittal (A) and axial (B and C) magnetic resonance imaging (MRI) scans reveals a small, homogenous enhancing lesion in the pineal area. There is no evidence of ventricular dilation. Navigational images indicate preoperative planning for an endoscopic approach to the pineal gland tumor (D). The monitor of the navigation system was connected with coaxial cables to the neuroendoscope monitor.

**Table 1.** Clinical characteristics of 6 cases of peri- or intraventricular tumors without hydrocephalus treated by navigation guided endoscopic biopsy

No.	Age (yr) / Sex	Clinical manifestations	Tumor size (mm)	Endoscopic treatment	Tumor marker	CSF cytology	Histology treatment	Further	Outcome
1	M/25	Blurred vision	10.7	Biopsy	N	N	Germinoma	CTx, RTx	Cured at 16 month
2	M/10	Headache	13.8	Biopsy	N	N	DNT	Tumor removal	Cured at 7 month
3	M/9	Headache	11.6	Removal	N	N	PA	None	Consider CTx
4	M/19	Polydipsia	9.1	Biopsy	$\beta$ -hCG	P	Germinoma	CTx, RTx	Cured at 6 month
5	M/8	Precocious puberty	43.6	Biopsy	N	N	PA	CTx	Cured at 10 month
6	F/47	Headache	14.8	Biopsy	N	N	Pineocytoma	None	Follow up loss

DNT : dysembryoplastic neuroepithelial tumor, PA : pilomyxoid astrocytoma, CTx : chemotherapy, RTx : radiotherapy, N : negative, P : positive

in entering small ventricles and in approaching the third ventricle when the foramen Monro was narrow. The overall success rate for achieving the intended surgical goal of tumor resection or diagnostic sampling in the 53 patients was 91.8%. In the study group, the surgical objective was met in all 6 patients (100%). The characteristics of these patients are described in Table 1. Compared with the group of 47 patients who had hydrocephalus at presentation, there was no statistical difference in achieving the surgical objective whether tumor biopsy or resection was the intent.

The histopathologic diagnosis was established in all of 6 patients : 2 germinomas, 2 astrocytomas, 1 dysembryoplastic neuroepithelial tumor and 1 pineocytoma. The tumor biopsy sites were pineal gland (n = 2), suprasellar area (n = 2), subcallosal area (n = 1) and thalamus (n = 1). There were no operative complications related to the endoscopic procedure.

**Patient outcome**

There were no recognized neurological complications related to the surgical procedure such as seizures, infections, or deaths. All drains were removed on postoperative Day 1 because normal intracranial pressures were observed in all cases. All wounds healed without evidence of CSF leaks. No patient exhibited signs of raised intracranial pressure or postoperative evidence of ventriculomegaly. Thus, no patient required subsequent treatment for symptomatic hydrocephalus. Notably, there was no symptomatic bleeding or visible hemorrhage on postoperative CT scan.

**DISCUSSION**

The usefulness of endoscopic neurosurgery for the management of intraventricular brain tumors is well established. Total extirpation of colloid cysts<sup>1,3,4,13-15</sup>, cystic decompression of craniopharyngiomas<sup>2</sup>, sampling of intraventricular brain tumors<sup>5,7,9,11,16-19,22</sup>, and removal of solid tumors<sup>9,11,16</sup> have been reported with increasing frequency since the advent of recent technological advances in endoscopic equipment. The usefulness of endoscopic tumor management is based on the principle that the intraventricular CSF serves

as an excellent natural medium for image and light transmission. Patients with hydrocephalus and appropriate intraventricular tumors thus serve as ideal candidates for endoscopic management.

However, endoscopic surgery for patients without hydrocephalus usually is avoided because of the purported difficulty with ventricular cannulation and intraventricular navigation. Logically, it is expected that in the absence of hydrocephalus, the success rate of endoscopic ventricular access would be reduced. In addition, the morbidity of such procedures also may be influenced by the degree of ventriculomegaly. Grunert et al.<sup>11</sup> reported their experiences of endoscopic surgery for third ventricular lesions in 1997. However, they included the cases with hydrocephalus and aqueduct obstruction<sup>11</sup>. This bias in patient selection is understandable because of the expectation that ventricular cannulation and intraventricular navigation may be difficult in normal-sized ventricles.

The specific topic of endoscopy in patients with normal-sized ventricles was the primary focus of an earlier publication by Yamamoto et al.<sup>23</sup> In those small series of three patients successful ventriculocopy for other intraventricular lesions was performed even though none had a brain tumor. Recently, a series of neuroendoscopic biopsies of intraventricular tumors in patients without hydrocephalus was reported by Souweidane.<sup>21</sup> They reported the experience with 15 patients without hydrocephalus who underwent endoscopic management for their intraventricular brain tumor. These results are compared with those with hydrocephalic patients. However, the 15 patients were relatively good candidates for endoscopic surgery in that the lesions were located in the lateral ventricle or anterior third ventricle, even if the ventricle sizes were not increased. They suggested that the surgical risk would increase if the lesions were located in the posterior third ventricle or pineal region because it is difficult to cannulate a normal-sized third ventricle and manipulate the device at the proximity of the choroid plexus, the internal cerebral veins, and the hypothalami.

In contrast to previous reports, we included all patients without hydrocephalus with lesions located in the posterior

third ventricle or pineal region as well as the lateral ventricular anterior third ventricle. Fortunately, the success rate of endoscopic biopsy was similar between the two groups of patients without hydrocephalus and with hydrocephalus.

In our series, five of these patients underwent diagnostic and one patient underwent tumor removal. The procedures were successfully finished in all patients without meaningful morbidity. Remarkably, no patient required treatment for symptomatic hydrocephalus after the procedure. Therefore, our strategy in patients without hydrocephalus is considered acceptable.

This study was not performed to define a superior technology than others, but to suggest the possible application of endoscopy in small ventricles only if careful approach using guidance of navigational system would be applied. A couple of experienced groups for endoscopic surgery subsequently suggested the advantages of navigational guidance for endoscopic cannulation into the ventricle in patients without hydrocephalus<sup>4,10,20</sup>.

Even though the conventional stereotactic needle biopsy is a valid alternative for tumor sampling in these situation, the endoscopic technique does offer several potential advantages, including ventriculoscopic inspection for any metastatic potential, CSF sampling for staging, direct visualization allowing avoidance of choroid plexus or vascular tributaries, and the ability to perform simultaneous procedures if indicated (endoscopic third ventriculostomy, septostomy, or tumor cyst decompression).

Thus, if indications for intraventricular tumor biopsy or resection are present, the absence of hydrocephalus does not seem to contraindicate an endoscopic approach.

## CONCLUSION

The combination of neuroendoscopy and navigation would improve the accuracy of the endoscopic approach and minimize the risk of brain injury as well.

In this study, we suggest the endoscopic approach to perior intraventricular tumors accompanied by navigational system in patients without hydrocephalus is helpful in achieving the proper surgical goal without additional complication risks.

## References

1. Abdou MS, Cohen AR : Endoscopic treatment of colloid cysts of the third ventricle. Technical note and review of the literature. *J Neurosurg* 89 : 1062-1068, 1998
2. Abdullah J, Caemaert J : Endoscopic management of craniopharyngiomas : a review of 3 cases. *Minim Invasive Neurosurg* 38 : 79-84, 1995
3. Cohen AR : Endoscopic ventricular surgery. *Pediatr Neurosurg* 19 : 127-134, 1993
4. Decq P, Le Guerinel C, Brugières P, Djindjian M, Silva D, Kéravel Y, et al. : Endoscopic management of colloid cysts. *Neurosurgery* 42 : 1288-1294; discussion 1294-1296, 1998
5. Ferrer E, Santamarta D, Garcia-Fructuoso G, Caral L, Rumiá J : Neuroendoscopic management of pineal region tumours. *Acta Neurochir (Wien)* 139 : 12-20; discussion 20-21, 1997
6. Fiorindi A, Longatti P : A restricted neuroendoscopic approach for pathological diagnosis of intraventricular and paraventricular tumours. *Acta Neurochir (Wien)* 150 : 1235-1239, 2008
7. Fukushima T : Endoscopic biopsy of intraventricular tumors with the use of a ventriculofiberscope. *Neurosurgery* 2 : 110-113, 1978
8. Fukushima T, Ishijima B, Hirakawa K, Nakamura N, Sano K : Ventriculofiberscope : a new technique for endoscopic diagnosis and operation. Technical note. *J Neurosurg* 38 : 251-256, 1973
9. Gaab MR, Schroeder HW : Neuroendoscopic approach to intraventricular lesions. *J Neurosurg* 88 : 496-505, 1998
10. Gaab MR, Schroeder HW : Neuroendoscopic approach to intraventricular lesions. *Neurosurg Focus* 6 : e5, 1999
11. Grunert P, Hopf N, Perneczky A : Frame-based and frameless endoscopic procedures in the third ventricle. *Stereotact Funct Neurosurg* 68 : 80-89, 1997
12. Guiot J, Rougerie J, Fourestier M, Fournier A, Comoy C, Vulmiere J, et al. : [Intracranial endoscopic explorations.] *Presse Med* 71 : 1225-1228, 1963
13. Hellwig D, Bauer BL, Schulte M, Gatscher S, Riegel T, Bertalanffy H : Neuroendoscopic treatment for colloid cysts of the third ventricle : the experience of a decade. *Neurosurgery* 52 : 525-533; discussion 532-533, 2003
14. King WA, Ullman JS, Frazee JG, Post KD, Bergsneider M : Endoscopic resection of colloid cysts : surgical considerations using the rigid endoscope. *Neurosurgery* 44 : 1103-1109; discussion 1109-1111, 1999
15. Kondziolka D, Lunsford LD : Stereotactic techniques for colloid cysts : roles of aspiration, endoscopy, and microsurgery. *Acta Neurochir Suppl* 61 : 76-78, 1994
16. Macarthur DC, Buxton N, Punt J, Vloeberghs M, Robertson IJ : The role of neuroendoscopy in the management of brain tumours. *Br J Neurosurg* 16 : 465-470, 2002
17. Oi S, Shibata M, Tominaga J, Honda Y, Shinoda M, Takei F, et al. : Efficacy of neuroendoscopic procedures in minimally invasive preferential management of pineal region tumors : a prospective study. *J Neurosurg* 93 : 245-253, 2000
18. Oka K, Yamamoto M, Nagasaka S, Tomonaga M : Endoneurosurgical treatment for hydrocephalus caused by intraventricular tumors. *Childs Nerv Syst* 10 : 162-166, 1994
19. Pople IK, Athanasiou TC, Sandeman DR, Coakham HB : The role of endoscopic biopsy and third ventriculostomy in the management of pineal region tumours. *Br J Neurosurg* 15 : 305-311, 2001
20. Schroeder HW, Wagner W, Tschiltshcke W, Gaab MR : Frameless neuronavigation in intracranial endoscopic neurosurgery. *J Neurosurg* 94 : 72-79, 2001
21. Souweidane MM : Endoscopic surgery for intraventricular brain tumors in patients without hydrocephalus. *Neurosurgery* 57 : 312-318; discussion 312-318, 2005
22. Souweidane MM, Sandberg DI, Bilsky MH, Gutin PH : Endoscopic biopsy for tumors of the third ventricle. *Pediatr Neurosurg* 33 : 132-137, 2000
23. Yamamoto M, Oka K, Takasugi S, Hachisuka S, Miyake E, Tomonaga M : Flexible neuroendoscopy for percutaneous treatment of intraventricular lesions in the absence of hydrocephalus. *Minim Invasive Neurosurg* 40 : 139-143, 1997