

## Clinical Article

# Interspinous Implant with Unilateral Laminotomy for Bilateral Decompression of Degenerative Lumbar Spinal Stenosis in Elderly Patients

Sung-Joo Ryu, M.D., In-Soo Kim, M.D., Ph.D.

Department of Neurosurgery, Dongsan Medical Center, Keimyung University School of Medicine, Daegu, Korea

**Objective :** This study assessed the safety and efficacy of one level unilateral laminotomy bilateral decompression (ULBD) with the placement of a device for intervertebral assisted motion (DIAM) compared with one level ULBD only in elderly patients with degenerative lumbar spinal stenosis (DLSS).

**Methods :** A non randomized prospective analysis was performed on 16 patients who underwent one level ULBD with DIAM (Group A) and 20 patients with one level ULBD only (Group B) between February 2007 and March 2008. Radiographic imaging, visual analog scale (VAS) and MacNab outcome scale were obtained before and after surgery at a mean interval of 21 months (range 17-27 months).

**Results :** The disc height, interpedicular distance, slip distance and segmental lordotic angle were similar between two groups. In the group A, there was no significant difference between the pre- and post-operative imaging in terms of the sagittal balance and disc height. Both groups showed significant improvement in the clinical outcomes. In addition, there was significantly less low-back pain in the group A than in the group B at the last follow up, while the clinical improvement of the leg pain and MacNab outcome scale showed no significant difference in the two groups. There were no major complications or DIAM associated complications.

**Conclusion :** ULBD with DIAM is a safe and efficacious treatment for selective elderly patients with DLSS, particularly for relieving low back pain comparing to ULBD. ULBD with DIAM did not alter the disc height or sagittal alignment at the mean 21 months follow-up interval.

**KEY WORDS :** Spinal stenosis · Intervertebral assisted motion · Laminotomy · Low-back pain.

## INTRODUCTION

The symptoms of degenerative lumbar spinal stenosis (DLSS) in the elderly typically result from a complex degenerative process of ligamentum flavum hypertrophy, intervertebral disc bulging or herniation, and facet thickening with arthropathy<sup>15,27</sup>. The symptoms can be treated conservatively using pain-relieving medication, physical therapy, or with spinal anesthetic block therapy. However, surgery should be considered if the pain persists<sup>6</sup>. Elderly patients tend to avoid surgery because of their increased age and comorbidity. The increasing elderly population and average

life span has led to an increase in the incidence of degenerative lumbar spinal stenosis and number of the elderly patients requiring surgical treatment<sup>10</sup>. Traditional decompression surgery frequently requires spinal fixation and fusion procedures. Therefore, these procedures are controversial in elderly patients<sup>8,9,13</sup>. With the aim of less invasiveness and better preservation of spinal stability, the technique of unilateral laminotomy for bilateral decompression (ULBD) and a device for intervertebral assisted motion (DIAM) were developed. This study compared the efficacy and safety of the ULBD with DIAM placement with those of ULBD only in the elderly patients.

## MATERIALS AND METHODS

We designed a non randomized prospective analysis aimed to assess the safety and efficacy of ULBD with DIAM placement as compared with the ULBD only in the elderly

• Received : February 24, 2010 • Revised : March 16, 2010

• Accepted : May 17, 2010

• Address for reprints : In-Soo Kim, M.D., Ph.D.

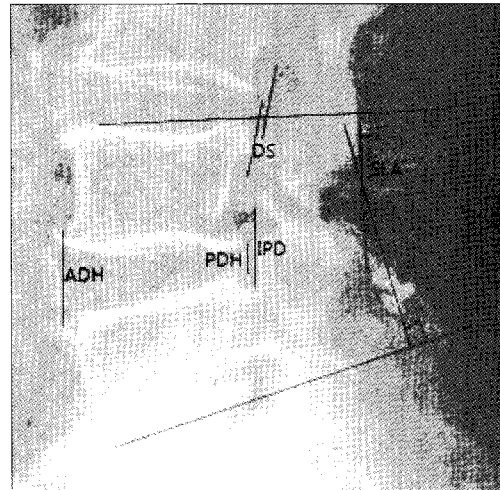
Department of Neurosurgery, Dongsan Medical Center, 194 Dongsan-dong, Jung-gu, Daegu 700-712, Korea

Tel : +82-53-250-7730, Fax : +82-53-250-7820

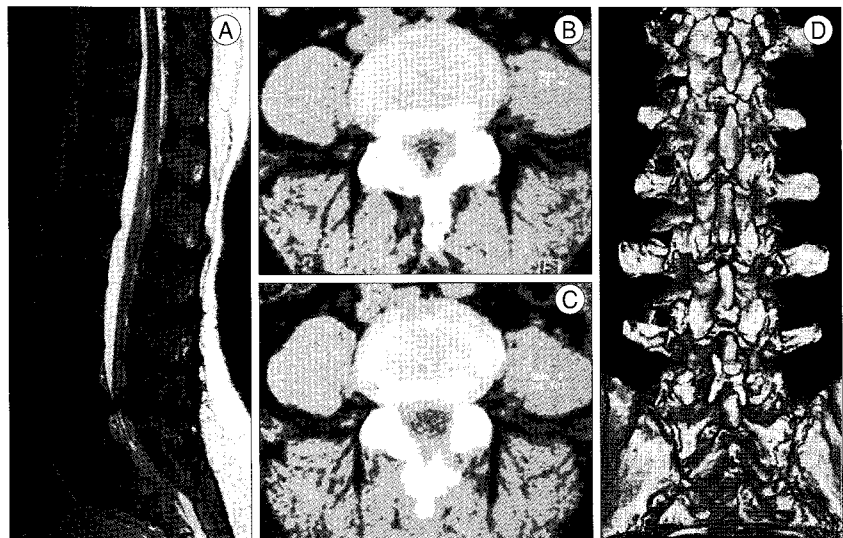
E-mail : neurokim@dsmc.or.kr

patients with DLSS. However, the data was collected retrospectively. Between February 2007 and March 2008, 36 patients with DLSS were enrolled in this study. Sixteen patients were treated with one level ULBD with DIAM (Group A) and 20 patients were treated with one level ULBD only (Group B). The following inclusion criteria were used : 1) the failure of conservative treatment for a minimum of 3 months; 2) the ages older than 65 years; and 3) the degenerative stenosis involving the central canal and/or foraminal recess at computed tomography (CT) and magnetic resonance imaging (MRI). The exclusion criteria were 1) the presence of isthmic spondylolisthesis, 2) the osteoporosis and degenerative scoliosis, and 3) the spinal instability at preoperative lateral flexion-extension radiography of the lumbar spine. The clinical outcomes were analyzed using the pre- and post-operative Visual Analog Scale (VAS) and the MacNab outcome scale. The patients' outcomes were assessed to be excellent, good, fair, or poor using the MacNab outcome scale. All patients underwent a pre- and post-operative radiographic assessment including upright lateral and flexion-extension lateral radiographs, CT and MRI of the lumbar spine. We compared the anterior and posterior disc height, distance of slip, segmental lordotic angle and interpedicular distance on pre- and post-operative radiographic images. The anterior disc heights were measured from the distance between the anterosuperior and anteroinferior corners of the vertebral bodies. The posterior disc heights were measured from the distance between the posterosuperior and posteroinferior corners of the vertebral bodies. The distance of slip was measured from each posterosuperior and posteroinferior corner of the vertebral bodies at the level of operation. The segmental lordotic angle was measured using the Cobb's angle at the level of the operation. The interpedicular distance was measured from the distance between the inferior border of the pedicle of the superior spinal level and the superior border of the pedicle of the inferior spinal level at the pedicle-laminar junction at the level of the operation (Fig. 1). The microsurgical procedure of ULBD is described in detail elsewhere<sup>5)</sup>. Surgery was performed in a standardized manner with a minimally invasive approach via a unilateral laminotomy with partial resection of the inferior aspect of the

cranial hemilamina and, usually to a minimal degree, from the superior aspect of the caudal hemilamina. After ipsilateral decompression, the base of the spinous process was undercut with aid of medial angulation of the operative microscope, the contralateral hemilamina together with the hypertrophied medial facet were partially removed after bilateral flavectomy, and the lateral recess and neural foramina were decompressed contralaterally. And, in the DIAM implant procedure, the supraspinous and interspinous ligaments were preserved during the decompression. A



**Fig. 1.** Lateral standing radiograph obtained after unilateral laminotomy bilateral decompression with device for intervertebral assisted motion at L4/5. ADH : anterior disc height, DS : distance of slip, IPD : interpedicular distance, PDH : posterior disc height, SLA : segmental lordotic angle.



**Fig. 2.** Illustrative case of a 67-year-old woman who presented with history of low-back pain, neurogenic intermittent claudication and right-sided L5 radicular symptoms. A : Preoperative sagittal T2 MRI confirms the severe stenosis at L4-L5. B : preoperative CT axial image reveals severe narrowing of the canal at L4-L5 with marked facet overgrowth and hypertrophy of the ligamentum flavum. C : CT axial image demonstrates the extent of decompression after ULBD with DIAM. D : Three-dimensional CT image shows implanted DIAM between L4-5 spinous processes. CT : computed tomography, DIAM : device for intervertebral assisted motion, MRI : magnetic resonance image, ULBD : unilateral laminotomy bilateral decompression.

space was then created between the inferior border of upper spinous processes and superior border of lower spinous processes with curet and a Kerrison punch. The distractor was then placed between the inferior border of upper lamina and superior border of lower lamina. The proper sized DIAM™ device was then folded and deposited. The area was then irrigated and closed in the standard fashion. Fig. 2 demonstrates a ULBD with DIAM placement for DLSS. Statistical significance was determined by a two sample and paired t-test using SPSS version 15.0. A *p* value < 0.05 was considered significant.

**RESULTS**

We carried out a prospective study comparing two consecutive groups, who underwent surgery for DLSS. All 36 patients were divided in 2 groups (A and B) according to the surgical type they received. Group A included 16 patients consisting of 11 males and 5 females. Among twenty patients of Group B, there were 12 males and 8 females. The mean age of the patients in Group A and B was 69.38 ± 4.57 and 72.31 ± 5.02, respectively. The mean follow-up duration in Group A and B was 21.43 ± 4.51 and 22.75 ±

5.21 months, respectively. All patients had symptoms of neurogenic claudication. In Group A, 15 patients (93.7%) had symptoms of low-back pain and radiculopathy. In Group B, 18 patients (90%) had symptoms of low-back pain and 17 patients (85%) showed radiculopathy. In both groups, L4-5 was the most common spine level operated on (Table 1).

**Clinical outcomes based on the VAS and MacNab scores in Groups A and B**

Evaluation of leg and low-back pain, using VAS scores were performed pre- and post-operatively. Both groups demonstrated significant improvement in leg and low-back pain between the pre- and post-operative VAS scores. However, there was no significant difference in the VAS score for leg pain between the groups. On the other hand, the low-back pain VAS scores of Group A (2.13 ± 1.35) were significantly lower than those for Group B (3.23 ± 1.27) at the last follow-up (*p* < 0.05) (Fig. 3). The MacNab outcome scales in Groups A and B were used to assess the patients at 1 month, 3 months and 6 months and at the last follow-up visit. Both groups demonstrated significant improvements but there was no significant difference between the two groups (Fig. 4).

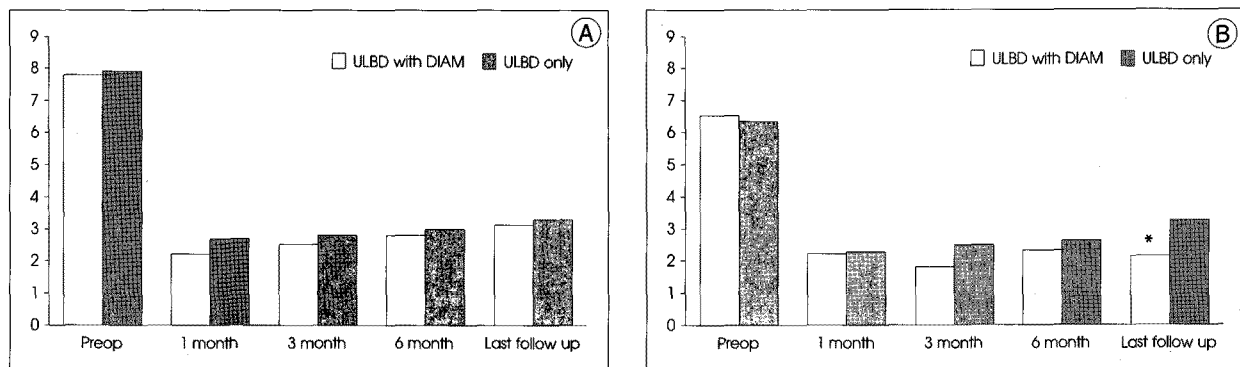
**Table 1.** Demographics of the patients

	ULBD with DIAM group	ULBD only group
No. of cases (No. of operation level)	16 patients (16 level)	20 patients (20 level)
Age	69.38 ± 4.57	72.31 ± 5.02
Sex (male : female)	11:5	12:8
BMD	-0.34 ± 0.61	-0.69 ± 0.84
Level of operation, no (%)	L3/4, 02 (12.5%) L4/5, 14 (87.5%)	L3/4, 02 (10.0%) L4/5, 18 (90.0%)
Chief Symptom, no (%)		
NIC	16 (100.%)	20 (100.%)
LBP	15 (93.7%)	18 (90%)
Radiculopathy	15 (93.7%)	17 (85%)
Follow up duration(month)	21.43 ± 4.51	22.75 ± 5.21

BMD : bone mineral density DIAM : device for intervertebral assisted motion, LBP : low-back pain, NIC : neurogenic intermittent claudication, ULBD : unilateral laminotomy bilateral decompression

**Radiologic outcomes**

There were no significant difference in the mean anterior disc height pre- and post-operatively between the two groups and follow-up interval (Fig. 5). The mean posterior disc height pre-operatively and at the last follow-up was similar in the two groups. However, the posterior disc height of Group A was significantly higher than that of Group B at the postoperative 1 day follow-up. In Group A, the posterior



**Fig. 3.** Results of pre- and post-operative visual analog scale (VAS) score. A : VAS score of Leg pain, B : VAS score of low-back pain. \*significance between ULBD only group and ULBD with DIAM group (*p* < 0.05).

disc height at the postoperative 1 day and 1 month follow-up showed a significant increase from  $7.20 \pm 1.78$  to  $9.02 \pm 1.64$  and  $7.99 \pm 1.71$ , respectively (Fig. 6). The mean interpedicular distance was similar in the two groups and between the follow-up intervals of each group (Fig. 7). Preoperatively, the mean segmental lordotic angle in Group A was  $15.29 \pm 2.84^\circ$ . It decreased to  $15.00 \pm 3.17^\circ$  at the last follow-up. The mean segmental lordotic angle in Group B was  $15.11 \pm 3.11$  preoperatively, and  $16.85 \pm 3.27$  at the last follow-up. However, there were no significant different pre- and post-operatively between the two groups and between the follow-up intervals of each group

(Fig. 8). In Group A, the mean distance of slip decreased from  $1.32 \pm 0.36$  to  $1.23 \pm 0.71$ , whereas in Group B, the mean distance of slip showed almost no change from  $1.21 \pm 0.48$  to  $1.24 \pm 0.63$ . There were no significant differences pre- and post-operatively between the two groups and between the follow-up intervals of each group (Fig. 9). There was no significant difference in the anterior and posterior disc height, interpedicular distance, segmental lordotic angle, the distance of slip pre-and postoperatively between the two groups (Table 2).

There were no perioperative major complications, such as infection or nerve damage. A dural tear was encountered in 1 case. There were no DIAM associated complications, such as displacement of DIAM, spinous process fracture and osteolysis of the spinous process.

**DISCUSSION**

The management of DLSS in elderly patients is still controversial. It is generally accepted that surgery is indicated if well-conducted conservative treatment fails. And, there are several reports in which surgical treatments showed better results compared to conservative treatments in elderly patients<sup>5,17,24</sup>. Open decompression is the most

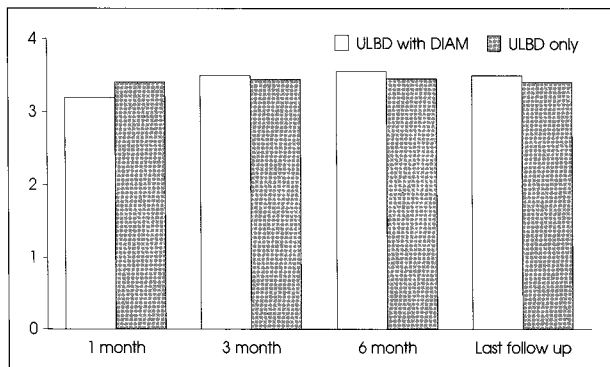


Fig. 4. Results of postoperative MacNab outcome scale.

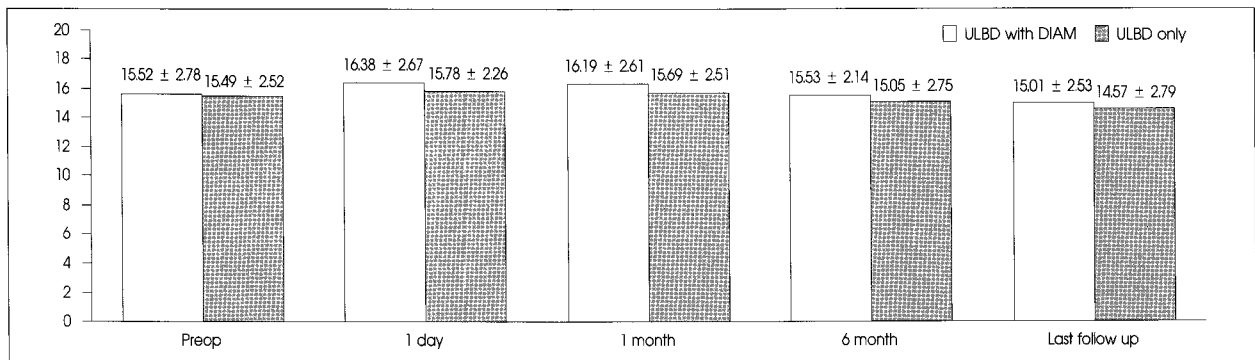


Fig. 5. Changes of anterior disc height (mm) pre- and post-operatively to the latest evaluation.

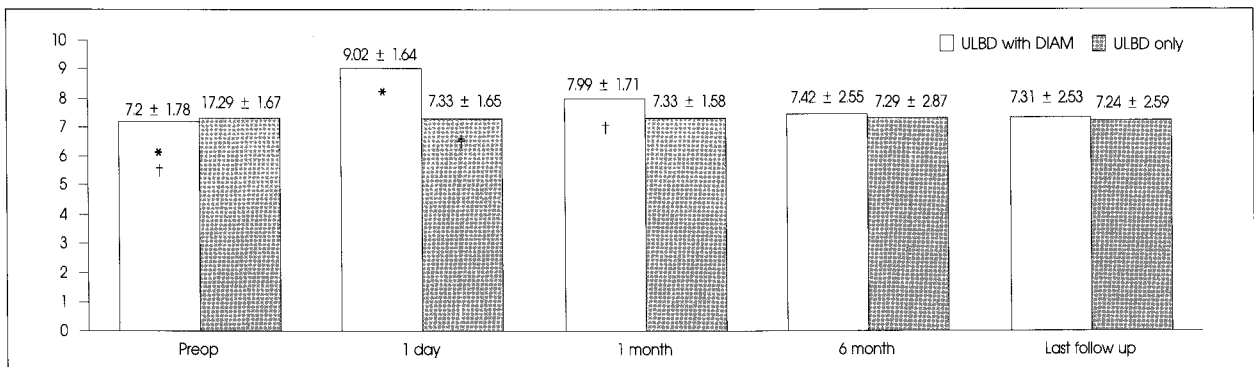


Fig. 6. Changes of posterior disc height (mm) pre- and post-operatively to the latest evaluation. \*significant increase at postoperative 1 day compared with preoperatively in unilateral laminotomy bilateral decompression (ULBD) with device for intervertebral assisted motion (DIAM) group ( $p < 0.05$ ), † significant increase at postoperative 1 day compared with preoperatively in ULBD only group ( $p < 0.05$ ), ‡ significant difference between ULBD with DIAM group and ULBD only group at postoperative 1 day ( $p < 0.05$ ).

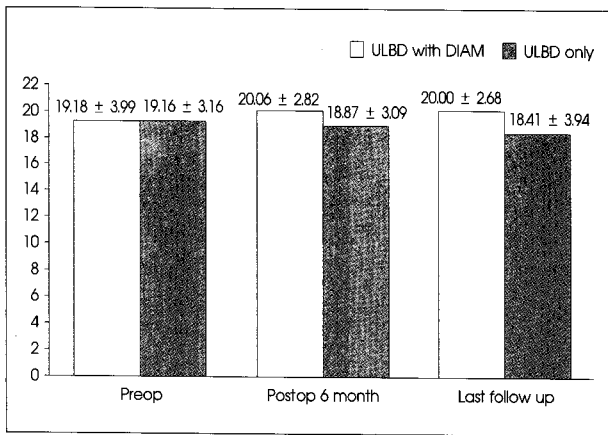


Fig. 7. Changes of interpedicular distance (mm) pre- and postoperatively to the latest evaluation.

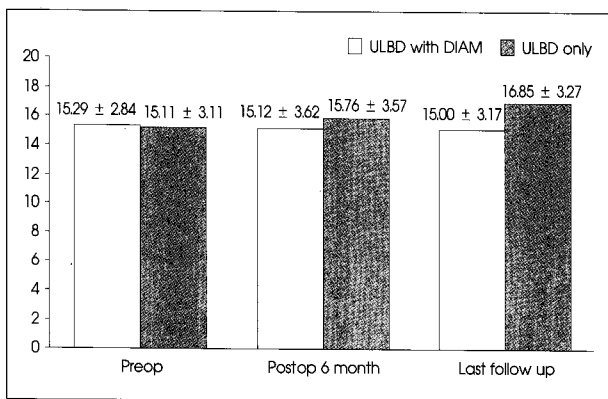


Fig. 8. Changes of segmental lordotic angle pre- and postoperatively to the latest evaluation.

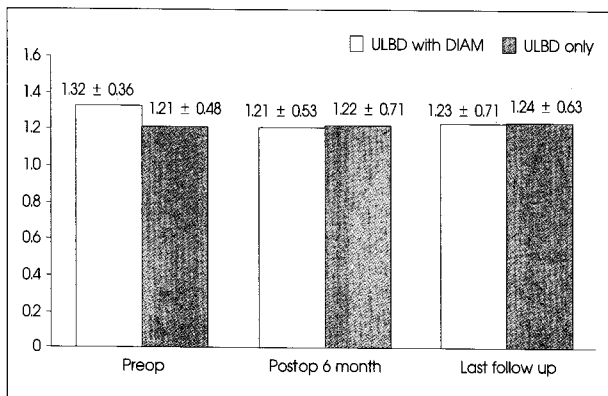


Fig. 9. Changes of distance of slip (mm) pre- and postoperatively to the latest evaluation.

common spinal operation for patients over 65 years of age with DLSS. However, for many patients, spinal stenosis is a progressive disease and may require repeated surgery for further decompression<sup>11,12,24</sup>. In addition, surgical decompression of spinal stenosis can cause or exacerbate the spinal instability, necessitating another operation for fusion<sup>9</sup>. Therefore, surgical fusion with instrumentation is needed to reduce the postoperative instability, to complete decom-

pression, to prevent a recurrence of the stenosis and to decrease the reoperation rate<sup>2,4,26</sup>. However, it has high perioperative mortality and complications, and a prolonged postoperative recuperation time in elderly patients and has adjacent segmental degeneration due to a loss of motion<sup>14</sup>. The more recently applied interspinous spacers are an alternative under discussion. An elastic device (device for intervertebral assisted motion or DIAM; Medtronic Sofamor Danek) was created<sup>11,19,23</sup>. The properties and promises the DIAM offers in theory are as follows: the device might achieve local kyphosis, alter the sagittal balance, provide segmental stability, alter the posterior neural foraminal height, and provide pain relief, particularly in patients suffering from low-back pain due to facet overloading or segmental instability or hyperlordosis<sup>1,18,19,21,23</sup>.

This study examined the clinical and radiologic outcomes. Clinically, the low-back pain VAS score of Group A at the last follow-up was significantly lower than that of Group B. The cause of this may be the stabilization of the painful segment as follows. 1) Restoring the posterior tension band by retightening the posterior elements in the vertebral body and not touching the supraspinous ligament reduce the posterior enfolding effect of the ligament flavum, and reload the disc in a more physiological pattern during motion. 2) Unloading the facet joint decreases the level of facetogenic pain and allows the repair and restorative mechanisms of the body to reduce the degree of inflammation<sup>7,16,19-22,25</sup>. Radiologically, DIAM would increase the posterior disc height, prevent or reduce the degree of spondylolisthesis, and correct the lordosis with kyphosis. In this study, there were no statistical differences in the anterior and posterior disc height, interpedicular distance, segmental lordotic angle, distance of slip at pre- and post-operative between the two groups at the last follow-up. However, the posterior disc height of Group A at the postoperative 1 day follow-up was significantly higher than that of Group B. In group A, the posterior disc height at the postoperative 1 day and 1 month follow-up increased significantly compared with the preoperative posterior disc height. There were no significant differences between the two groups at the last follow-up, and the changes were not sufficient to achieve local kyphosis, and alter the sagittal balance.

The safety of a DIAM implant was examined by Kim et al.<sup>13</sup> who reported no rejection or DIAM related complications<sup>3</sup>. Similarly, this study showed no infection or DIAM associated complications. These findings agree with those of previous studies on the safety of DIAM implant at a mean of 21 months. Kim et al.<sup>13</sup> reported 2 intra-operative spinous process fractures after DIAM implant placement. However, no spinous process fracture was noted in the pre-

**Table 2.** Comparison radiographic changes of ULBD with DIAM group compared with ULBD group

Difference*	ULBD with DIAM group	ULBD only group	p value
Anterior disc height	0.81 ± 0.97	1.12 ± 0.67	0.38
Posterior disc height	-0.11 ± 0.20	0.05 ± 0.64	0.42
Interpedicular distance	-0.84 ± 1.59	0.28 ± 2.47	0.11
Slip distance	0.21 ± 0.63	0.33 ± 0.52	0.58
Segmental angle	0.28 ± 0.44	0.67 ± 0.95	0.10

\*Difference : preoperative value - postoperative value. DIAM : device for intervertebral assisted motion, ULBD : unilateral laminotomy bilateral decompression

sent study. To reduce the chance of spinous process fractures, patients whose preoperative bone mineral density (BMD) was below -1.0 were excluded. Oversizing of the interspinous process was avoided using an 8 mm DIAM™ device and more flexion was performed for distraction of the spinous process during the insertion of the DIAM in the intraoperative field. We thought that the risk of postoperative spinous process fractures was low because the contact surface of the DIAM was not only the spinous process but also the upper portion of lamina.

This study had some inherent limitations because of the small number of cases and insufficient follow-up period. A larger number of cases and a longer follow-up period will be needed to confirm these findings and validate the new method (ULBD with DIAM).

## CONCLUSION

ULBD with DIAM did not alter the disc height or sagittal alignment at the mean 21 months follow-up interval. No adverse local or systematic reactions to the DIAM were encountered. Both ULBD with DIAM and ULBD only were effective for pain relief and improving the MacNab outcome scale in the elderly with DLSS. In addition, ULBD with DIAM is proven to be a safe and efficacious treatment for selective elderly patients with DLSS, particularly for relieving low-back pain comparing to the ULBD only.

## References

- Bono CM, Vaccaro AR : Interspinous process devices in the lumbar spine. *J Spinal Disord Tech* 20 : 255-261, 2007
- Carreon LY, Glassman SD, Howard J : Fusion and nonsurgical treatment for symptomatic lumbar degenerative disease : a systematic review of Oswestry Disability Index and MOS Short Form-36 outcomes. *Spine J* 8 : 747-755, 2008
- Caserta S, La Maida GA, Misaggi B, Peroni D, Pietrabisia R, Raimondi MT, et al. : Elastic stabilization alone or combined with rigid fusion in spinal surgery : a biomechanical study and clinical experience based on 82 cases. *Eur Spine J* 11 : S192-S197, 2002
- Christie SD, Song JK, Fessler RG : Dynamic interspinous process technology. *Spine (Phila Pa 1976)* 30 : S73-S78, 2005
- Costa F, Sassi M, Cardia A, Ortolina A, De Santis A, Luccarell G, et al. : Degenerative lumbar spinal stenosis : analysis of results in a series of 374 patients treated with unilateral laminotomy for bilateral microdecompression. *J Neurosurg Spine* 7 : 579-586, 2007
- Gunzburg R, Szpalski M : The conservative surgical treatment of lumbar spinal stenosis in the elderly. *Eur Spine J* 12 : S176-S180, 2003
- Gunzburg R, Szpalski M, Callary SA, Colloca CJ, Kosmopoulos V, Harrison D, et al. : Effect of a novel interspinous implant on lumbar spinal range of motion. *Eur Spine J* 18 : 696-703, 2009
- Hopp E, Tsou PM : Postdecompression lumbar instability. *Clin Orthop Relat Res* 227 : 143-151, 1988
- Johnsson KE, Willner S, Johnsson K : Postoperative instability after decompression for lumbar spinal stenosis. *Spine (Phila Pa 1976)* 11 : 107-110, 1986
- Kalbarczyk A, Lukes A, Seiler RW : Surgical treatment of lumbar spinal stenosis in the elderly. *Acta Neurochir (Wien)* 140 : 637-641, 1998
- Katz JN, Lipson SJ, Chang LC, Levine SA, Fossel AH, Liang MH : Seven- to 10-year outcome of decompressive surgery for degenerative lumbar spinal stenosis. *Spine (Phila Pa 1976)* 21 : 92-98, 1996
- Katz JN, Lipson SJ, Larson MG, McInnes JM, Fossel AH, Liang MH : The outcome of decompressive laminectomy for degenerative lumbar stenosis. *J Bone Joint Surg Am* 73 : 809-816, 1991
- Kim KA, McDonald M, Pik JH, Khoeir P, Wang MY : Dynamic intraspinal spacer technology for posterior stabilization : case-control study on the safety, sagittal angulation, and pain outcome at 1-year follow-up evaluation. *Neurosurgical Focus* 22 : E7, 2007
- Korovessis P, Repantis T, Zacharatos S, Zafiroopoulos A : Does Wallis implant reduce adjacent segment degeneration above lumbosacral instrumented fusion? *Eur Spine J* 18 : 830-840, 2009
- Kosaka H, Sairyo K, Biyani A, Leaman D, Yeasting R, Higashino K, et al. : Pathomechanism of loss of elasticity and hypertrophy of lumbar ligamentum flavum in elderly patients with lumbar spinal canal stenosis. *Spine (Phila Pa 1976)* 32 : 2805-2811, 2007
- Lindsey DP, Swanson KE, Fuchs P, Hsu KY, Zucherman JF, Yerby SA : The effects of an interspinous implant on the kinematics of the instrumented and adjacent levels in the lumbar spine. *Spine (Phila Pa 1976)* 28 : 2192-2197, 2003
- Malmivaara A, Slätis P, Heliövaara M, Sainio P, Kinnunen H, Kankare J, et al. : Surgical or nonoperative treatment for lumbar spinal stenosis? A randomized controlled trial. *Spine (Phila Pa 1976)* 32 : 1-8, 2007
- Mariottini A, Pieri S, Giachi S, Carangelo B, Zalaffi A, Muzii FV, et al. : Preliminary results of a soft novel lumbar intervertebral prosthesis (DIAM) in the degenerative spinal pathology. *Acta Neurochir Suppl* 92 : 129-131, 2005
- Minns RJ, Walsh WK : Preliminary design and experimental studies of a novel soft implant for correcting sagittal plane instability in the lumbar spine. *Spine (Phila Pa 1976)* 22 : 1819-1825; discussion 1826-1827, 1997
- Palmer S, Mahar A, Oka R : Biomechanical and radiographic analysis of a novel, minimally invasive, extension-limiting device for the lumbar spine. *Neurosurg Focus* 22 : E4, 2007
- Sobottke R, Schlüter-Brust K, Kaulhausen T, Röllinghoff M, Joswig B, Stützer H, et al. : Interspinous implants (X Stop, Wallis, Diam) for the treatment of LSS : is there a correlation between radiological parameters and clinical outcome? *Eur Spine J* 18 : 1494-1503, 2009
- Swanson KE, Lindsey DP, Hsu KY, Zucherman JF, Yerby SA : The effects of an interspinous implant on intervertebral disc pressures. *Spine (Phila Pa 1976)* 28 : 26-32, 2003
- Taylor J, Pupin P, Delajoux S, Palmer S : Device for intervertebral assisted motion : technique and initial results. *Neurosurg Focus* 22 : E6, 2007

24. Weinstein JN, Tosteson TD, Lurie JD, Tosteson AN, Blood E, Hanscom B, et al. : Surgical versus nonsurgical therapy for lumbar spinal stenosis. *N Engl J Med* 358 : 794-810, 2008
25. Wiseman CM, Lindsey DP, Fredrick AD, Yerby SA : The effect of an interspinous process implant on facet loading during extension. *Spine (Phila Pa 1976)* 30 : 903-907, 2005
26. Xu WX, Wang J, Lu D, Wu Z, Zhu WM, Zhang C : [Surgical treatment for lumbar spinal stenosis by different methods.] *Zhongguo Gu Shang* 22 : 738-740, 2009
27. Yong-Hing K, Kirkaldy-Willis WH : The pathophysiology of degenerative disease of the lumbar spine. *Orthop Clin North Am* 14 : 491-504, 1983