

## Laboratory Investigation

# Morphometric Study of the Nerve Roots Around the Lateral Mass for Posterior Foraminotomy

Jae-Chan Hwang, M.D.,<sup>1</sup> Hak-Geun Bae, M.D., Ph.D.,<sup>2</sup> Sung-Won Cho, M.D., Ph.D.,<sup>1\*</sup> Sung-Jin Cho, M.D., Ph.D.,<sup>1</sup> Hyung-Ki Park, M.D., Ph.D.,<sup>1</sup> Jae-Chil Chang, M.D., Ph.D.<sup>1</sup>

Department of Neurosurgery,<sup>1</sup> College of Medicine, Soonchunhyang University, Seoul, Korea

Department of Neurosurgery,<sup>2</sup> College of Medicine, Soonchunhyang University, Cheonan, Korea

**Objective :** Morphometric data on dorsal cervical anatomy were examined in an effort to protect the nerve root near the lateral mass during posterior foraminotomy.

**Methods :** Using 25 adult formalin-fixed cadaveric cervical spines, measurements were taken at the lateral mass from C3 to C7 via a total laminectomy and a medial one-half facetectomy. The morphometric relationship between the nerve roots and structures of the lateral mass was investigated. Results from both genders were compared.

**Results :** Following the total laminectomy, from C3 to C7, the mean of the vertical distance from the medial point of the facet (MPF) of the lateral mass to the axilla of the root origin was 3.2-4.7 mm. The whole length of the exposed root had a mean of 4.2-5.8 mm. Following a medial one-half facetectomy, from C3 to C7, the mean of the vertical distance to the axilla of the root origin was 2.1-3.4 mm, based on the MPF. Mean vertical distances from the MPF to the medial point of the root that crossed the inferior margin of the intervertebral disc were 1.2-2.7 mm. The mean distance of the exposed root was 8.2-9.0 mm, and the mean angle between the dura and the nerve root was significantly different between males and females, at 53.4-68.4°.

**Conclusion :** These data will aid in reducing root injuries during posterior cervical foraminotomy.

**KEY WORDS :** Posterior foraminotomy · Spinal nerve roots · Laminectomy · Facetectomy · Cadaveric study.

## INTRODUCTION

Although the anterior approach has been well-established as the standard treatment modality for cervical spine diseases, excellent treatment outcomes have also been achieved with the posterior approach. Great advances have been made with the posterior approach with the development of equipment such as the microscope and the endoscope. Advantages of the posterior approach include an ability to avoid damage to vital structures located in the anterior area of the cervical spine (i.e., the trachea, esophagus, internal carotid artery, vertebral artery, thoracic duct, and recurrent laryngeal

nerve), an ability to prevent structural and biomechanical damage to the remaining vertebral disc by preserving it, an ability to lower the morbidity associated with the joint, and an ability to reduce the occurrence of complications associated with the bone graft, as well as degenerative changes at the adjacent joint<sup>2,9-11,16,18</sup>. In cases where only dorsal decompression of the nerve root is performed and only fragments of the intervertebral disc are removed, excellent treatment outcomes have also been reported<sup>7,8,12,20</sup>. When a posterior approach is performed for a posterior foraminotomy or for the removal of an intervertebral disc, it is essential to understand the anatomical relationships between the dura, where the nerve root originates, and the lateral mass, where the nerve root passes. It is also important to understand the morphological relationships between the dura, lateral mass, and intervertebral disc to maximize the effect of the decompression while minimizing any impairment of motor function.

To define the anatomical relationship between the facet

\* Sung-Won Cho, M.D. moved to Department of Neurosurgery, Seo Ulsan Boram Hospital, Ulsan Korea

Received : January 21, 2010 • Revised : April 8, 2010

Accepted : May 10, 2010

Address for reprints : Jae-Chil Chang, M.D., Ph.D.

Department of Neurosurgery, College of Medicine, Soonchunhyang University, 22 Daesagwan-gil, Yongsan-gu, Seoul 140-743, Korea

Tel : +82-2-709-9268, Fax : +82-2-792-5976

E-mail : j7chang@hosp.sch.ac.kr

and the nerve root crossing the intervertebral disc, morphometric analyses of the nerve root and the lateral mass were conducted after a total laminectomy and a medial one-half facetectomy of the cervical spine using adult cadavers. The findings presented here will assist neurosurgeons in safely performing posterior laminotomies in the absence of a navigational aid.

## MATERIALS AND METHODS

Twenty-five adult cadavers (19 males, 6 females) with a mean age of 60.8 (range, 23-75) were fixed in a prone position in a mixture of formalin, phenol, alcohol, and glycerin. Posterior muscles of the cervical spine were removed, and the posterior area was completely exposed to observe areas ranging from the second cervical spine to the first thoracic spine (Fig. 1). The cadavers were assigned to two groups, one for total laminectomy analysis and the other for medial one-half facetectomy analysis.

A total laminectomy was performed on C3-7 and included both left and right sides. The following measurements were obtained, based on the medial point of the facet (MPF) of the lateral mass : the horizontal distance to the lateral margin of the dura, the vertical distance to the axilla of the nerve root, and the length of the exposed nerve root (Fig. 2).

Following the medial one-half facetectomy, the following measurements were also obtained, based on the MPF of the lateral mass : the horizontal distance to the lateral surface of the dura, the vertical distance to the axilla of the nerve root, the horizontal and vertical distances to the medial point of the root crossing the inferior margin of the intervertebral disc, the length of the exposed nerve root, and the angle between the nerve root and the lateral margin of the dura (Fig. 3).

A standard meter and a goniometer were used to obtain measurements, and all measurements were performed by a single investigator to minimize error. Factors for statistical analysis of measurements were the spinal segment, age, and gender. The SPSS software (version 11.0) was used to perform a t-test with the threshold *p* value set at 0.05.

## RESULTS

### Anatomical structure of the cervical lateral mass

The cervical lateral mass is posterior and lateral to the cervical spine (Fig. 1). Medially, it forms a margin with the lamina and laterally forms a margin with the base transverse process. The superior and inferior articular processes form a facet connecting adjacent vertebrae on the lateral side. In

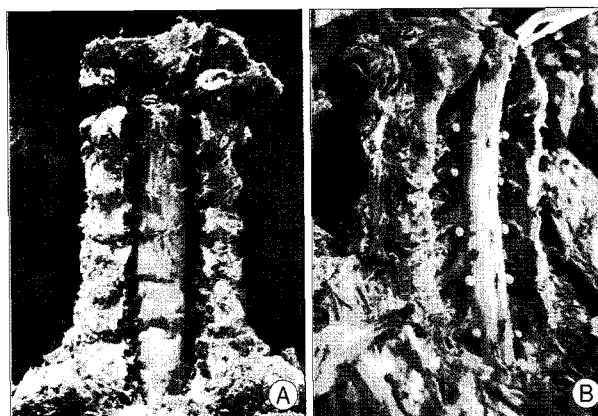

Fig. 1. Photographs showing cadaver specimens after total laminectomy (A) and after medial one-half facetectomy (B). After medial one-half facetectomy, each nerve root crossing the corresponding intervertebral disc (pink pin) is clearly visible.



Fig. 2. Photograph schematic view showing the measured parameters after total laminectomy. A : MPF of the lateral mass after total laminectomy, a : horizontal distance from point A to the lateral surface of the dura, b : vertical distance from point A to the axilla of the nerve root, c : length of the exposed nerve root.




Fig. 3. Photograph and schematic drawing showing the measured parameters after medial one-half facetectomy, B : after medial one-half facetectomy, the MPF of the lateral mass, C : point medial to the nerve root crossing the inferior surface of the intervertebral disc, a : horizontal distance from point B to the lateral surface of dura, b : vertical distance from point B to the axilla of the root, c : horizontal distance from point B to point C, d : vertical distance from point B to point C, e : length of the exposed nerve root, f : angle between the nerve root and the lateral margin of dura.

the lower cervical spine, the facet shows an increased slant towards the cephalo-caudal direction. The facet of the cervical spine is closely directed to the axial plane, making rotation, flexion, and extension movements possible. The spinous process is horizontally attached to the posterior arch and has an increasing slope in the lower cervical spine.

**Morphological measurements following total laminectomy**

Table 1 shows the results of the measurement of each segment, and Table 2 illustrates the results corresponding to gender and each spinal segment. Left and right side measurements were summed and then averaged.

**Horizontal distance to the lateral surface of the dura**

The horizontal distance of C3-4 to the lateral surface of the dura was 3.7 ± 1.0 mm and was the shortest. The horizontal distance further widened towards the lower level, with the longest being that of C6-7, at 4.0 ± 1.1 mm. The difference between the horizontal distance of males (4.0 ± 1.0 mm) and females (3.7 ± 1.1 mm) was not significant (*p* = 1.417).

**Table 1.** Variables measured at each vertebral level after total laminectomy in 50 specimens from 25 cadavers (Group A)

Measured variables	Distance in mm (mean ± SD)				
	C3	C4	C5	C6	C7
Horizontal distance from point A to the lateral surface of the dura	3.8 ± 1.1	3.7 ± 1.0	3.9 ± 1.1	4.0 ± 1.2	4.1 ± 1.1
Vertical distance from point A to the axilla of nerve root	3.8 ± 2.6	4.3 ± 3.1	3.2 ± 2.2	3.9 ± 2.53	4.7 ± 2.4
Length of exposed nerve root	4.2 ± 1.5	5.1 ± 1.2	5.1 ± 1.4	5.8 ± 1.8	5.6 ± 1.8

Point A : the medial point of the facet of the lateral mass after total laminectomy. SD : standard deviation

**Table 2.** Gender differences in the biometric data after total laminectomy in 50 specimens of 25 cadavers (Group A)

Measured variables	Level of vertebra	Distance in mm and degrees (mean ± SD)		
		Male	Female	T-test
Horizontal distance from point A to the lateral surface of the dura	C3	3.9 ± 0.9	3.5 ± 1.6	0.628
	C4	3.8 ± 0.9	3.5 ± 1.2	0.512
	C5	4.0 ± 1.1	3.9 ± 0.9	0.843
	C6	4.2 ± 1.1	3.5 ± 1.4	1.198
	C7	4.1 ± 1.1	4.2 ± 1.0	0.165
	Total	4.0 ± 1.0	3.7 ± 1.1	1.417
Vertical distance from point A to the axilla of nerve root	C3	3.7 ± 2.2	3.8 ± 3.6	0.076
	C4	4.7 ± 3.3	3.5 ± 2.7	0.840
	C5	3.4 ± 2.2	2.7 ± 2.3	0.652
	C6	4.0 ± 2.4	3.5 ± 3.1	0.376
	C7	5.2 ± 2.0	3.5 ± 3.1	1.464
	Total	4.3 ± 2.4	3.0 ± 2.8	2.501
	Length of exposed nerve root	C3	4.3 ± 1.6	3.7 ± 1.1
C4		5.3 ± 1.3	4.3 ± 0.7	1.863
C5		5.2 ± 1.5	4.8 ± 0.7	0.438
C6		5.8 ± 1.9	6.1 ± 2.1	0.318
C7		5.4 ± 1.8	6.5 ± 2.0	1.019
Total		5.2 ± 1.6	4.9 ± 1.7	0.764

Point A : the medial point of the facet of the lateral mass after total laminectomy. SD : standard deviation

**Vertical distance to the axilla of the nerve root**

The vertical distances to the axilla of the C5, C3, and C7 nerve roots were 3.2 ± 2.2, 3.8 ± 2.6, and 4.7 ± 2.4 mm, respectively. There was no significant difference (*p* = 2.501) between the vertical distance in males (4.3 ± 2.4 mm) and females (3.0 ± 2.8 mm).

**Length of the exposed nerve root**

The shortest length, corresponding to the exposed C3 nerve root, was 4.2 ± 1.5 mm, while that of the C6 nerve root was 5.8 ± 1.8 mm. This indicates that length increased in the lower cervical levels. By gender, the length of the exposed nerve root was 5.2 ± 1.6 mm (males) and 4.9 ± 1.7 mm (females).

**Morphological measurements following medial one-half facetectomy (Table 3, 4)**

**Horizontal distance to the lateral surface of the dura**

The mean horizontal distance of C2-3 to C6-7 to the lateral surface of the dura was within 8-9 mm. Compared with the total laminectomy, the horizontal distance to the dura was longer, by 5.0 mm on average. The horizontal distances were 9.0 ± 1.9 and 8.2 ± 1.9 mm in males and females, respectively.

**Vertical distance to the axilla of the nerve root**

The vertical distance was 2.1-3.4 mm from the MPF to the axilla of the C3-7 nerve roots. Compared with the findings following the total laminectomy, the posterior lateral mass had an ascending form towards the lateral side, with a shorter vertical distance (1-2 mm). There was no significant difference (*p* = 0.139) between the vertical distance in males and females (2.7 ± 3.1 and 3.4 ± 3.1 mm, respectively).

**Horizontal distance from the MPF to the medial point of the root crossing the inferior margin of the intervertebral disc**

The horizontal distance to the point between the medial margin of the C3-7 nerve roots and the inferior margin of the intervertebral disc was within 6-7 mm. In the lower cervical spine,

the horizontal distance increased. The longest horizontal distance,  $6.8 \pm 2.4$  mm, was near the C5 nerve root. The horizontal distance between males and females was not significantly different ( $6.7 \pm 2.3$  and  $5.9 \pm 2.0$  mm, respectively;  $p = 0.056$ ).

#### Vertical distance between the medial margin of the root and the inferior margin of the intervertebral disc

The vertical distance was within 1-3 mm for the C3 to C7 nerve roots. With males at  $1.8 \pm 2.6$  mm and females at  $2.1 \pm 2.1$  mm, there was no significant difference in the overall vertical distance ( $p = 0.462$ ).

#### Length of the exposed nerve root

The lengths of the exposed C3-7 nerve roots were within 8.2-9.0 mm. The longest mean length was  $9.0 \pm 1.8$  mm and corresponds to the C5 nerve root. In the lower level of the cervical spine, the length of the exposed nerve root decreased, with C7 as the shortest ( $8.2 \pm 1.8$  mm). The average length of the nerve root in males was  $8.5 \pm 2.0$  mm, compared with  $9.2 \pm 1.6$  mm in females.

#### Angle between the nerve root and the lateral margin of the dura

The smallest angle, at  $59.4 \pm 21.8^\circ$ , corresponded to the C5 nerve root. The angle of the C7 nerve root was  $68.4 \pm 22.4^\circ$ . There was a statistically significant difference ( $p = 0.011$ ) between the mean angle in males ( $65.4 \pm 22.9^\circ$ ) and females ( $56.5 \pm 19.2^\circ$ ). Thus, the nerve root passed from the dura at a greater angle in males.

## DISCUSSION

Representative surgical treatments for cervical spine disease include the anterior and posterior approaches. In 1934, Mixter, Barr, et al.<sup>5)</sup> used a laminectomy to treat 19 patients with vertebral disc disease. In 1946, Scoville<sup>19)</sup> reported a surgical treatment called keyhole foraminotomy at a Harvey Cushing meeting. In the 1950s, Smith and Robinson<sup>21)</sup> and Cloward<sup>6)</sup> introduced decompression and fusion, via the anterior approach. Since then, remarkable advances using both the anterior and the posterior approaches have been made to surgically treat patients with degenerative cervical spine diseases. Although the posterior

approach has greatly improved treatment outcomes, the anterior approach has been more commonly used by neurosurgeons to treat cervical spine lesions, including radiating pain from the cervical nerve root.

In 1983, Raynor<sup>13)</sup> compared the removal of the medial one-half of the posterior joint between the anterior and posterior approaches, and obtained a nerve root approximately 3-5 mm long. It was noted, however, that the anterior approach needed a more in-depth dissection of structures to obtain an identical range. In recent years, renewed interest has gained by many surgeons with regard to the posterior approach to treat cervical spine lesions, because of advancements in minimally invasive surgery and endoscopy, with a series of reports detailing excellent treatment outcomes<sup>1,2,9-11,15-18)</sup>.

In cases where foraminotomy or discectomy is performed via the posterior approach (using microscopy, endoscopy, or both), it is necessary for the bones to be removed once the lateral mass at the site of the lesion is secured and for the muscles to be dissected to a minimal extent, using a narrow retractor. To do this, the lateral part of the lamina should initially be ground with a 3-mm high-speed drill; the drill is generally used to remove the lamina at the point where it meets the lateral mass. This allows for visibility of the dura, which would be located closer to the medial side of the drill. Special attention is required for high cervical spines because the dura and the lateral mass are closely located (indeed, in our series, the horizontal distance of C3 and C4 was 3 and 4 mm, respectively, for the MPF of the lateral mass to the dura after total laminectomy).

Based on the results obtained after total laminectomy, the vertical distance to the axilla of the nerve root was 3.2 mm for the C5 nerve root, which was the shortest. For cases in

**Table 3.** Data of variables measured at each vertebral level after medial one-half facetectomy in 50 specimens from 25 cadavers (Group B)

Measured variables	Distance in mm and degrees (mean $\pm$ SD)				
	C3	C4	C5	C6	C7
Horizontal distance from point B to the lateral surface of dura	$8.4 \pm 1.7$	$8.6 \pm 1.9$	$9.0 \pm 2.0$	$9.0 \pm 2.0$	$8.9 \pm 2.0$
Vertical distance from point B to the axilla of the root	$3.4 \pm 3.3$	$2.7 \pm 2.9$	$2.1 \pm 2.8$	$2.8 \pm 3.0$	$3.4 \pm 3.4$
Horizontal distance from point B to point C	$6.4 \pm 2.0$	$6.7 \pm 2.5$	$6.8 \pm 2.4$	$6.6 \pm 2.6$	$6.1 \pm 2.0$
Vertical distance from point B to point C	$2.7 \pm 2.3$	$1.9 \pm 2.0$	$1.2 \pm 2.16$	$1.2 \pm 2.1$	$2.4 \pm 3.3$
Length of exposed nerve root	$8.5 \pm 1.8$	$8.7 \pm 2.3$	$9.0 \pm 1.8$	$9.0 \pm 1.9$	$8.2 \pm 1.8$
Angle between the nerve root and the lateral margin of dura	$63.9 \pm 22.1$	$61.1 \pm 21.2$	$59.4 \pm 21.8$	$63.4 \pm 22.4$	$68.4 \pm 22.4$

Point B : After medial one-half facetectomy, the medial point of the facet of lateral mass. Point C : the cross point between medial margin of the root and the inferior margin of the intervertebral disc. SD : standard deviation

**Table 4.** Gender difference of the biometric data after medial one-half facetectomy in 50 specimens of 25 cadavers (Group B)

Measured variables	Level of vertebra	Distance in mm and degrees (mean ± SD)			T-test
		Male	Female		
Horizontal distance from point B to the lateral surface of dura	C3	8.3 ± 1.7	8.7 ± 2.0	0.665	
	C4	8.6 ± 2.2	8.5 ± 1.3	0.245	
	C5	9.1 ± 2.1	9.0 ± 1.6	0.136	
	C6	8.9 ± 2.1	9.3 ± 2.1	0.555	
	C7	8.6 ± 2.1	9.8 ± 1.6	1.677	
	Total	8.2 ± 1.9	9.0 ± 1.9	0.495	
Vertical distance from point B to the axilla of the root	C3	3.2 ± 3.3	3.9 ± 3.4	0.564	
	C4	2.7 ± 2.9	2.7 ± 3.2	0.014	
	C5	2.0 ± 2.8	2.6 ± 3.1	0.688	
	C6	2.4 ± 2.7	3.9 ± 3.6	1.546	
	C7	3.0 ± 3.5	4.8 ± 2.9	1.514	
	Total	2.7 ± 3.1	3.4 ± 3.1	0.139	
Horizontal distance from point B to point C	C3	6.6 ± 2.0	5.3 ± 1.6	1.585	
	C4	6.9 ± 2.7	6.3 ± 2.1	0.721	
	C5	7.1 ± 2.4	5.9 ± 2.5	1.292	
	C6	6.7 ± 2.7	6.3 ± 2.5	0.427	
	C7	6.0 ± 2.1	6.6 ± 1.7	0.731	
	Total	6.7 ± 2.3	5.9 ± 2.0	0.056	
Vertical distance from point B to point C	C3	2.7 ± 2.3	2.7 ± 2.9	0.041	
	C4	2.2 ± 2.1	1.1 ± 1.2	1.658	
	C5	1.2 ± 2.5	1.1 ± 1.0	0.038	
	C6	0.9 ± 2.4	1.8 ± 1.4	1.101	
	C7	2.2 ± 3.6	3.0 ± 2.2	0.584	
	Total	1.8 ± 2.6	2.1 ± 2.1	0.462	
Length of exposed nerve root	C3	8.4 ± 1.9	9.0 ± 1.6	0.814	
	C4	8.7 ± 2.6	8.8 ± 1.3	0.504	
	C5	8.9 ± 2.0	9.3 ± 1.2	0.676	
	C6	8.5 ± 1.9	9.9 ± 1.7	2.208	
	C7	7.8 ± 1.8	9.2 ± 1.2	2.330	
	Total	8.5 ± 2.0	9.2 ± 1.64	2.057	
Angle between the nerve root and the lateral margin of dura	C3	65.9 ± 22.7	57.1 ± 19.9	1.004	
	C4	62.2 ± 21.2	58.1 ± 22.3	0.196	
	C5	61.6 ± 21.5	53.1 ± 22.4	1.168	
	C6	67.4 ± 24.6	51.8 ± 19.0	2.003	
	C7	72.7 ± 22.7	54.5 ± 15.7	2.357	
	Total	65.4 ± 22.9	56.5 ± 19.2	0.011*	

\*These results indicate that the nerve root was passed from the dura at a smoother angle. Point B : After medial one-half facetectomy, the medial point of the facet of lateral mass, Point C : the cross point between medial margin of the root and the inferior margin of the intervertebral disc. SD : standard deviation

which the latero-inferior part of the lamina is removed using a 3-mm high-speed drill, special attention is needed. Interestingly, the origin of each nerve root is initiated at a location 5 mm superior to the MPF. This indicates that when the decompressive laminectomy of each segment is performed, this procedure, performed primarily for the superior rather than the inferior lamina, should prevent unnecessary damage to normal tissue. We removed the cortical bone on the latero-inferior side of the superior lamina using a 3-mm cutting drill with the aid of a micros-

cope. Subsequently, the medial cortical bone was removed using a diamond drill under the continuous irrigation of normal saline. The remaining cortical bone was removed with a micro-curette. As a result, attempts were made to achieve a partial hemostatic effect and to prevent any nerve damage. The dissection of the medial one-third of the lateral mass should be done and this procedure should not exceed more than one-half of the lateral mass.

Biomechanical studies of this rationale have been alluded to in several papers. Raynor<sup>14)</sup> noted that bone fracture might occur during the loading, within the physiologic range, when a 50% or greater facetectomy is performed. Zdeblick et al.<sup>22)</sup> also noted that torsional hyper-mobility might be generated when the facet is dissected for a facetectomy of at least 50%. In recent years, Chen et al.<sup>4)</sup> reported that a minimal extent of movement occurs during a keyhole foraminotomy, compared with a normal procedure. Movement is 18% more likely to occur when lateral bending is done on the side where the facetectomy is performed. Within the range of medial facetectomy, to confirm the intervertebral disc and to remove the lesions without damaging the nerve root, the absolute surgical location must be known.

Based on the results obtained from the medial one-half facetectomy, spare space was generated to such an extent that the resulting horizontal distance

to the dura was 8-9 mm and the vertical distance was 2-3 mm. In cases of medial one-half facetectomy, the vertical distance from the dura to where the axilla of the C5 nerve root originates was the shortest (2.1 mm). Because the C5 nerve root has the highest risk of causing a nerve root injury, more attention should be focused on the C5 nerve root.

Chang et al.<sup>3)</sup> reported that the width of the dura was greater in the C5-6 cervical spine. Our results are based on the same phenomena and are consistent with the previous study.

The relationship with the intervertebral disc is also important. The horizontal distance between the medial margin of the nerve root and the inferior margin of the intervertebral disc, following the dissection of the medial one-half facetectomy, is 6-7 mm. Its vertical distance is 1.2-2.7 mm.

These results were also seen in our series, again indicating that special emphasis must be placed on this particular surgical procedure. To remove the herniated intervertebral disc and hypertrophied osteophyte, a nerve hook is placed in the axillary region. This is retracted superiorly, exposing the intervertebral disc. In our series, after the medial one-half facetectomy, the vertical distance from the medial margin of the C5-6 nerve root to the inferior margin of the intervertebral disc was 1.2 mm; the angle measured 59° for the C5 nerve root, and this was the smallest. Chang et al.<sup>3)</sup> reported that the width of the dura was the greatest at C5-6, so was the angle between the nerve root and the lateral margin of the dura.

Due to a shortage of spare space, C5-6 nerve roots require a greater degree of retraction than other nerve roots to obtain sufficient surgical vision. The resulting complications must also be considered. For this reason, the removal of the pedicle, which is located superior to the inferior facet, can secure the axillary region for the appropriate nerve root for cases in which osteophyte formation is severe. The nerve root and its adjacent dura and the epidural vein are severely compressed by the bone at all times. Surgical damage predominantly occurs during the decompression of these lesions. Sometimes, a ventral decompression of the nerve root is solely performed, as well as using the ventral osteophyte and removing intervertebral discs that are secured under surgical vision<sup>7,8,12,20)</sup>. A sufficient degree of decompression can be confirmed based on findings that the nerve root is released freely when using a probe to manipulate an intervertebral foramen.

## CONCLUSION

The cervical spines of 25 adult cadavers were used to apply a posterior foraminotomy via the posterior approach. The landmark formed by the MPF of the lateral mass following a medial facetectomy, the relative relationship between the nerve root exposed on the medial side of the superior and inferior articular surface of the lateral mass, and the correlation between the nerve root and the dura mater provide new information about the nerve roots and the dural theca near the lateral mass on the dorsal surface of the cervical spine. These findings can aid in reducing root injury during minimal decompression via a posterior foraminotomy.

## References

1. Adamson TE : The impact of minimally invasive cervical spine surgery. *J Neurosurg Spine* 1 : 43-46, 2004
2. Burke TG, Caputy A : Microendoscopic posterior cervical foraminotomy : a cadaveric model and clinical application for cervical radiculopathy. *J Neurosurg* 93 : 126-129, 2000
3. Chang JC, Park HK, Bae HG, Cho SJ, Choi SK, Byun PJ : Morphometric measurement of the anatomical landmark in anterior cervical microforaminotomy. *J Korean Neurosurg Soc* 39 : 340-346, 2006
4. Chen BH, Natarajan RN, An HS, Andersson GB : Comparison of biomechanical response to surgical procedures used for cervical radiculopathy : posterior keyhole foraminotomy versus anterior foraminotomy and discectomy versus anterior discectomy with fusion. *J Spinal Disord* 14 : 17-20, 2001
5. Clark CR : *The Cervical Spine (4th)*. Lippincott Williams & Wilkins, 2005, pp1031-1042
6. Cloward RB : The anterior approach for removal of ruptured cervical disks. *J Neurosurg* 15 : 602-617, 1958
7. Collias JC, Roberts MP : Posterior surgical approaches for cervical disk herniation and spondylotic myelopathy. In : Schmidek HH, Sweet WH, eds. *Operative neurosurgical techniques : indications, methods and results, 4th ed.* Philadelphia : WB Saunders, 2000, pp2016-2027
8. Davis RA : A long-term outcome study of 170 surgically treated patients with compressive cervical radiculopathy. *Surg Neurol* 46 : 523-530; discussion 530-533, 1996
9. Fessler RG, Khoo LT : Minimally invasive cervical microendoscopic foraminotomy : an initial clinical experience. *Neurosurgery* 51 : S37-S45, 2002
10. Gala VC, O'Toole JE, Voyadzis JM, Fessler RG : Posterior minimally invasive approaches for the cervical spine. *Orthop Clin North Am* 38 : 339-349, 2007
11. Hilton DL Jr : Minimally invasive tubular access for posterior cervical foraminotomy with three-dimensional microscopic visualization and localization with anterior/posterior imaging. *Spine J* 7 : 154-158, 2007
12. Krupp W, Schattke H, Mücke R : Clinical results of the foraminotomy as described by Frykholm for the treatment of lateral cervical disc herniation. *Acta Neurochir (Wien)* 107 : 22-29, 1990
13. Raynor RB : Anterior or posterior approach to the cervical spine : an anatomical and radiographic evaluation and comparison. *Neurosurgery* 12 : 7-13, 1983
14. Raynor RB, Pugh J, Shapiro I : Cervical facetectomy and its effect on spine strength. *J Neurosurg* 63 : 278-282, 1985
15. Roh SW, Kim DH, Cardoso AC, Fessler RG : Endoscopic foraminotomy using MED system in cadaveric specimens. *Spine (Phila Pa 1976)* 25 : 260-264, 2000
16. Roh SW, Rhim SC : Endoscopic cervical foraminotomy using endoscopic discectomy (MED) system in cadaveric specimens. *J Korean Neurosurg Soc* 28 : 1100-1105, 1999
17. Ruetten S, Komp M, Merk H, Godolias G : Full-endoscopic cervical posterior foraminotomy for the operation of lateral disc herniations using 5.9-mm endoscopes : a prospective, randomized, controlled study. *Spine (Phila Pa 1976)* 33 : 940-948, 2008
18. Saringer WF, Reddy B, Nöbauer-Huhmann I, Regatschnig R, Reddy M, Tschabitscher M, et al. : Endoscopic anterior cervical foraminotomy for unilateral radiculopathy : anatomical morphometric analysis and preliminary clinical experience. *J Neurosurg* 98 : 171-180, 2003
19. Scoville WB : Types of cervical disk lesions and their surgical approaches. *JAMA* 196 : 479-481, 1966
20. Scoville WB, Dohrmann GJ, Corkill G : Late results of cervical disc surgery. *J Neurosurg* 45 : 203-210, 1976
21. Smith GW, Robinson RA : The treatment of certain cervical-spine

disorders by anterior removal of the intervertebral disc and interbody fusion. **J Bone Joint Surg Am 40-A** : 607-624, 1958  
22. Zdeblick TA, Zou D, Warden KE, McCabe R, Kunz D, Vanderby

R : Cervical stability after foraminotomy. A biomechanical in vitro analysis. **J Bone Joint Surg Am 74** : 22-27, 1992