

Case Report

Clinical Experience and Management of Cervico-Thoracic Epidural Hematoma

Sang-Soak Ahn, M.D., Young-Jin Song, M.D.

Department of Neurosurgery, College of Medicine, Dong-A University, Busan, Korea

Spinal epidural hematoma (SEH) causing acute myelopathy is rare. The usual clinical presentation of a SEH is sudden severe neck or back pain that progresses toward paraparesis or quadriplegia, depending on the level of the lesion. Recent studies have shown that early decompressive surgery is very important for patient's recovery. We experienced five patients of cervico-thoracic epidural hematomas associated with neurologic deficits that were treated successfully with surgical intervention.

KEY WORDS : Intraspinal · Epidural · Hematoma · Laminectomy.

INTRODUCTION

Spinal epidural hematoma (SEH) which causing acute myelopathy is rare^{1,2,4,5,8,12,14}. Repeated epidural injection, preexisting coagulopathy, and the use of anticoagulant or antiplatelet medications are known risk factors of SEH^{12,14}. Injection-related epidural hematoma in the cervico-thoracic spine have rarely been reported^{1,4,5,12,14}. Spontaneous SEH is also a relatively rare disease^{2,10}. Hematologic problem and trauma are also the risk factors of SEH.

In this study, we report five patients who experienced cervico-thoracic epidural hematoma with neurological deteriorations.

CASE REPORT

We reviewed five patients who were admitted to our hospital with neurological deteriorations from 2006 to 2009. The subjects include 1 male and 4 female patients, and their ages ranged from 36 to 66 years old. There were no medical problems and specific findings in 3 patients on past history, and one patient was taking coumadin that had

been started for their heart problems. The other one patient had a history of hypothyroidism and diabetes mellitus. Two patients had a history of cervical nerve-root blocks, and one patient had a history of minor vertebral trauma. All patients complained of motor weakness and sensory changes and underwent an emergent operation.

The hematologic examinations, simple radiographies and magnetic resonance images were performed in all patients.

SEH was seen in all five cases. Three patients had a history of cervical nerve-root blocks. One patient was taking coumadin that had been started for valvular heart disease, and other one had a history of minor vertebral trauma. The level of hematoma extended from cervical to thoracic area (Table 1).

Emergent surgeries were performed in all patients. All five patients with epidural hematoma slowly regained strength and sensation. By the time of the one-month follow-up, they had regained full strength and sensation (Table 2).

Case 1

A 66-year-old woman was admitted to the hospital because of acute onset of left lower extremity motor weakness (grade IV), and right extremities sensory changes and gait disturbance. She was taking coumadin that had been started for mitral valve stenosis and her PT, PTT, INR were checked highly. MRI of the cervical spine showed an oval shaped lesion in the dorsal and left lateral side of the epidural space from the C2 to C5 levels showing high signal

• Received : August 17, 2009 • Revised : February 5, 2010
• Accepted : February 8, 2010
• Address for reprints : Young-Jin Song, M.D.
Department of Neurosurgery, College of Medicine, Dong-A University,
Dongdaesin-dong 3-ga, Seo-gu, Busan 602-715, Korea
Tel : +82-51-240-5241, Fax : +82-51-242-6714
E-mail : ns2000@daunet.ac.kr

Table 1. Demographic characteristics of cases

| Patients | Sex/Age | Location | Extension | Predisposing condition | Nerve-root block | Symptom | Operation |
|----------|---------|----------|-----------|------------------------|------------------|-----------------------------------|--------------|
| 1 | F/56 | Epidural | C4-C6 | DM & hypothyroidism | + | Motor weakness & sensory changes | After 5 hour |
| 2 | M/45 | Epidural | C3-C5 | None | + | Quadriplegia | After 6 hour |
| 3 | F/66 | Epidural | C2-C5 | Coumadin MVS | - | Motor weakness & gait disturbance | After 8 hour |
| 4 | F/57 | Epidural | C6-T4 | Trauma | - | Paraplegia | After 7 hour |
| 5 | F/36 | Epidural | C7-T4 | None | - | Paraplegia | After 6 hour |

The table shows each case of spinal epidural hematoma according to sex/age, location, extent of lesion, predisposing condition, nerve-root block, symptom and operation. DM : diabetes mellitus, MVS : mitral valve stenosis

Table 2. Preoperative and postoperative neurological status according to the Modified Frankel Scale

| Group | Criteria | Preop. | Postop. |
|-------|---------------------------------------|--------|---------|
| A | No neurological function | - | - |
| B | Preservation of sensory | - | - |
| C | Inadequate motor function | 5 | - |
| Da | Allowing ambulation with assistance | - | - |
| Db | Self ambulation with minor difficulty | - | 1 |
| E | Normal neural status | - | 4 |

hematoma was grossly total removed. After surgery, the strength in the patient's extremities improved and 3 weeks later, she was fully recovered and discharged without any neurological problems.

Case 2

A 57-year-old woman was presented to the hospital because of acute onset of paraplegia developed 2 hour prior to admission. She had a history of minor vertebral trauma. She had no past medical history and no abnormal laboratory data. MRI of the cervico-thoracic spine showed an oval shaped lesion in the dorsal and left lateral side of the epidural space from the C6 to T4 levels showing high signal intensity on T1-weighted images and heterogeneous signal intensity on T2-weighted images (Fig. 2A) and spinal cord compression on the dorsal and right lateral sides (Fig. 2B).

Multilevel hemilaminectomy was done, and the strength in the patient's extremities improved.

Case 3

A 36-year-old woman was admitted to the hospital because of weakness of both legs (Gr III) and voiding difficulty. She had no past medical history or trauma and no abnormal laboratory data. MRI of the cervico-thoracic spine showed an oval shaped lesion in the ventral and right lateral side of the epidural space from the C7 to T4 levels showing heterogeneous signal intensity on T2-weighted images (Fig. 3A) and spinal cord compression (Fig. 3B).

Multilevel total laminectomy was done, and the strength in the patient's extremities was improved.

Case 4

A 45-year-old man was admitted to the hospital because of acute onset of quadriplegia that developed 1 hour prior to admission. He developed numbness and weakness after the performance of a cervical nerve-root injection at the

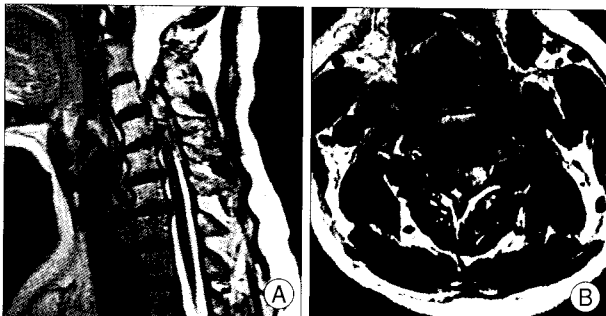


Fig. 1. Case 1. A : Preoperative sagittal T2-weighted image shows epidural hematoma at C2-C5. B : Axial T2-weighted image demonstrates hematoma with cord displacement.

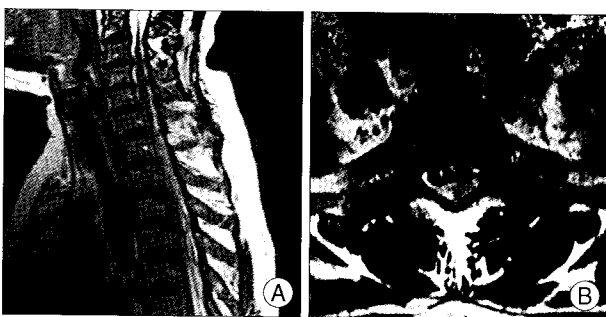


Fig. 2. Case 2. A : Preoperative sagittal T2-weighted image shows epidural hematoma at C6-T4. B : Axial T2-weighted image shows hematoma with cord displacement.

intensity on T1-weighted images and heterogeneous signal intensity on T2-weighted images (Fig. 1A). There was no definite signal change in the spinal cord on MRI even though the lesion displaced the spinal cord toward the right side (Fig. 1B).

Multilevel partial laminectomy was done and epidural

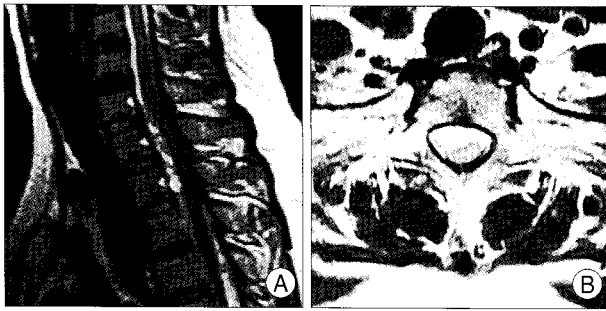

Fig. 3. Case 3. A : Preoperative sagittal T2-weighted image shows epidural hematoma at C7-T4. B : Axial T2-weighted image shows hematoma with cord displacement.

C3-C5 level. He had no past medical history and no abnormal laboratory data. MRI of the cervicothoracic spine showed an irregular dorsal and left lateral epidural mass lesion from the C3 to T3 levels with slightly high signal intensity on T1-weighted images and heterogeneous high signal intensity on T2-weighted images. There was no definite signal change in the spinal cord on MRI even though the lesion displaced the spinal cord toward the right side.

Multilevel partial laminectomy was done and epidural hematoma was grossly total removed. After surgery, the strength in the patient's four extremities was improved and 2 weeks later, he was fully recovered and discharged without any neurological problems.

DISCUSSION

Acute progressive neurological deficits may have a wide variety of causes. Painful paraparesis directs attention to a spinal location of pathology. Besides neoplastic and inflammatory lesions of the spine and spinal cord, SEH has to be taken into account even in patients without recent trauma and with normal blood coagulation and thrombocyte function¹⁰.

Cervical nerve-root blocks can be effective in both diagnosis and treatment of cervical radiculopathy^{1,4,5,11,12,14}. But, complications of this procedure may cause severe neurologic deficits. Epidural hematoma, subdural complications such as respiratory depression and hypotension, postdural puncture headache, paresthesia, neuropathic pain, intracranial hypotension, epidural granuloma, cerebellar infarction, brain-stem herniation have been reported in the literature^{1,4-6,11,12}.

In the case of our patient and in the case of the patient described by Stoll and Sanchez¹⁴, there was a delay in presentation of the paralytic symptoms following the last injections. This may be due to venous bleeding that slowly accumulated over several days^{12,14}. In our case, the patients complained neurologic deteriorations two days after the final injection. Therefore, physicians should be aware and

should inform their patients that potentially devastating neurological complications can occur days after an injection.

Spontaneous SEH is a rare but significant neurological condition². Certain precipitating factors, including anti-coagulant therapy for prosthetic cardiac valves, therapeutic thrombolysis for acute myocardial infarction, hemophilia B, factor XI deficiency, long-term aspirin using as a platelet aggregation inhibitor, and vascular malformation, are suggested to be correlated with spontaneous SEH^{2,8}. Statistically, idiopathic cases account for approximately 40% of all cases². The most common site of a spontaneous SEH is the cervico-thoracic lesion. In our case, one patient who admitted with paraplegia was spontaneous cervico-thoracic epidural hematoma.

The usual clinical presentation of a SEH is sudden severe neck or back pain that progresses toward paraparesis or quadriplegia, depending on the level of the lesion and the nerve root. In high cervical lesion, SEH could cause spinal shock, leading to fatal condition. In our cases, most patients were presented with motor weakness, sensory change, and gait disturbance (Table 1).

MR imaging can quite accurately characterize SEH and hence aid in early diagnosis and institution of definitive treatment¹³. Within 24 hours of onset, the SEH is usually iso-intense on T1-weighted images. Occasionally, there is a mildly or markedly increased signal. On T2-weighted images, there may be homogenous high signal or inhomogenous areas of mixed high and low signal. After 24 h, there is usually a high signal on T1-weighted images. T2-weighted images in most cases are the same signal as CSF. Important differential diagnosis to exclude are epidural hematoma, subdural hematoma, epidural metastasis and epidural abscess^{10,13}.

Early surgical intervention is the general treatment for SEH^{1,2,4,5,8-14}. Rapid diagnosis and emergent surgical treatment maximize the neurological recovery¹³. The procedure includes partial or total laminectomy and hematoma removal. If the exact location of the hematoma cannot be detected and confirmed by image, the dura is opened to exclude the subdural hematoma². In cases with incomplete preoperative sensorimotor deficit, early surgery (within 36 h) are correlated with better outcome. Mortality is higher in patients with cervical or cervico-thoracic hematomas, especially in patients with cardiovascular disease and those on anti-coagulant therapy^{2,13}.

There have been reported cases of spontaneous resolution of spinal epidural hematomas with good neurological recovery^{8,13}. Some authors have proposed conservative management by lumbar puncture¹³. However, prompt surgical decompression should remain the treatment of choice except

in cases whose operative risk is high and in cases with no neurological deficit^{1,2,4,5,8-14}.

CONCLUSION

We experienced five cases of cervico-thoracic SEH. For patient's recovery, early detection of lesion and emergent operation should be required as soon as possible.

References

1. Abbasi A, Malhotra G, Malanga G, Elovic EP, Kahn S : Complications of interlaminar cervical epidural steroid injections : a review of the literature. *Spine (Phila Pa 1976)* 32 : 2144-2151, 2007
2. Baek BS, Hur JW, Kwon KY, Lee HK : Spontaneous spinal epidural hematoma. *J Korean Neurosurg Soc* 44 : 40-42, 2008
3. Benzon HT, Wong HY, Siddiqui T, Ondra S : Caution in performing epidural injections in patients on several antiplatelet drugs. *Anesthesiology* 91 : 1558-1559, 1999
4. Botwin KP, Castellanos R, Rao S, Hanna AF, Torres-Ramos FM, Gruber RD, et al. : Complications of fluoroscopically guided interlaminar cervical epidural injections. *Arch Phys Med Rehabil* 84 : 627-633, 2003
5. Derby R, Lee SH, Kim BJ, Chen Y, Seo KS : Complications following cervical epidural steroid injections by expert interventionalists in 2003. *Pain Physician* 7 : 445-449, 2004
6. Hong WJ, Lee SG, Park CW, Kim WK, Yoo CJ, Park CW : Awareness for serious spinal complications predicted after acupuncture procedures for pain control. *J Korean Neurosurg Soc* 36 : 130-134, 2004
7. Jeon JS, Cho SM, Cho YJ, Hong SK : Hemorrhage in the cisterna magna after acupuncture. *J Korean Neurosurg Soc* 36 : 412-414, 2004
8. Kato S, Seki H, Kosu K : Acute cervical spinal epidural hematoma with spontaneous resolution--case report. *Neurol Med Chir (Tokyo)* 34 : 23-26, 1994
9. Kreppel D, Antoniadis G, Seeling W : Spinal hematoma : a literature survey with meta-analysis of 613 patients. *Neurosurg Rev* 26 : 1-49, 2003
10. Küker W, Thiex R, Friese S, Freudenstein D, Reinges MH, Erne-mann U, et al. : Spinal subdural and epidural haematomas : diagnostic and therapeutic aspects in acute and subacute cases. *Acta Neurochir (Wien)* 142 : 777-785, 2000
11. Lee JH, Lee JK, Seo BR, Moon SJ, Kim JH, Kim SH : Spinal cord injury produced by direct damage during cervical transforaminal epidural injection. *Reg Anesth Pain Med* 33 : 377-379, 2008
12. Lee JY, Nassr A, Ponnappan RK : Epidural hematoma causing paraplegia after a fluoroscopically guided cervical nerve-root injection. A case report. *J Bone Joint Surg Am* 89 : 2037-2039, 2007
13. Ng WH, Lim CC, Ng PY, Tan KK : Spinal epidural haematoma : MRI-aided diagnosis. *J Clin Neurosci* 9 : 92-94, 2002
14. Stoll A, Sanchez M : Epidural hematoma after epidural block : implications for its use in pain management. *Surg Neurol* 57 : 235-240, 2002