

Clinical Article

Long-Term Results of Microsurgical Selective Tibial Neurotomy for Spastic Foot : Comparison of Adult and Child

Jong-Hoon Kim, M.D.,¹ Jae-Il Lee, M.D.,² Min-Su Kim, M.D.,¹ Seong-Ho Kim, M.D., Ph.D.¹

Department of Neurosurgery,¹ College of Medicine, Yeungnam University, Daegu, Korea

Department of Neurosurgery,² Joong Ang Hospital, Ulsan, Korea

Objective : Selective neurotomy is generally a safe, effective, and long-lasting treatment for patients with spastic equinovarus foot deformity. We retrospectively analyzed the results of microsurgical selective tibial neurotomy (STN) for spastic feet in adults and children.

Methods : A neurosurgeon selected 32 patients with 45 spastic feet (adults : 13, children : 32) to undergo microsurgical STN between October 1998 and September 2007. A physician of rehabilitation assessed spasticity pre- and postoperatively, that was based on the Ashworth scale, ankle clonus, and the amplitude of ankle dorsiflexion. The mean postoperative follow-up period was 36.7 months in adults and 42.5 months in children.

Results : Spastic components of the feet were corrected immediately after surgery in both the adult and child groups. The mean Ashworth's grade changed from 3.6 ± 0.40 to 1.6 ± 0.70 in adults and from 3.7 ± 0.69 to 1.4 ± 0.49 in children. Mean ankle clonus decreased markedly, from 1.6 ± 0.79 to 0.3 ± 0.42 in adults and from 1.7 ± 0.65 to 0.3 ± 0.56 in children. The mean amplitude of ankle dorsiflexion was improved, but eight (adults: 4, children: 4) contracted feet needed complementary orthopedic correction for acceptable results.

Conclusion : STN can be effective in the long-term for improving lower limb function and reduction of equinovarus deformity. Our results demonstrate that STN might be an effective procedure for treating localized harmful spastic feet in adults and children.

KEY WORDS : Foot · Spasticity · Surgical procedures · Children · Adults.

INTRODUCTION

Lance defined spasticity in 1980 as "a motor disorder characterized by a velocity-dependent increase in tonic stretch reflexes ('muscle tone') with exaggerated tendon jerk, resulting from hyperexcitability of the stretch reflex, as one of the components of the upper motor neuron syndrome"³⁾. This symptom is observed in various neurological diseases such as cerebral palsy, traumatic brain injury, cerebrovascular disease, spinal cord tumor or trauma, and degenerative diseases of the central nerve system. Medical treatments for spasticity include physiotherapy, perineural injections of alcohol, and intramuscular injections of botuli-

num toxin. When these treatments fail, other options can be considered such as orthopedic surgery (aponeurotomy of gastrocnemius or lengthening of calcaneus tendon) and neurosurgical treatment (intrathecal baclofen, peripheral neurotomy, dorsal rhizotomy, or Dorsal Root Entry Zoneotomy⁹⁾). Stoffel introduced the partial peripheral neurotomy technique in 1910⁷⁾. In 1972, Gros et al. introduced the concept of selectivity to harmful spasticity. Selective peripheral neurotomy (SPN) aims to re-equilibrate the tonic balance between agonist and antagonist muscles by reducing excess spasticity⁶⁾.

Spasticity is decreased by sectioning both afferents and efferent fibers of the stretch-reflex at the level of a muscle's nerve. This eliminates the afferent pathway corresponding to the affected muscle's proprioception and induces paralysis by sectioning the efferent pathway. The principle of neurotomy is based on the different plasticities of these two pathways¹⁵⁾. Thanks to fine microsurgical dissection and mapping with intra-operative electrical nerve stimulation,

• Received : October 15, 2009 • Revised : February 10, 2010
 • Accepted : March 31, 2010
 • Address for reprints : Seong-Ho Kim, M.D., Ph.D.
 Department of Neurosurgery, College of Medicine, Yeungnam University, 317-1 Daemyeong-dong, Nam-gu, Daegu 705-717, Korea
 Tel : +82-53-620-3790, Fax : +82-53-620-3770
 E-mail : shkim@medyu.ac.kr

SPN can, in effect, be selective and effective². SPN is considered a safe, effective, and long-lasting treatment for patients with spastic equinovarus foot deformity³. Successful and satisfying clinical outcomes are possible with careful patient selection and close cooperation between the physician, surgeon, physical and occupational therapists, and nursing staff. This study analyzed retrospectively a comparison of the results of microsurgical STN for spastic feet in adults and children.

MATERIALS AND METHODS

Thirty-two patients with 45 spastic feet (adults : 13, children : 32) were selected to undergo microsurgical STN between October 1998 and September 2007. Eleven of the children were treated for both spastic feet, which affected their gait. The mean ages of the adults and children were 30.7 years (17 to 51 years) and 8.4 years (5 to 15 years), respectively. Nineteen (adults : 2, children : 17) suffered from cerebral palsy, seven (adults : 4, children : 3) had head trauma, and five adults had suffered a stroke. Another child had spinal dysraphism. All patients were included in group I or II of the New York University Patient Group Classification. The clinical features did not differ between adults and children (Table 1). It was analyzed with a Pearson Chi-square test. There were no statistically significant differences in any of the subtypes of deformity between adults and children.

Preoperative assessment

The indication for STN was spasticity that interfered with daily living and resisted conservative treatment (rehabilitation therapies and neurolytic blocks). Most of the patients were referred to neurosurgery from the rehabilitation clinic and all cases were assessed together. The clinical evaluation was followed by a careful discussion and explanation with the patient's family of the procedure's goals and limitations. Surgical planning was determined depending on the clinical examination's results.

Surgical technique

The neurotomy was performed under general anesthesia without pharmacologic muscle relaxants to avoid interference with intraoperative electrical stimulation. Each patient was placed prone and a skin incision was made vertically in the midline around the transverse popliteal line. Each motor branch of the posterior tibial nerve was visually identified by each muscle contraction using electrical stimulation to its motor branches. We partially (50-70% of fascicles, about 10 mm long) resected preoperatively selected motor fascicles

under microscope that innervated the selected spastic muscles responsible for the abnormal posture and functional disability (Fig. 1). On the third postoperative day, the patients started on rehabilitative management, including stretching the ankles' plantar flexor and sitting balance training. After all sutures had been removed two weeks postoperatively, the rehabilitative management focused on strengthening the ankles' dorsiflexors using neuromuscular electrical

Table 1. Clinical features of spastic feet

Deformity	Adults (n = 13)	Children (n = 32)
Equinus	13 (100%)	32 (100%)
Varus	9 (69.2%)	26 (81.3%)
Clonus	7 (53.8%)	19 (59.4%)
Flexion of toes	6 (46.2%)	7 (21.9%)

Table 2. Ashworth scores

Ashworth score	Degree of muscle tone
1	No increase in tone (normal)
2	Slight increase
3	Marked increase, passive movements easy
4	Considerable increase, passive movements difficult
5	Affected part rigid during flexion or extension



Fig. 1. Intraoperative findings after a skin incision showing the tibial nerve and its branches

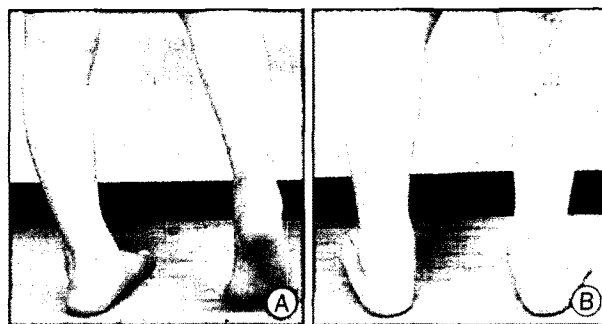


Fig. 2. A : Preoperative photograph showing equinus and varus deformities of a right foot. B : Postoperative photograph showing good correction of deformities.

stimulation, standing balance training, and stretching Achilles tendons using a wedge board.

Postoperative evaluation

A physician of rehabilitation who was not involved in the operations assessed spasticity pre- and postoperatively based on the Ashworth scale (Table 2), ankle clonus, and the amplitude of passive ankle dorsiflexion (Fig. 2). The satisfaction was evaluated via a personal question and a telephone interview in adults, and by asking patients' parents and a personal question in children.

RESULTS

The mean postoperative follow-up period was 36.7 months (12-56 months) in adults and 42.5 months (14-96 months) in children.

Spastic components of the feet were corrected immediately after the operation in both the adults and children (Table 3). The mean Ashworth's scale score was changed from 3.6 ± 0.40 to 1.6 ± 0.70 in adults and from 3.7 ± 0.69 to 1.4 ± 0.49 in children. Mean ankle clonus was decreased markedly, from 1.6 ± 0.79 to 0.3 ± 0.42 in adults and from 1.7 ± 0.65 to 0.3 ± 0.56 in children. The mean amplitude of passive ankle dorsiflexion improved, but eight (adults : 4, children : 4) contracted feet needed complementary orthopedic correction for acceptable results. Most of the patients continued to improve after the postoperative period by continuing the comprehensive rehabilitation. Four pediatric spastic feet recurred in patients who did not vigorously follow the postoperative rehabilitation program. No mortality or morbidity occurred in either group. Only two patients showed surgical wound infection and one adult complained of transient sensory discomfort. The surgical outcomes were classified into four categories (excellent, good, fair, or poor). Satisfaction was rated "excellent" if there was consistently greater than 75% satisfaction, "good" if there was 51-75% satisfaction, "fair" if there was 26-50% satisfaction, and poor if there was less than 25% satisfaction. In adults, the operation's overall satisfaction was 61.6% (including both "excellent" and "good" ratings). It was 81.2% in children (Table 4).

DISCUSSION

Spasticity in the lower limbs leads to an abnormal tonic balance between agonist and antagonist muscles with co-contraction of both agonist and antagonist muscles during

Table 3. Parameters of improvement in spasticity after selective tibial neurotomy

Parameter	Adults		Children	
	Preop (mean)	Postop (mean)	Preop (mean)	Postop (mean)
AS	3.6 ± 0.40	1.6 ± 0.70	3.7 ± 0.69	1.4 ± 0.49
AC	1.6 ± 0.79	0.3 ± 0.42	1.7 ± 0.65	0.3 ± 0.56
APAD (degree)	11.2 ± 1.05	17.6 ± 1.78	11.8 ± 1.15	22.5 ± 1.95

AS : Ashworth scale, AC: ankle clonus, APAD : amplitude of passive ankle dorsiflexion, Preop : preoperative, Postop : postoperative

Table 4. Level of satisfaction of surgical outcomes

Level of satisfaction	Adults	Children
Excellent	3 (23.1%)	10 (31.2%)
Good	5 (38.5%)	16 (50.0%)
Fair	3 (23.1%)	3 (9.4%)
Poor	2 (15.3%)	3 (9.4%)

gait. Lower limb spasticity is a serious problem that affects daily life activities and places obstacles in the path to achieving rehabilitative goals. Stiffness, restricted movement, the development of contractures, and a serious potential for joint complications are associated with muscles affected by spasticity. The management procedures for relieving ankle spasticity are generally divided into nonsurgical (motor point blocks using alcohol or phenol and neuromuscular junction blocks using botulinum toxin type A) and surgical (neurectomy, neurotomy, tendon lengthening, and tendon transfer)¹⁰.

Tendon lengthening and tenotomy can correct ankle contracture or deformity, but they have a significant limitation in that they cannot reduce ankle spasticity. Neurotomy is an effective long-term treatment for spastic equinus feet. Resolution of spasticity via neurotomy improved joint mobility and eventually decreased joint stiffness. Neurotomy allows functional improvement in patients with a spastic equinus foot³.

The most important step is to select good surgical candidates. This selection is always done using a multidisciplinary approach and surgery is indicated only in cases of very severe spasticity, after all noninvasive management procedures have failed. This means after the failure of adequate oral medication and physical treatment, including all the latest approaches, and the suppression of aggravating factors. So, this surgical step is becoming more selective than it used to be and applies only to resistant spasticity.

One of the most frequent muscular compartments involved in this pathology is the posterior muscles of the leg, especially the triceps surae¹¹. So among the many neurotomies performed for spasticity, tibial neurotomies often are done. STN can selectively reduce ankle spasticity because the ankle's equinus and clonus originate from the medial and lateral gasticnemius and soleus muscle, and the varus

of that originates from the tibialis posterior.

The indication for neurotomy can be defined by observing a number of principles¹⁵. Neurotomies are indicated for a localized spastic disorder. Excessive contractures of spastic muscles considerably limit a neurotomy's efficacy, and therefore its value; so an orthopedic procedure combining tendon lengthening and/or transfer and/or arthrodesis is preferable in those cases. Neurotomy is indicated only when no other nonsurgical treatment options are available and after a patient has completed a well-conducted rehabilitation program. An interval of at least a year between the spastic disorder's onset and surgery typically is required. Spasticity must be examined thoroughly and understood clearly before proposing neurotomy.

Tibial nerve neurotomy reduces focal spasticity of plantar flexors (gastrocnemius and soleus), invertors (tibialis posterior), and toe flexors (flexor digitorum longus). A partial neurotomy must include the sectioning of 50-80% (usually 75%) of all branches to a targeted muscle in order for it to be effective.

SPN can unmask residual motor function of antagonist muscles, ease passive movements, increase comfort in daily activities, decrease pain because of spasticity, and improve cosmetic appearance¹⁵. Neurotomy of the gastrocnemius and soleus muscles' motor branches can be proposed with fair tolerance and good efficacy in many patients who show severe equinus, especially when spasticity is severe. SPN is the surgical technique introduced by Sindou and Mertens, who reported an average decrease in the Ashworth score, a correction of the equines and the varus, and an improvement in the ankle's passive and active dorsiflexion¹⁴. STN has another advantage of allowing early commencement of rehabilitative management. Most orthopedic surgery requires casting after operation, which delays early rehabilitation; STN, however, does not¹⁰.

Side effects of neurotomy consist mostly of sensory disorders⁹. Pain, most often transient, and lasting hypoesthesia were found following resection of the motor fascicles controlling the flexor digitorum longus and, at times, the tibialis posterior. The risk of sensory disorders justifies giving patients complete information before surgery and avoiding dissecting and resecting the flexor digitorum longus fascicles within the tibial nerve. Sensory complications are the consequence of excessive manipulations of the sensory fascicles during surgery¹¹.

Spasticity can recur when the amount of sectioning is insufficient or after reinnervation. Two mechanisms might explain reinnervation, as Decq showed⁹; first is the axonal growth of the cut motor neurons, and second is the "sprouting phenomenon" Hoffman described in the 1950s⁸. The

sprouting of motor neurons' endings leads to the development of new motor endplates on denervated muscles, and this phenomenon increases motor unit size, as Rafuse et al.¹³ showed. The resection is 5-10 mm long to prevent regrowth of fibers, and the proximal stump of the resected fascicle is coagulated with the goal of avoiding proliferative painful neuroma formation¹⁴. Other complications include postoperative hematoma and infection¹⁵. But neurotomy is associated with little morbidity, apart from the classic anesthetic risks and the risks related to any surgical procedure on the lower limb (wound dehiscence and reflex sympathetic dystrophy).

Neurotomy cannot replace the orthopedic treatments proposed in patients with tendon retractions; it constitutes only a part of a patient's global management, which must include physiotherapy to ensure muscle reinforcement and rehabilitation of gait. The results' quality clearly depends on meticulous preoperative assessment and a rigorous surgical procedure³. SPN's outcome also depends intimately on the postoperative care provided after a successful surgery. The limb can be raised to avoid edema and mobilized as soon as possible, with physical therapy beginning the second postoperative day¹⁵. It seems logical to perform SPN as the first step among invasive procedures if spasticity and contracture are combined. If any residual contracture inhibits function after intensive rehabilitative management, it should be corrected by orthopedic surgery.

Rehabilitation plays a fundamental role in managing these patients and, in its absence, the benefits of a proposed operation will remain limited¹¹.

Compared to adult patients, children have a greater chance of benefiting from a reduction in spasticity because of their developing nervous system's plasticity. On the other hand, they are at a higher risk than adults of developing skeletal deformities if left untreated.

Msaddi et al.¹² reported that the best results of STN were obtained in children between the ages of three and six years. In our patients, however, we found that similar effects of STN in both adults and children before fixed contracture. A vigorous sophisticated postoperative rehabilitation program is needed to avoid recurrence at long-term follow-up.

CONCLUSION

STN must be performed before the fixed deformities and vigorous rehabilitation provided after surgery in order to achieve good results. If it is performed before the fixed contracture, its effects are shown to be similar in both adults and children. The more important element in result of STN is not the degree of the analytical results obtained, but

the patient's functional improvement and satisfaction. Our results demonstrate that satisfaction in children seems to be higher than in adults. However, if children would like to obtain above results, vigorous sophisticated postoperative rehabilitation is needed due to a relative paucity of children's drive of rehabilitation.

References

1. Baroncini M, Baiz H, Wavreille G, Demondion X, Maurage CA, Buisset N, et al. : Anatomical bases of tibial neurotomy for treatment of spastic foot. *Surg Radiol Anat* 30 : 503-508, 2008
2. Brunelli G, Brunelli F : [Selective microsurgical denervation in spastic paralysis.] *Ann Chir Main* 2 : 277-280, 1983
3. Buffenoir K, Roujeau T, Lapierre F, Menei P, Menegalli-Boggelli D, Mertens P, et al. : Spastic equinus foot : multicenter study of the long-term results of tibial neurotomy. *Neurosurgery* 55 : 1130-1137, 2004
4. Caillet F, Mertens P, Rabaséda S, Boisson D : [Three dimensional gait analysis and controlling spastic foot on stroke patients.] *Ann Readapt Med Phys* 46 : 119-131, 2003
5. Collado H, Bensoussan L, Viton JM, Milhe De Bovis V, Delarque A : Does fascicular neurotomy have long-lasting effects? *J Rehabil Med* 38 : 212-217, 2006
6. Decq P : [Peripheral neurotomies for the treatment of focal spasticity of the limbs.] *Neurochirurgie* 49 : 293-305, 2003
7. Deltombe T, Detrembleur C, Hanson P, Gustin T : Selective tibial neurotomy in the treatment of spastic equinovarus foot : a 2-year follow-up of three cases. *Am J Phys Med Rehabil* 85 : 82-88, 2006
8. Hoffman H : Local re-innervation in partially denervated muscle; a histophysiological study. *Aust J Exp Biol Med Sci* 28 : 383-397, 1950
9. Hong JC, Kim MS, Chang CH, Kim SW, Kim OL, Kim SH : Long term results of microsurgical dorsal root entry zontomy for upper extremity spasticity. *J Korean Neurosurg Soc* 43 : 182-185, 2008
10. Jang SH, Park SM, Kim SH, Ahn SH, Cho YW, Ahn MO : The effect of selective tibial neurotomy and rehabilitation in a quadriplegic patient with ankle spasticity following traumatic brain injury. *Yonsei Med J* 45 : 743-747, 2004
11. Keats S : Combined adductor-gracilis tenotomy and selective obturator-nerve resection for the correction of adduction deformity of the hip in children with cerebral palsy. *J Bone Joint Surg Am* 39-A : 1087-1090, 1957
12. Msaddi AK, Mazroue AR, Shahwan S, al Amri N, Dubayan N, Livingston D, et al. : Microsurgical selective peripheral neurotomy in the treatment of spasticity in cerebral-palsy children. *Stereotact Funct Neurosurg* 69 : 251-258, 1997
13. Rafuse VF, Gordon T, Orozco R : Proportional enlargement of motor units after partial denervation of cat triceps surae muscles. *J Neurophysiol* 68 : 1261-1276, 1992
14. Sindou M, Mertens P : Selective neurotomy of the tibial nerve for treatment of the spastic foot. *Neurosurgery* 23 : 738-744, 1988
15. Sindou MP, Simon F, Mertens P, Decq P : Selective peripheral neurotomy (SPN) for spasticity in childhood. *Childs Nerv Syst* 23 : 957-970, 2007