

Analysis of location and prevalence of maxillary sinus septa

Won-Jin Lee¹, Seung-Jae Lee¹, Hyung-Seop Kim^{1,2*}

¹Department of Periodontology, Chonbuk National University School of Dentistry, Jeonju, Korea

²Research Institute of Oral Bio-Science, Chonbuk National University, Jeonju, Korea

Purpose: The sinus lift procedure requires detailed knowledge of maxillary sinus anatomy and the possible anatomical variations. This study evaluated the location and prevalence of maxillary sinus septa using computed tomography (CT).

Methods: This study was based on the analysis of CT images for posterior maxilla which were obtained from patients who visited Chonbuk National University Dental Hospital during the period of June 2007 to December 2008. With the exclusion of cases presenting any pathological changes, 236 maxillary sinuses in 204 patients were retrospectively analyzed. The average age of the patients was 50.9. The cases were divided into two groups, an atrophy/edentulous segment and a non-atrophy/dentate segment, and maxillary sinus septa of less than 2.5 mm were not taken in-to consideration. The location of septa was also divided for analysis into 3 regions: the anterior (1st and 2nd premolar), middle (1st and 2nd molar) and posterior (behind 2nd molar) regions.

Results: In 54 (20.9%) of the 204 patients there were pathologic findings, and those patients were excluded from the analysis. Sinus septa were present in 58 (24.6%) of the 236 maxillary sinuses and in 55 (27%) of the 204 total patients. In the atrophy/edentulous ridge group (148 maxillary sinuses), 41 cases (27.7%) were found, and 17 cases (19.3%) were found in the non-atrophy/dentulous ridge group (88 maxillary sinuses). In terms of location, septa were found in 18 cases (27.3%) in the anterior, in 33 cases (50%) in the middle and in 15 cases (22.7%) in the posterior regions.

Conclusions: In the posterior maxilla, regardless of type of ridge (atrophy/edentulous or non-atrophy/dentate), the anatomical variation of sinus septa is diverse in its prevalence and location. Thus, accurate information on the maxillary sinus of the patient is essential and should be clearly understood by the surgeon to prevent possible complications during sinus lifting.

Keywords: Computed tomography, Dental implants, Maxillary Sinus.

INTRODUCTION

Osseointegrated implants are increasingly used to functionally restore partial and complete edentulism. Implant therapy has become an excellent and safe treatment modality providing both a conservative and aesthetic alternative. However, implant therapy can be complicated if available bone is deficient at the surgical site.

Implant installation in the posterior maxilla is especially complicated because of the maxillary sinus above the surgical site. Because the alveolar process of the edentulous posterior maxilla is absorbed gradually, vertical bone dimension is reduced. This phenomenon is exacerbated by pneumatization of the maxillary sinus. The level of absorption varies by person, so vertical bone height for implant installation may become deficient [1-4] in certain persons.

Received: Dec. 21, 2009; **Accepted:** Mar. 02, 2010

***Correspondence:** Hyung-Seop Kim

Department of Periodontology, Chonbuk National University School of Dentistry, 634-18 Geumam-dong, Dukjin-gu, Jeonju 561-712, Korea

E-mail: cbuperio@chonbuk.ac.kr, Tel: +82-63-250-2116, Fax: +82-63-250-2259

The sinus lift procedure was first conceived by Tatum in 1976 for implant installation on the atrophic posterior maxilla. The lateral approach, which is performed by bone graft filling after hinge door formation at the lateral sinus wall and Schneiderian membrane elevation was reported by Boyne and James in 1980 [5]. There have been some modifications of this surgical technique in the past few years [6,7].

Several complications, however, were reported during this procedure [8-11], and the most frequent was the perforation of the Schneiderian membrane [9,12].

The risk of the membrane perforation increases when anatomical variations, such as a maxillary sinus septum, are present [1,4,13-16]. Several authors have studied the etiology of maxillary sinus septa [4,16,17]. Underwood [4] reported that septa are formed because of the different eruption phases of the teeth, while Neivert [17] proposed that the septa are derived from the fingerlike projections produced by the embryologic out-pouching of the ethmoid infundibulum, where the contiguous walls did not absorb. Finally, Krennmair et al. [16] further classified the septa into primary and secondary septa; primary septa arise from the development of the maxilla, whereas the secondary septa were said to arise from the irregular pneumatization of the sinus floor following tooth loss.

Even though Underwood [4] published a detailed description of maxillary sinus anatomy in 1910, for decades these septa were considered clinically-insignificant anatomical variations. Now, however, we must understand the maxillary sinus and anatomical variations [1,4] because the lateral hinge door formation is a complicated procedure and the membrane is susceptible to perforation during elevation in the presence of a maxillary sinus with septa [5,18]. Therefore, only when the prevalence, location and morphology of the sinus septa are understood, can a precise surgical plan be made and complications from sinus surgery prevented.

The prevalence of sinus septa varies from 16% to 58% according to the literature [4,16,19]. Underwood [4] found 30 septa in 45 skulls (90 maxillary sinuses), demonstrating a 33% prevalence. Krennmair et al. [16] reported a prevalence ranging from 14% to 31.7%, depending on patient age and tooth loss. Recently, according to Kim et al. [19], sinuses with septum or septa were found in 53 of 200 sinuses, demonstrating a 26.5% prevalence.

The location of sinus septa also varies according to the literature. The most common location described by Underwood [4] was the posterior region. However, Krennmair et al. [16] observed a majority of septa in the anterior/premolar region of edentulous maxillae (75%) and dentate maxillae (57.1%). According to Kim et al. [19], the majority of septa are located in the middle/molar region (50%). The remaining

septa, located in the anterior/premolar region and in the posterior/distal aspect of the second molar region, represent 25.4% and 23.7%, respectively.

The aim of this study is to analyze the location and prevalence of maxillary sinus septa using computed tomography (CT) images for posterior maxilla which were obtained from the patients who visited Chonbuk National University Dental Hospital.

MATERIALS AND METHODS

This study was based on an analysis of CT images for posterior maxilla which were obtained from patients who visited Chonbuk National University Dental Hospital during the period of June 2007 to December 2008. The images included in this study only include those obtained from the lateral wall of the nasal cavity to the posterior wall of the maxillary sinus. The patient population was 258 in total, but 54 of the 258 patients exhibited pathologic changes in appearance in the maxillary sinus and were therefore excluded from this study. Finally, of the total 204 subjects, 236 sinuses were analyzed. The mean age was 50.9, and ranged from 10 to 78. 148 sinuses (62.7%) were atrophic/edentulous, and the remainder (37.3%) were non-atrophic/dentate. The maxillae with atrophic buccal bone were included in the atrophic segment, and the maxillae with a distinctive, recently extracted socket line were included in the non-atrophic segment when reading the CT image.

CT was performed on the patients using PSR 9000N (80 kV/16 mA, Asahi Roentgen Ind., Kyoto, Japan), and image analyses were performed after reconstruction of tomographic images using M-View 5.3 (Marotech, Tokyo, Japan), a multiple image reconstruction program. The sagittal image from the CT was used for measurement, and the measurement was performed using digital calipers in the program. During evaluation of the septa at the mid-crestal aspect, a line drawn at the approximate base of the septa was established (A, B), and its height was measured using a line extending from this base to the most coronal portion of the septa (C, D). If the vertical dimension of the septa was over 2.5 mm, the septa was included in our study (Fig. 1). To assure teeth location, CT was performed while wearing a surgical stent filled with radiopaque material. Each antral cavity exhibiting a septum was divided into three locations: anterior (mesial to distal aspect of the second premolar), middle (from the distal aspect of the second premolar to the distal aspect of the second molar), and posterior (the distal aspect of the second molar region).

Statistical analyses were performed using the chi-square test to determine whether there were significant differences

in the location and prevalence of the septa in the atrophic/edentulous and non-atrophic/dentate groups and in the prevalence of the septa by gender, and in both sinuses. *P* values less than 0.05 were considered statistically significant.

This study protocol was approved by the Clinical Research Institute, Chonbuk National University Hospital (CBIRB 0911-123).

RESULTS

Pathologic appearance

CT imaging of the posterior maxillae was performed on a total of 258 patients during the period of June 2007 to December 2008. Out of 258, however, 54 patients exhibited a pathologic appearance. A majority of pathologic appearances were mucosal thickening (*n*=38, 66.7%), followed by sinusitis (*n*=17, 29.8%). Mucocele and mucous retention cysts were each found in 1 case (Table 1).

Prevalence

Two hundred and four patients, excluding the 54 patients with a pathologic appearance, were analyzed. Out of 236 sinuses, 58 (24.6%) had one or more septa, and out of 204 patients, 55 (27%) had one or more septa. 50 sinuses had 1 septum, and 8 sinuses had 2 septa. No sinus had 3 or more septa,

and there were no septa completely dividing the sinus into two or more compartments. In terms of gender, 35 of 117 men (35%) and, 20 of 87 women had septa - so the prevalence of septa was higher in men (*P*<0.05). In terms of sinus location, 26 septa existed in right sinuses (23.6%), and 32 septa existed in left sinuses (25.4%). This difference was not statistically significant (*P*>0.05). In the atrophic/edentulous group, 41 septa were found in 148 sinuses, and in the non-atrophic/dentate group, 17 septa were found in 88 sinuses. This difference was statistically significant (*P*<0.01) (Table 2).

Location

The analysis of the anatomic location of the septa within the sinus, revealed that 18 (27.3%) septa were located in the anterior region, 33 (50%) in the middle region, and 15 (22.7%) in the posterior region. The distribution varied when the atrophic/edentulous and non-atrophic/dentate group were compared, but a significant difference was only observed between the two populations in the posterior region (*P*<0.01). A closer examination of the non-atrophic/dentate group revealed a 66.7% prevalence of septa located superior to a maxillary tooth (primary septa) and a 33.3% prevalence of septa

Table 1. Maxillary sinuses involved with diseases (*n*=57).

Diseases	Number
Sinusitis	17
Mucosal thickening	38
Mucous retention cyst	1
Mucocele	1

Table 2. Summary of septa prevalence data.

	Number	No. of septa (%)	1 septum	2 septa
Patients	204	55 (27)	-	-
Male	117	35 (30)	-	-
Female	87	20 (23)	-	-
Sinus	236	58 (24.6)	50	8
Right	110	26 (23.6)	19	7
Left	126	32 (25.4)	31	1
Atrophic/edentulous	148	41 (27.7)	34	7
Non-atrophic/dentate	88	17 (19.3)	16	1

Table 3. Summary of septa location data.

	Anterior (%)	Middle (%)	Posterior (%)	No. of septa
Atrophic/edentulous	13 (27.1)	22 (45.8)	13 (27.1)	48
Non-atrophic/dentate	5 (27.8)	11 (61.1)	2 (11.1)	18
Primary	5 (100)	6 (54.5)	1 (50)	12
Others	0 (0)	5 (45.5)	1 (50)	6
Total	18 (27.3)	33 (50)	15 (22.7)	66

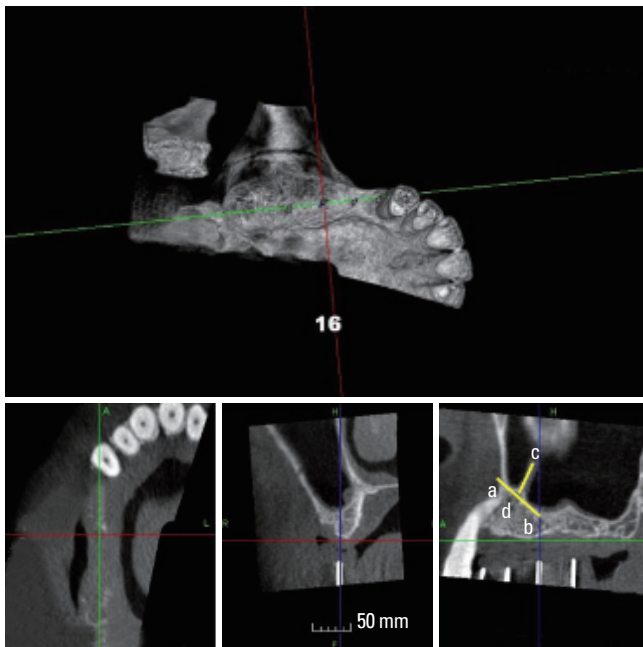


Figure 1. Evaluation of septa at mid-crestal aspect (lower-right). A line drawn at the approximate base of the septa was established (A, B), and its height was measured using a line extending from this base to the most coronal portion of the septa (C, D). If the vertical dimension of the septa was over 2.5 mm, the septa was included in our study.

located superior to an atrophic/edentulous ridge (primary septa, secondary septa, or a combination of both) (Table 3).

DISCUSSION

Several authors have studied the prevalence of maxillary sinus septa [4,12,16,19-21]. Underwood [4] found 30 septa in 90 sinuses, demonstrating a 33% prevalence, and Ulm et al. [12] found 15 septa in 82 sinuses, demonstrating a prevalence of 18.3%. Also, Krennmair et al. [16] reported 32 septa in 200 sinuses, demonstrating a 16% prevalence, and Velasquez-Plata et al. [20] reported 75 septa in 312 sinuses, demonstrating a prevalence of 24%. This study revealed 58 septa (24.6%) in 236 sinuses. The prevalence of the present study agrees with the results of the previous studies. Also, the prevalences of septa in the atrophic/edentulous and non-atrophic/dentate group in the present study were 27.7% (41/148) and 19.3% (17/88), respectively. The prevalence of the former was higher than the latter. We can assume that secondary septa can develop more frequently in the area above lost teeth due to pneumatization of the maxillary sinus, making the prevalence of septa in the atrophic/edentulous group higher than in the non-atrophic/dentate group. Eighteen septa were found in the non-atrophic/dentate group, and 12 of these septa were primary (66.7%). Also, 50 sinuses had 1 septum were, and 8 had 2 septa. There were no sinuses with 3 or more septa, and no septa completely divided the sinus into two or more compartments.

Sinus septa can be divided into primary septa and secondary septa; the primary septa arise from the development of the maxilla, whereas the secondary septa are said to arise from the irregular pneumatization of the sinus floor following tooth loss [16]. In other words, primary septa are congenital, and secondary septa are acquired. The septa above the apical area of an edentulous ridge cannot be distinguished into primary or secondary septa without previous radiographic records. Therefore, it can be said that septa above teeth are primary, and septa above an edentulous ridge are primary or secondary.

The location of septa observed in the present study demonstrated a greater prevalence in the middle region (from the distal aspect of the second premolar to the distal aspect of the second molar) (50%), followed by the anterior region (mesial to distal aspect of the second premolar) (24.0%) and the posterior region (the distal aspect of the second molar region) (22.7%). This result agrees with the result of previous study [19]. Kim et al. [19] reported prevalences of 25.4% in the anterior region, 50.8% in the middle region, and 23.7% in the posterior region. We can assume that secondary septa develop more frequently in the area above lost molar teeth because of earlier extraction of molar teeth than premolar

teeth. Krennmair et al. [16], however, reported a conflicting result, with the greatest prevalence in the anterior region, at 70-75%. Further studies will be required to determine the reason for the difference in prevalence by location.

CT at both sinuses was performed in 32 of 204 patients. The prevalence of septa in the left sinus was higher than in the right sinus, at 28.1% (9/32) in the left, compared to 18.8% (6/32) in right. The prevalence of septa in both sinuses was low, at 9.4% (3/32). However, the prevalence in either the left or right sinus was similar, at 25.4% and 23.6%, respectively. Velasquez-Plata et al. [20] reported 72 septa in 312 sinuses, and found 39 in the left sinus and 36 in the right sinus. Similarly to this study, it appeared that sinus septa exist in equal number in the left or right sinus. We need to emphasize that 7 of 8 sinuses with 2 septa were found on the right side. To evaluate this result, a large sample in a well-controlled study is required.

Sinuses with pathologic appearance were excluded from the present study. Out of 258 patients, 54 had a pathologic appearance (20.9%). A majority of pathologic appearances were mucosal thickening (n=38, 66.7%), followed by sinusitis (n=17, 29.8%). Mucocele and mucous retention cysts were each found in only 1 case. Beaumont et al. [8] evaluated the prevalence of sinus disease, and reported a 27% prevalence. In the present study, a 20.9% prevalence was found, which is lower than the previous reports [8], but the results reinforce the importance of taking a careful, detailed history and evaluation thorough clinical and radiographic examination prior to performing sinus augmentation.

In spite of the limitation of not including septa size, the present study indicates that maxillary sinus septa can develop in all maxillary sinus regions whether they are atrophic/edentulous or non-atrophic/dentate. Therefore, the presence/absence and the location of septa need to be diagnosed using CT. Only then can a precise surgical plan be decided upon, and perioperative complications prevented. For instance, opening 2 adjacent windows instead of one could be necessary to facilitate access to and elevation of the Schneiderian membrane [14]. In other cases, the septum can be removed using an instrument, such as a hemostat [5].

In conclusion, whether they were found to be in atrophic posterior maxilla or not, and whether over an edentulous ridge or not, the prevalence and location of the maxillary sinus septa varied anatomically. Therefore, to prevent perioperative complications, the clinician must have accurate information and a clear understanding of the patient's maxillary sinus. In the present study, only the result of the CT reading was presented and actual clinical evidence is deficient. Therefore, further study of the anatomical variation of the maxillary sinus is required.

CONFLICT OF INTEREST

No potential conflict of interest relevant to this article was reported.

ACKNOWLEDGEMENTS

This study was supported by a scientific research fund from Chonbuk National University Hospital, Jeonju, Korea.

REFERENCES

1. Chanavaz M. Maxillary sinus: anatomy, physiology, surgery, and bone grafting related to implantology--eleven years of surgical experience (1979-1990). *J Oral Implantol* 1990;16:199-209.
2. Cawood JI, Howell RA. A classification of the edentulous jaws. *Int J Oral Maxillofac Surg* 1988;17:232-6.
3. Vinter I, Krmpotic-Nemanic J, Hat J, Jalsovec D. Does the alveolar process of the maxilla always disappear after tooth loss? *Laryngorhinootologie* 1993;72:605-7.
4. Underwood AS. An inquiry into the anatomy and pathology of the maxillary sinus. *J Anat Physiol* 1910;44:354-69.
5. Boyne PJ, James RA. Grafting of the maxillary sinus floor with autogenous marrow and bone. *J Oral Surg* 1980;38:613-6.
6. Farmand M. Horse-shoe sandwich osteotomy of the edentulous maxilla as a preprosthetic procedure. *J Maxillofac Surg* 1986;14:238-44.
7. Sailer HF. A new method of inserting endosseous implants in totally atrophic maxillae. *J Craniomaxillofac Surg* 1989;17:299-305.
8. Beaumont C, Zafiroopoulos GG, Rohmann K, Tatakis DN. Prevalence of maxillary sinus disease and abnormalities in patients scheduled for sinus lift procedures. *J Periodontol* 2005;76:461-7.
9. Kasabah S, Slezak R, Simunek A, Krug J, Lecaro MC. Evaluation of the accuracy of panoramic radiograph in the definition of maxillary sinus septa. *Acta Medica (Hradec Kralove)* 2002;45:173-5.
10. Maksoud MA. Complications after maxillary sinus augmentation: a case report. *Implant Dent* 2001;10:168-71.
11. Ueda M, Kaneda T. Maxillary sinusitis caused by dental implants: report of two cases. *J Oral Maxillofac Surg* 1992;50:285-7.
12. Ulm CW, Solar P, Krennmair G, Matejka M, Watzek G. Incidence and suggested surgical management of septa in sinus-lift procedures. *Int J Oral Maxillofac Implants* 1995;10:462-5.
13. Tatum H, Jr. Maxillary and sinus implant reconstructions. *Dent Clin North Am* 1986;30:207-29.
14. Betts NJ, Miloro M. Modification of the sinus lift procedure for septa in the maxillary antrum. *J Oral Maxillofac Surg* 1994;52:332-3.
15. van den Bergh JP, ten Bruggenkate CM, Disch FJ, Tuinzing DB. Anatomical aspects of sinus floor elevations. *Clin Oral Implants Res* 2000;11:256-65.
16. Krennmair G, Ulm CW, Lugmayr H, Solar P. The incidence, location, and height of maxillary sinus septa in the edentulous and dentate maxilla. *J Oral Maxillofac Surg* 1999;57:667-71.
17. Neivert H. Symposium on maxillary sinus: surgical anatomy of the maxillary sinus. *Laryngoscope* 1930;40:1-4.
18. Tidwell JK, Blijdorp PA, Stoelinga PJ, Brouns JB, Hinderks F. Composite grafting of the maxillary sinus for placement of endosteal implants: a preliminary report of 48 patients. *Int J Oral Maxillofac Surg* 1992;21:204-9.
19. Kim MJ, Jung UW, Kim CS, Kim KD, Choi SH, Kim CK, et al. Maxillary sinus septa: prevalence, height, location, and morphology. A reformatted computed tomography scan analysis. *J Periodontol* 2006;77:903-8.
20. Velasquez-Plata D, Hovey LR, Peach CC, Alder ME. Maxillary sinus septa: a 3-dimensional computerized tomographic scan analysis. *Int J Oral Maxillofac Implants* 2002;17:854-60.
21. Krennmair G, Ulm C, Lugmayr H. Maxillary sinus septa: incidence, morphology and clinical implications. *J Craniomaxillofac Surg* 1997;25:261-5.